

## Case Report

# A Solitary Neurofibroma of the Small Finger Associated with Trauma

Hwan Jun Choi, Kyu Hwa Jung, Doo Hyun Nam

Department of Plastic and Reconstructive Surgery, Soonchunhyang University College of Medicine, Cheonan, Korea

Received July 27, 2013  
Revised September 21, 2013  
Accepted September 24, 2013

Correspondence to: Hwan Jun Choi  
Department of Plastic and Reconstructive  
Surgery, Soonchunhyang University  
Cheonan Hospital, 31 Suncheonhyang  
6-gil, Dongnam-gu, Cheonan 330-903,  
Korea  
Tel: +82-41-570-2195  
Fax: +82-41-570-6133  
E-mail: medi619@hanmail.net

Neurofibroma may present as a solitary lesion or as multiple lesions. Although there is no site of predilection for solitary lesions, occurrence on the hand is rare. Plexiform neurofibroma can develop in isolation or more commonly as a part of neurofibromatosis type 1. In those that appear in isolation, trauma has been suggested as a precipitating factor. A 68-year-old male farmer had experienced repetitive prior episodes of trauma in the involved finger. He presented with a painless mass on the dorsal aspect of the fifth finger. Physical examination showed a protruding mass measuring approximately 15×20 mm which was not tenderness to palpation and any skin changes or pigmentation. Ultrasonography showed a cystic mass on the dorsal aspect of the middle phalanx. Microsurgical dissection was applied in order to separate the lesion from the ulnar side of the dorsal branch of the digital nerve. Pathologic examination of the specimens revealed neurofibroma. At three-month follow-up, motor and sensory function were intact, and range of motion was fully recovered. Traumatic solitary neurofibroma is a rare tumor of the hand, especially in the finger. Hand surgeons should be aware of the diagnostic possibilities of this tumor based on examination, history taking and imaging studies.

**Key Words:** Neurofibroma, Fingers, Isolation

Neurofibroma is a benign tumor of neuroectodermal origin and represents a proliferation of cells within the nerve sheath.<sup>1</sup> Usually, neurofibroma is a benign nonencapsulated tumor of nerve fiber fascicles, which are generally localized and cannot be removed.<sup>2</sup> It is composed of cellular and fibrous central bands and a peripheral band which consists predominantly of myxoid stroma rich in mucopolysaccharides.<sup>2</sup> They can occur as a solitary lesion or as multiple distinct lesions. Localized neurofibromas arise from a single fascicle within a nerve.<sup>1</sup> Plexiform neurofibromas, on the other hand, involve multiple fascicles of a nerve, creating a network of thickened neural tissue. The anatomical enlargement of the affected nerve is often accompanied by soft tissue hypertrophy, which can be significant.<sup>1</sup> Plexiform neurofibromas are commonly found in individuals with von Recklinghausens disease or

neurofibromatosis type 1 (NF-1). Treatment consists of observation or surgical excision. Indications for surgical intervention include increase in size, reduction in function, overlying skin adherence, pain and malignant transformation.<sup>1</sup>

Hand surgeons should be aware of the clinical features of solitary neurofibroma. It is a subset of neurofibromatosis that is not associated with systemic disease. It presents with painful neurofibromas involving different peripheral nerves limited to a single body part unilaterally.<sup>3</sup> Treatment by excision using microsurgical technique can remove traumatic solitary neurofibromas completely with good results.

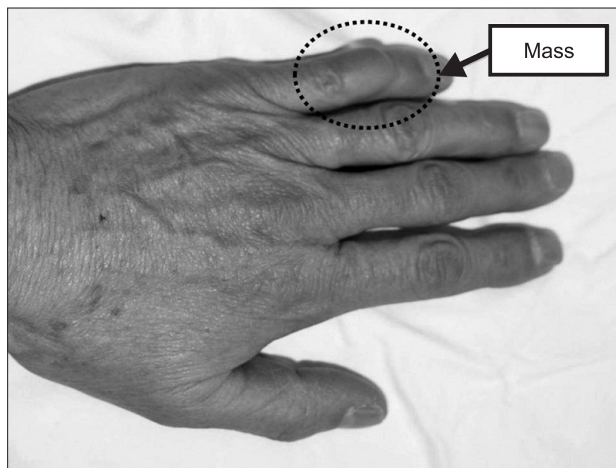
## CASE REPORT

A 68-year-old male farmer presented with 5-year history of

a painless, slowly growing, swelling mass on the his left small finger. There was repetitive history of prior trauma, but his medical history was unremarkable. On physical examination, he had a single soft, non-tender swelling mass, about 15×20 mm in size, on the dorsal skin of the finger (Fig. 1). The mass was freely mobile and the overlying skin was normal. There were no café au lait spots, axillary and inguinal freckles. Complete neurologic and ophthalmologic examinations did not reveal any abnormality. However, brain and spinal scans were not performed. There was no family history of NF-1, NF-2, or schwannomatosis. Ultrasonography showed a well-defined swelling mass, free from the tendon sheaths and

the middle phalangeal bone, with a fine echogenic pattern suggesting gelatinous materials. Needle-aspiration cytology and punch biopsy were not attempted (Fig. 2).

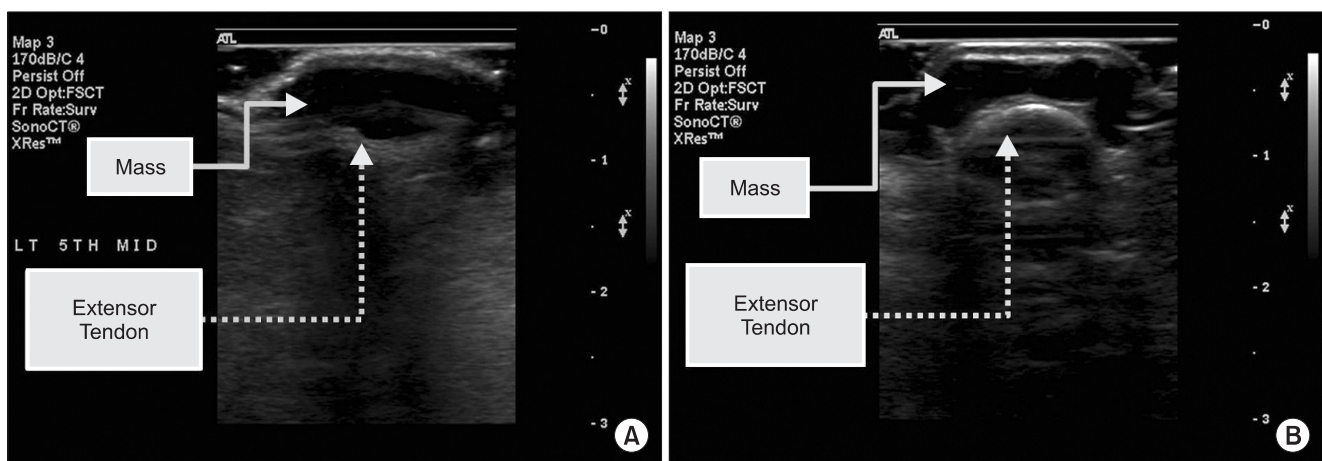
Surgical excision was carried out through a direct longitudinal incision. Microsurgical dissection was applied to separate this lesion from the tendon sheath. When dissection was directed deep to the mass, the lesion peeled away from the tendon sheath along with the dorsal branch of the digital nerve (Fig. 3). Histology of the mass contents revealed slender spindle shaped cells with thin wavy nuclei arranged in a storiform pattern (Fig. 4). The background matrix was pale stained and had focal myxoid stroma. There was no significant nuclear pleomorphism, and no mitoses were found.



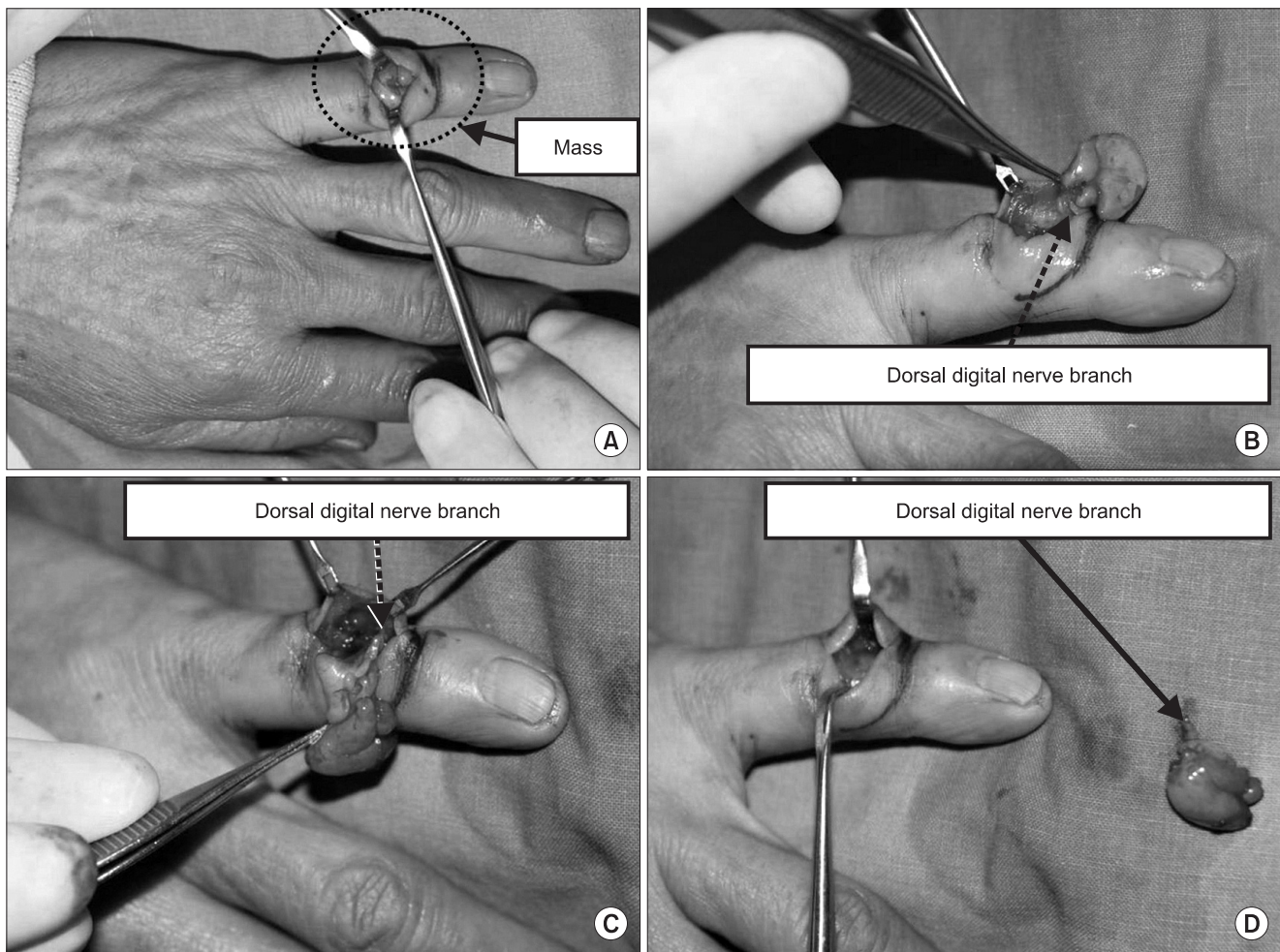
**Fig. 1.** Preoperative finding. The photograph shows 68-year-old male with a solitary palpable mass on the left 5th finger.

## DISCUSSION

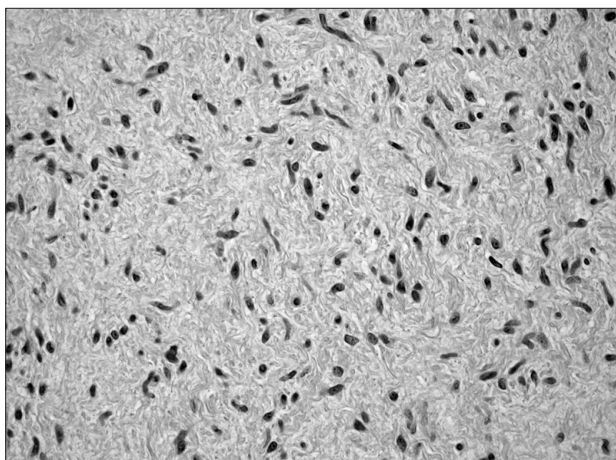
Neurofibromas are benign nonencapsulated tumors originating from Schwann cells. However, unlike schwannomas, they have a wider, more disordered spectrum of cellular pathology involving portions of the peripheral nerve fiber. Neurofibromas tend to involve the central portion of the nerve and may be difficult to dissect freely without damaging nerve fibers. Because neurofibromas occur within the nerve and are not extrinsic to it, as schwannomas are, they cannot be enucleated from the nerve fibers (unlike schwannomas).<sup>4</sup> Neurofibromas occur in 2 basic disease patterns: sporadic and in association with neurofibromatosis.<sup>1</sup>



**Fig. 2.** Preoperative ultrasonographic (USG) findings. (A) Longitudinal view shows a subcutaneous mass. (B) Transverse USG view shows a cystic mass on the extensor tendon sheath.



**Fig. 3.** Intraoperative findings. (A) This finding shows skin incision and the subcutaneous mass. (B) Photographic finding shows a worm-like enlarged mass. (C) This photograph reveals the mass and its related dorsal branch of the digital nerve. (D) Showing the removed mass and dissected nerve.



**Fig. 4.** Pathological finding. Irregularly directed spindle cells with elongated, wavy nuclei and fibrosis. It consists of spindle cells with slight to moderate pleomorphic hyperchromatic nuclei (H&E,  $\times 400$ ).

Localized neurofibromas are thought to be solitary lesions not associated with systemic disease. Approximately 90% of neurofibromas are localized lesions; the rest are associated with neurofibromatosis. Neurofibromatosis (von Recklinghausen disease) is a neurocutaneous syndrome that affects the skin, nervous system, musculoskeletal system, and eyes in various manifestations. NF-1 involves a genetic defect of chromosome 17, encoding for a tumor suppressor gene, *NF1*, which is transmitted in an autosomal dominant pattern. Clinical signs include café au lait spots, axillary/inguinal freckling, optic glioma, Lisch nodules (iris hamartomas), osseous lesions, and neurofibromas.<sup>4</sup> Neurofibromas often occur in a plexiform growth pattern, which is pathognomic of neurofibromatosis. Plexiform growth is multicentric and involves the same nerve over an extended area, resulting in

irregular thickening of the nerve. Neurofibromas can involve an entire extremity, and they have a classic 'bag of worms' appearance. Skeletal abnormalities occur in up to 40% of patients with the disease and can manifest as long-bone bowing, scoliosis, and nonossifying fibromas.<sup>4</sup>

Diagnostic difficulties and delays are common due to the lack of characteristic features of these lesions and in some cases due to unexpected sites. Neurofibromas on fingers are rare and reports in literatures are scant. In our case, diagnosis of neurofibroma was not considered clinically due to the unusual site of the tumor, but in retrospect, the lesion was typical of a solitary neurofibroma.<sup>5</sup>

Most cases of multiple neurofibromas involving cutaneous and peripheral nerves represent NF-1 and are associated with a well-described constellation of symptoms. In contrast, a rare variant of neurofibromatosis, segmental neurofibromatosis (segmental NF), presents with multiple plexiform neurofibromas limited to a single body part not crossing the midline and without the typical clinical characteristics of NF-1.<sup>3</sup>

Imaging studies included magnetic resonance imaging that revealed numerous nodules in the upper extremity that were circumscribed and had a low signal on T1 and high signal on T2. They had an enhancement pattern that was inconsistent with that of ganglions and were intimately related to different peripheral nerves.<sup>3</sup>

Histologically, neurofibromas in all form of neurofibromatosis can be unencapsulated, poorly circumscribed tumors that can incorporate all aspects of the nerve including the surrounding Schwann cells and the axons within. They are often confused with schwannomas, which in contrast are globular, well circumscribed tumors of Schwann cells that line nerves.<sup>3</sup> In our case, the neurofibroma maintained an infiltrative nature resulting in splaying of fascicles within the dorsal cutaneous branch and well circumscribed mass in the subcutaneous tissue.

A differential diagnosis of neurofibroma should be considered for all slow-growing, soft or rubbery swellings on the skin, wherever the site.<sup>5</sup> The differential diagnosis of painful subcutaneous masses includes angiolipomas, leiomyomas, schwannomas, eccrine spiradenomas, and glomus tumors. Angiolipomas and leiomyomas are the most common among these.<sup>3</sup> Diagnosis requires an excisional

biopsy. In contrast to plexiform neurofibroma, plexiform Schwannoma occurs sporadically, is not associated with NF-1, and has no propensity for malignant potential.<sup>6</sup> Schwannoma shows mostly high cellularity and biphasic patterns (Antoni A, B) while axons are often absent, whereas in neurofibroma, cellularity is low to moderate, the growth pattern is uniphasic and axons are frequently detectable. The distinction of neurofibroma from low-grade malignant peripheral sheath tumor usually does not because problems considering cellularity, nuclear morphology, and mitotic activity. Traumatic neuroma is composed of small complex microfascicles of axons, whereas axons in neurofibroma are generally dispersed.<sup>7</sup>

In our opinion, solitary neurofibromas can usually be treated by simple excision. However, if the swelling is soft and small, it may be extruded through a small punch hole, providing an excellent cosmetic result. We have presented the clinical and histopathological features of a case of solitary traumatic neurofibroma in order to highlight the existence of this rare lesion. First of all, histological recognition is important to ensure that cutaneous solitary neurofibroma are not confused with more ominous lesions.

## REFERENCES

1. Jones ME, Tonkin MA. Plexiform neurofibroma with dual nerve origin within the palm: a case report. *Hand Surg* 2007;12:173-6.
2. Amoretti N, Grimaud A, Hovorka E, Chevallier P, Roux C, Bruneton JN. Peripheral neurogenic tumors: is the use of different types of imaging diagnostically useful? *Clin Imaging* 2006;30:201-5.
3. Ilyas AM, Nourissat G, Jupiter JB. Segmental neurofibromatosis of the hand and upper extremity: a case report. *J Hand Surg Am* 2007;32:1538-42.
4. Lincoski CJ, Harter GD, Bush DC. Benign nerve tumors of the hand and the forearm. *Am J Orthop (Belle Mead NJ)* 2007;36:E32-6.
5. Prasad-Hunasehally RY, Motley R. Bulbous swelling on the finger pulp. *Clin Exp Dermatol* 2009;34:279-80.
6. Punia RS, Dhingra N, Mohan H. Cutaneous plexiform schwannoma of the finger not associated with neurofibromatosis. *Am J Clin Dermatol* 2008;9:129-31.
7. Lohmeyer JA, Kimmig B, Gocht A, Machens HG, Mailänder P. Combined manifestation of a neurofibroma and a nerve sheath ganglion in the ulnar nerve after radiotherapy in early childhood. *J Plast Reconstr Aesthet Surg* 2007;60:1338-41.