

수지의 사구체 종양 - 66예 증례 분석 -

아주대학교 의과대학 정형외과학교실, 한국병원 가정의학과*

한경천* · 노형래 · 이한동 · 이유상

— Abstract —

Glomus Tumors of the Fingers -A Report of 66 Cases -

Han Kyong Chon, M.D.*, Hyong Rae Roh, M.D., Han-Dong Lee, M.D., Yu Sang Lee, M.D.

*Department of Orthopaedic Surgery, Ajou University School of Medicine, Suwon, Korea.
Department of Family Medicine, Hankook General Hospital, Cheongju, Korea**

Purpose: We reviewed 66 cases of the glomus tumors in the hands. The purpose of this study was to review the characteristic signs and symptoms of glomus tumors and the surgical outcomes. We made hypothesis that (1) our guideline for surgical excision are reliable and (2) our surgical technique is efficient and less harmful to the nail root.

Materials and Methods: The clinical diagnosis was made with occasional radiological studies and surgical excision was performed according to our indications. Patients with electrical shock-like pain by touching (the essential symptom) and at least 2 of 4 clinical signs and symptoms (cold hypersensitivity, paroxysmal pain that radiated proximally, blue discoloration, nail deformity for dorsal tumor or a palpable nodule for pulp tumor) underwent surgical excision.

Results: The duration of symptoms of the patients was about 5.3 years. No difference of prevalence was found in both hands, but the thumb and the middle finger were more affected than the other fingers. The mean follow up period was 2.4 years and none of the patients complained the same characteristic pain at the last visit.

Conclusion: To the best of our knowledge, this report is the largest case series about glomus tumors in the finger tip. The clinical signs and symptoms are important to make a diagnosis of glomus tumors, and surgical excision is the treatment of choice.

Key Words: Glomus tumor, Finger, Subungual approach

*통신저자: 이 유 상

경기도 수원시 영통구 원천동 산5

아주대학교 의과대학 정형외과학교실

Tel: 031-219-5220, Fax: 031-219-5229, E-mail: osdrlee@gmail.com

INTRODUCTION

Glomus tumors are benign hamartomas that arise from the normal glomus apparatus, which is located in the subcutaneous tissue^{1,2}. This tumor is small in size, but symptoms such as pain, tenderness and temperature sensitivity can distress the patient. Moreover, misdiagnosis and improper treatments make the patients suffer a severe pain for long time without improvement³.

The most common site is the subungual space of the distal phalanx, but it can occur at any site on the upper extremity⁴. In most patients, electrical shock-like pain is elicited by direct touch on the tumors, and cold hypersensitivity, blue discoloration, nail deformity and/or a palpable neuropathic nodule around the pulp were common. None the less, these symptoms are sometimes under-estimated or ignored by physicians, so an early diagnosis and proper treatment are delayed. Many authors have reported that the proper diagnosis of glomus tumor was made several years after the onset of symptoms³.

Surgical excision is the only recommended curative treatment, so some authors have reported their surgical techniques with good

results^{2,5}. Although the lateral approach has been recommended by some authors⁶, the direct transungual approach is more popular^{3,7}. But in some cases, nail deformity and cleavage were noticed after surgical excision, so we used a less aggressive surgical technique to protect the nail root.

The purpose of this study was to review the characteristic signs and symptoms of glomus tumors and the surgical outcomes. We made hypothesis that (1) our guideline for surgical excision are reliable and (2) our surgical technique is efficient and less harmful to the nail root.

PATIENTS AND METHODS

We reviewed 66 cases (64 patients) of glomus tumors treated surgically between March 2001 and January 2009. Surgical excisions were done by a single surgeon and all confirmed as glomus tumors histopathologically. The average age of the patients was 36.5 years (range: 22~62 years) and 42 patients were women (65.6%). It took an average of 5.3 years (range: 1 to 16 years) from the onset of clinical symptoms to an

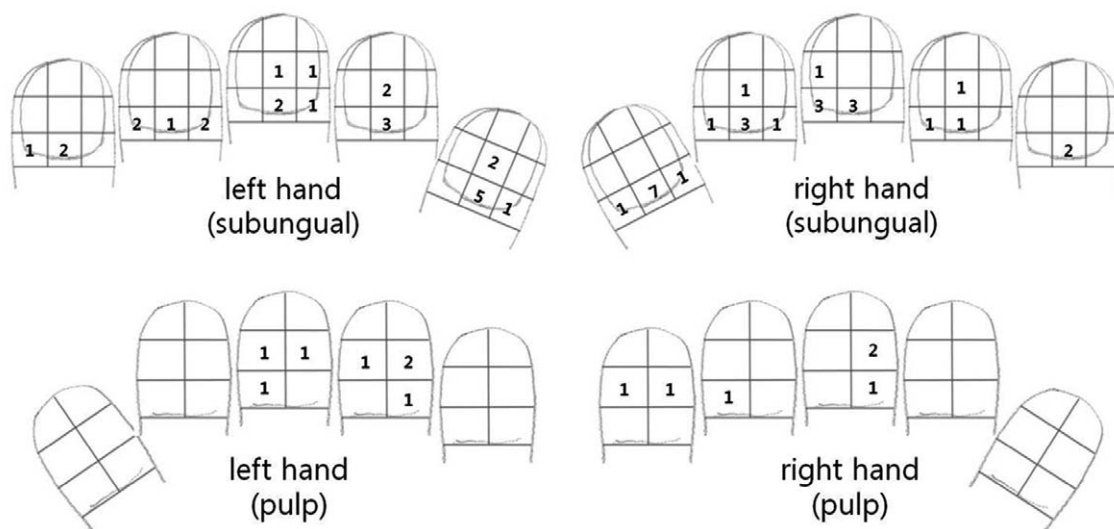


Fig. 1. Prevalence of glomus tumors of the distal finger. The most common site was the proximal-middle area for the subungual tumors and the middle-radial area for the volar pulp tumor. No tumor was found at the distal portions.

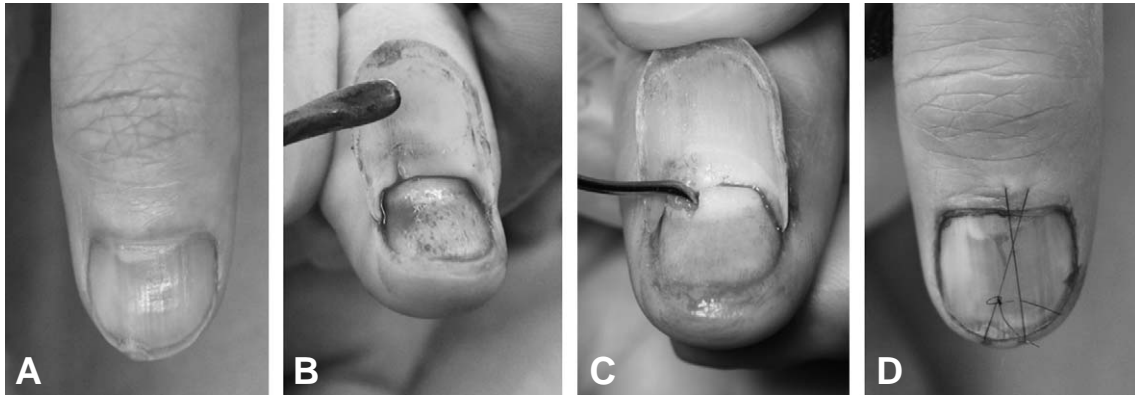


Fig. 2. Surgical excision of subungual tumor without complete detachment of the proximal nail plate. **(A)** Nail deformity and bluish discoloration are noticed on the proximal-ulnar area of the right thumb. **(B)** Nail plate elevation without detachment from the nail root. **(C)** Incision and excision of tumor. **(D)** After excision, the nail is replaced without violation of the nail root.

operation. The locations of the tumors are described in figure 1. The distal phalanges were evenly partitioned into 9 regions for the dorsal subungual tumors and 6 regions for the volar pulp tumors. The preoperative diagnosis and the decision for surgical excision were made by our clinic's guideline, which is presented below.

Surgical guideline for glomus tumors

- I. Essential symptom: Electrical shock-like pain elicited by touch at a specific point of the distal phalanx
- II. Clinical signs and symptoms
 1. Hypersensitivity to cold
 2. Paroxysmal pain that radiated proximally
 3. Blue discoloration
 4. Nail deformity for dorsal tumor or a palpable nodule for pulp tumor

The patients with the essential symptom and 2 of the clinical signs and symptoms underwent surgical excision under loupe magnification, digital nerve block with finger tourniquet. All the excised tumors were confirmed by pathological examination. Plain radiographs were all taken, and MRI was also checked in case of an uncertain localization of neuropathic pain.

Surgical Technique

All glomus tumor excision was performed with loupe magnification, under the digital nerve block and a rubber tourniquet at the base of the proximal phalanx.

1. Subungual tumors: As described by McDermott and Weiss, the direct transungual approach and complete excision of masses were done². But the root of the nail plate was not detached from the germinal matrix as much as possible (Fig 2). We made a small longitudinal incision over the mass, a cottle elevator was used for definite isolation and excision of tumor without damage to the nail matrix. If the tumor was located far proximally or laterally, then the nail was partially extracted to expose the tumor. After repair of the nail bed, the nail plate was replaced and immobilized with a figure-8 tie-over stitch for 2 weeks.
2. Pulp tumors: A longitudinal incision was made just over the most painful point. Careful dissection exposed the tumor, and complete excision of the mass with the surrounding connected tissues was performed (Fig 3).

The patients' signs and symptoms were

checked at 2 weeks after surgery and the patients were followed up for about 2 years. We telephoned the patients who did not revisit our clinic after 1 year of surgery, and we asked questions about symptoms and the status of nail plate.

RESULTS

All the patients had electrical shock-like pain (elicited by touch). Cold hypersensitivity was elicited in 71.7% of the subungual tumors and 61.5% of the pulp tumors. Paroxysmal radiating pain and blue discoloration were found less frequently, but a palpable neuropathic nodule was

the second most common symptom of the pulp tumors (Table 1). On the simple radiographs, 3 patients showed definite bony erosion, and MRI was used for only 14 patients for localization of the tumors.

After excision of subungual tumor by the transungual approach, 47 of the 53 (88.7%) patients were satisfied with their nail plate configuration. For the pulp tumors, 11 of 13 (84.6%) patients were satisfied with their surgical scars.

The mean follow-up period was 2.4 years and none of the patients complained the same characteristic pain at the last visit. All cases were confirmed as glomus tumors by pathologic examination.

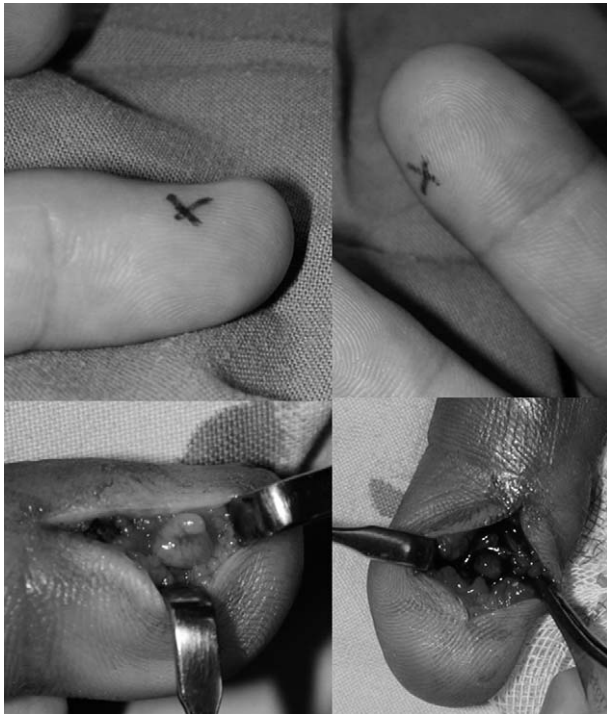

Fig 3: Double Pulp tumors on both hands in one patient. Both the tumors were excised at the same time.

DISCUSSION

Glomus tumors were first described by Wood in 1812⁸ and Mason reported on their histopathology in 1924⁹. They are derived from the neuromyoarterial glomus apparatus and these tumors are traditionally characterized by a small solitary nodule of the distal phalanx with point tenderness, lancinating pain and cold sensitivity¹⁰. Although multiple glomus tumors have been reported¹¹ and they have a different character (uncapsulated, often asymptomatic), the majority of them are a solitary mass in the distal finger. Glomus tumors are very rare, so many patients are misdiagnosed and they have a long period of pain and discomfort. Moreover, the only curative treatment is surgical radical excision, and medication or restriction of activities is not helpful. Therefore, making a proper diagnosis is very important and it is essential for

Table 1. Clinical features of glomus tumors. Besides electrical-shock like pain, the most common symptom was cold hypersensitivity for the subungual tumors and a palpable neuropathic nodule for the volar pulp tumors.

	Electrical shock pain	Cold hypersensitivity	Paroxysmal radiating pain	Blue discoloration	
Subungual tumor (53 cases)	100%	71.7% (38)	67.9% (36)	34.0% (18)	Nail deformity 47.2% (25)
Pulp tumor (13 cases)	100%	61.5% (8)	38.5% (5)	13.4% (2)	Palpable nodule 76.9% (10)

resolving the pain and improving daily activities. But the characteristics of this tumors have been reported for only small groups of patients. To date, a retrospective study of 51 cases reported by Geertruyden is the largest study³, and the other studies are smaller sized. Only limited information about glomus tumor has been revealed, so we reviewed a larger group of patients with glomus tumors.

Most authors have reported the female dominant character of glomus tumors. Geerruyden et al noticed that 44 of 51 cases were female³, but our experience shows 38 of 66 cases were female. The proportion of females was not overwhelming in our study. The incidence of tumor on each finger was almost same and no predominant finger was reported in a previous study³. Yet in our results, glomus tumors were found more commonly in the thumbs and the long fingers than the other fingers. None of the tumors was located at the distal one third of the distal phalanx.

All the patients who were compatible with our surgical indications underwent an excision under digital block with loupe magnification. All the tumors were confirmed by pathologic examination as glomus tumors. None of the patients experienced the recurrence of the same symptoms, but two patients revisited for the equal symptoms at other sites. As described by McDermott and Weiss, if another tumor develops within weeks after excision, it regards as recurrence². In these sense, no recurrence of glomus tumor was found in our cases. As residual tumor tissue is the source of recurrence⁵, we used a small curette for definite isolation of tumor, and removed suspected tissue with a small rongeur. We believe that this protocol is the reason for the lack of recurrence in our cases. In most cases, the subungual glomus tumors could be excised without detachment of the nail root. As described before, we didn't extract the nail, but rather, we just elevated the distal part of the nail plate and excised the

tumor. This technique has some benefits of minimal violation to the nail root, preservation of the dorsal nail bed and exact placement of the nail plate after surgery.

On the simple radiographs, bony erosion or lytic changes were found only in 3 of 66 cases, and these radiological abnormalities were not correlated with the characteristic symptoms of glomus tumors. Nevertheless, MRI is helpful for defining the exact site of a tumor, the tumor size and other abnormality¹². We recommended MRI to those patients who could not specify their tumor location to avoid surgical failure. We used MRI for very limited conditions such as multiple masses or findings that were not compatible with the surgical indications. Fourteen of 66 patients underwent MRI and we could exactly localize the glomus tumor, and surgical excision and pathologic confirmation were done. False negative findings on MRI for glomus tumor have been reported¹³. In the current study, all of the patients with the characteristic signs and symptoms were clinically diagnosed, and surgical removals were decided without the help of MRI images.

To the best of our knowledge, the current report is the largest case series about glomus tumors in the finger tip. The clinical signs and symptoms are essential and sufficient to make a diagnosis of glomus tumors, and surgical excision is the treatment of choice. But many of glomus tumors were clinically found late, and conservative treatment was done for long time. On the basis of proper surgical indications, making an early diagnosis and surgical excision are essential for the complete relief of the symptoms.

REFERENCES

- 1) Tuncali D, Yilmaz AC, Terzioglu A, Aslan G. Multiple occurrences of different histologic types of the glomus tumor. *J Hand Surg Am.* 2005; 30: 161-4.
- 2) McDermott EM, Weiss AP. Glomus tumors. *J Hand Surg Am.* 2006; 31: 1397-400.

- 3) Van Geertruyden J, Lorea P, Goldschmidt D, et al. Glomus tumours of the hand. A retrospective study of 51 cases. *J Hand Surg Br.* 1996; 21: 257-60.
- 4) Al-Qattan MM, Al-Namla A, Al-Thunayan A, Al-Subhi F, El-Shayeb AF. Magnetic resonance imaging in the diagnosis of glomus tumours of the hand. *J Hand Surg Br.* 2005; 30: 535-40.
- 5) Vasisht B, Watson HK, Joseph E, Lionelli GT. Digital glomus tumors: a 29-year experience with a lateral subperiosteal approach. *Plast Reconstr Surg.* 2004; 114: 1486-9.
- 6) Gandon F, Legaillard P, Brueton R, Le Viet D, Foucher G. Forty-eight glomus tumours of the hand. Retrospective study and four-year follow-up. *Ann Chir Main Memb Super.* 1992; 11: 401-5.
- 7) Carroll RE, Berman AT. Glomus tumors of the hand: review of the literature and report on twenty-eight cases. *J Bone Joint Surg Am.* 1972; 54: 691-703.
- 8) Wood W. On painful subcutaneous tubercle. *Edinburgh Med J* 1812;8:283-91.
- 9) Masson P. Le glomus neuromyo-arteriel des regions tactiles et ses tumeurs [The neuromyo-arterial glomus of the tactile regions and their tumors]. *Lyon Chir.* 1924; 21: 257-80.
- 10) Gandhi J, Yang SS, Hurd J. The anatomic location of digital glomus tumor recurrences. *J Hand Surg Am.* 2010; 35: 986-9.
- 11) Moor EV, Goldberg I, Westreich M. Multiple glomus tumor: a case report and review of the literature. *Ann Plast Surg.* 1999; 43: 436-8.
- 12) Theumann NH, Goettmann S, Le Viet D, et al. Recurrent glomus tumors of fingertips: MR imaging evaluation. *Radiology.* 2002; 223: 143-51.
- 13) Dahlin LB, Besjakov J, Veress B. A glomus tumour: classic signs without magnetic resonance imaging findings. *Scand J Plast Reconstr Surg Hand Surg.* 2005; 39: 123-5.