

Thymoma of the Middle Mediastinum

Su Ryeun Chung, M.D., In Sook Kim, M.D., Jhngook Kim, M.D.

Thymoma is a common anterior mediastinal mass, although thymomas have occasionally been found in the neck, pulmonary hilus, or posterior mediastinum. But a thymoma within the middle mediastinum has rarely been reported. We report a thymoma arising in the middle mediastinum with a review of the literature.

Key words: 1. Thymoma
2. Mediastinal neoplasms

CASE REPORT

A 59-year-old woman presented with an abnormal mass on chest X-ray that was discovered during a routine check-up. She had lost body weight during the previous 3 months. No family history of tumors or other medical diseases was identified. We obtained a biopsy through endobronchial ultrasound and pathologically diagnosed a thymoma (type A). A systemic examination was performed, and all tests were negative. Contrast-enhanced computed tomography showed a smooth, solitary homogeneously enhanced mass measuring 3×3.5×2 cm in the right paratracheal area, which had no calcification (Fig. 1). We initially suspected Castleman disease due to the mass location. She underwent mass excision by video-assisted thoracic surgery. The resected specimen was a firm light-gray tumor with a smooth capsule that measured 4.5×3×2.5 cm. The tumor was solid and was partially composed of adipose tissue. The tumor had not invaded any other mediastinal structures and was easily extracted.

Postoperative follow-up proceeded without any problems, and the patient was discharged after 5 days. Microscopy revealed that the tumor was a thymoma (World Health

Organization type A+B2, Masaoka staging I) (Fig. 2).

DISCUSSION

The majority of thymomas are found in the anterior mediastinum. Only a few thymic masses arising out of the anterior mediastinum have been described in the literature, and these have been found in an ectopic thymus location such as the neck, pulmonary hilus, or posterior mediastinum [1,2]. A thymoma occurring in the middle mediastinum is extremely rare. The thymus arises embryologically from the third pharyngeal pouch and branchial cleft on each side. The thymic masses from each side then move toward each other and migrate from the midline to the anterior mediastinum and their final position. Failure of the thymic gland to migrate during embryogenesis leads to ectopic thymic tissue. The incidence of ectopic thymic tissue is 3% to 5% in the retroinnominate vein (i.e., a paratracheal site) [3].

Surgical resection has been used for both a firm diagnosis and treatment in previously reported cases of a middle mediastinum thymoma [4]. Endobronchial ultrasound-guided biopsy may be useful, as in this case. Sakurai et al. [5] reported that

Department of Thoracic and Cardiovascular Surgery, Samsung Medical Center, Sungkyunkwan University School of Medicine

Received: October 20, 2011, Revised: November 28, 2011, Accepted: December 1, 2011

Corresponding author: Jhngook Kim, Department of Thoracic and Cardiovascular Surgery, Samsung Medical Center, Sungkyunkwan University School of Medicine, 81 Irwon-ro, Gangnam-gu, Seoul 135-710, Korea
(Tel) 82-2-3410-3483 (Fax) 82-2-3410-0089 (E-mail) jkim@smc.samsung.co.kr

© The Korean Society for Thoracic and Cardiovascular Surgery. 2012. All rights reserved.

© This is an open access article distributed under the terms of the Creative Commons Attribution Non-Commercial License (<http://creativecommons.org/licenses/by-nc/3.0>) which permits unrestricted non-commercial use, distribution, and reproduction in any medium, provided the original work is properly cited.

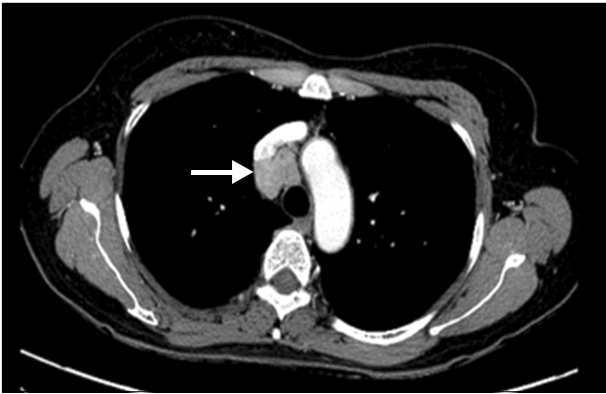

Fig. 1. Preoperative heart contrast computed tomography scan shows round shaped mass in the right paratracheal area (arrow).

¹⁸F-fluorodeoxyglucose positron emission tomography (PET) scan and ¹¹C-acetate PET are useful for diagnosing a thymoma from the middle mediastinum as ectopic thymic tissue.

Castleman disease is an atypical lymphoproliferative disorder, and masses are commonly located in the chest. Most patients are asymptomatic and lesions are accidentally found on chest X-ray as rounded mediastinal masses, often mistaken for a thymoma [6]. The most effective treatment for Castleman disease is surgical resection.

Because of malignant changes, patients with unicentric Castleman disease may need more postoperative immunosuppressive therapy or radiation. Thus, it is important to pathologically confirm the diagnosis [7].

Thymomas rarely arise in the middle mediastinum, and thymoma is not considered in the differential diagnosis of middle mediastinum masses. But thymomas appear to have malignant potential, and the overall rate of thymoma recurrence is approximately 20%. So a thymoma should be considered in the differential diagnosis of a mediastinal mass [2,8]. A complete resection of a thymoma is useful for both treatment and diagnosis.

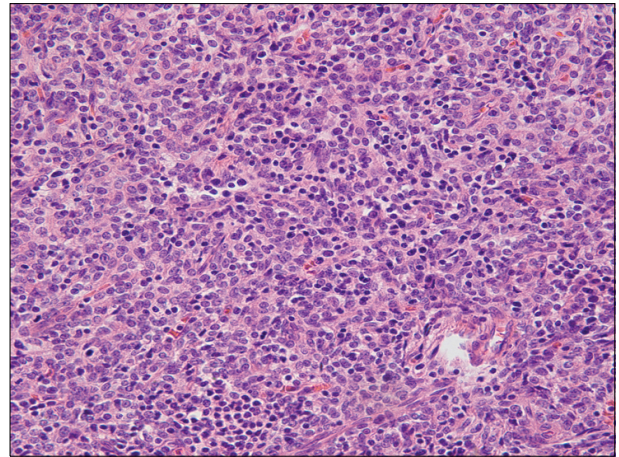


Fig. 2. Postoperative pathology slide shows the thymoma (H&E stain, ×200, Type A+B2).

REFERENCES

1. Shimosato Y, Mukai K. *Tumors of the thymus and related lesion*. In: Rosai J, editor. *Atlas of tumor pathology: fascicle 21, third series*. Washington: Armed Force Institute of Pathology; 1995. p. 33-247.
2. Kojima K, Yokoi K, Matsuguma H, et al. *Middle mediastinal thymoma*. *J Thorac Cardiovasc Surg* 2002;124:639-40.
3. Ashour M. *Prevalence of ectopic thymic tissue in myasthenia gravis and its clinical significance*. *J Thorac Cardiovasc Surg* 1995;109:632-5.
4. Nakamura H, Adachi Y, Fujioka S, Miwa K, Haruki T, Taniguchi Y. *Thoracoscopic resection of middle mediastinal noninvasive thymoma: report of a case*. *Surg Today* 2007; 37:787-9.
5. Sakurai H, Kaji M, Suemasu K. *Thymoma of the middle mediastinum: ¹¹C-acetate positron emission tomography imaging*. *Ann Thorac Surg* 2009;87:1271-4.
6. Keller AR, Hochholzer L, Castleman B. *Hyaline-vascular and plasma-cell types of giant lymph node hyperplasia of the mediastinum and other locations*. *Cancer* 1972;29:670-83.
7. Jongsma TE, Verburg RJ, Geelhoed-Duijvestijn PH. *Castleman's disease: A rare lymphoproliferative disorder*. *Eur J Intern Med* 2007;18:87-9.
8. Monden Y, Nakahara K, Iioka S, et al. *Recurrence of thymoma: clinicopathological features, therapy, and prognosis*. *Ann Thorac Surg* 1985;39:165-9.