

Redo-Coronary Artery Bypass due to Progression of the Celiac Axis Stenosis

Sang Yoon Yeom, M.D., Ho Young Hwang, M.D., Ph.D., Ki-Bong Kim, M.D., Ph.D.

We report a redo coronary artery bypass grafting (CABG) in a 55-year-old man. Angina recurred 7 years after the initial surgery. Coronary angiography showed all patent grafts except a faint visualization of the *in situ* right gastroepiploic artery (RGEA) graft, which was anastomosed to the posterior descending coronary artery, associated with celiac axis stenosis. Redo-CABG was performed at postoperative 10 years because of aggravated angina and decreased perfusion of the inferior wall in the myocardial single photon emission computed tomography. The saphenous vein graft was interposed between the 2 *in situ* grafts used previously; the right internal thoracic artery and RGEA grafts. Angina was relieved and myocardial perfusion was improved.

Key words: 1. Coronary artery bypass surgery
2. Reoperation
3. Ischemic heart disease

CASE REPORT

A 55 year-old man visited our emergency department because of increasing frequency of chest pain. He had undergone off-pump coronary artery bypass grafting (CABG) 10 years ago because of unstable angina associated with three vessel coronary artery disease. At the initial operation, the *in situ* right internal thoracic artery (ITA), *in situ* left ITA and *in situ* right gastroepiploic artery (RGEA) grafts were used to revascularize the left anterior descending coronary artery, two obtuse marginal coronary branches, and posterior descending coronary artery, respectively. An excess segment of the distal right ITA was connected to the side of left ITA as a Y-composite graft and anastomosed to the first diagonal coronary artery. Coronary angiography and myocardial single photon emission computed tomography (SPECT) were performed at

5 years after surgery as a follow-up study. The 5-year angiography showed all patent grafts and the myocardial SPECT demonstrated no perfusion decrease. Exertional chest pain recurred at 7 years after surgery, and a repeated coronary angiography showed patent previous grafts including faint visualization of the *in situ* RGEA graft associated with significant stenosis at the os of the celiac axis. The computed tomographic angiogram also demonstrated a 90% stenosis at the celiac os, which had been without stenosis on abdominal angiography taken before the surgery (Fig. 1). The myocardial SPECT, however, demonstrated no perfusion decrease. Redo off-pump CABG was performed 10 years after the initial surgery because of an increasing frequency of angina and an aggravated finding of the follow-up myocardial SPECT, which was a newly developed reversible perfusion decrease in the inferior wall (Fig. 2).

Department of Thoracic and Cardiovascular Surgery, Seoul National University Hospital, Seoul National University College of Medicine

Received: December 5, 2011, Revised: December 20, 2011, Accepted: January 25, 2012

Corresponding author: Ki-Bong Kim, Department of Thoracic and Cardiovascular Surgery, Seoul National University Hospital, Seoul National University College of Medicine, 101 Daehak-ro, Jongno-gu, Seoul 110-744, Korea
(Tel) 82-2-2072-3482 (Fax) 82-2-747-5245 (E-mail) kimkb@snu.ac.kr

© The Korean Society for Thoracic and Cardiovascular Surgery. 2012. All right reserved.

© This is an open access article distributed under the terms of the Creative Commons Attribution Non-Commercial License (<http://creativecommons.org/licenses/by-nc/3.0>) which permits unrestricted non-commercial use, distribution, and reproduction in any medium, provided the original work is properly cited.

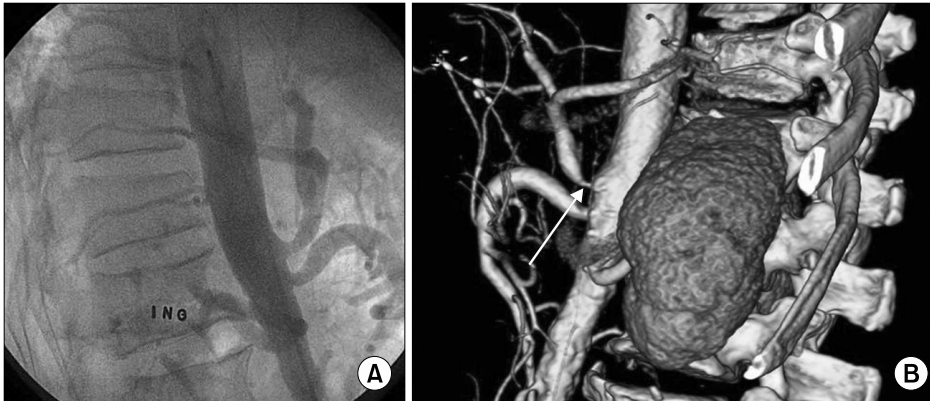


Fig. 1. (A) Abdominal aortography demonstrating no celiac axis stenosis before the initial surgery. (B) Computed tomography angiogram showed a 90% stenosis of the celiac axis os at postoperative 7 years.

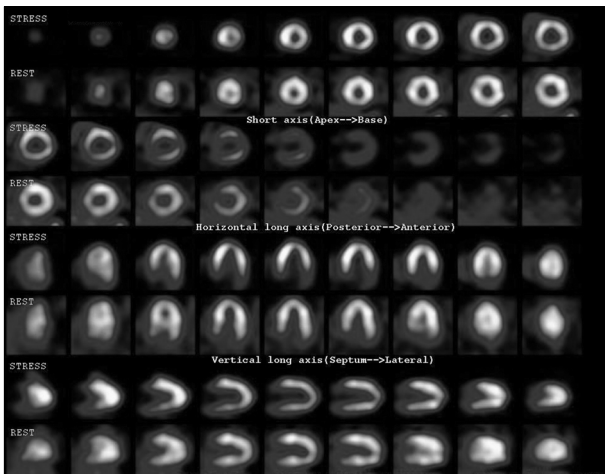


Fig. 2. Postoperative 10-year myocardial single photon emission computed tomography demonstrating a newly developed reversible perfusion decrease in the inferior wall.

At reoperation, the great saphenous vein was harvested from the lower leg and interposed between the middle part of in situ right ITA and distal part of in situ RGEA grafts used previously, to supply blood flow from the right ITA graft to the posterior descending coronary artery. The patient was discharged without any complication on the 9th postoperative day. One year after redo surgery, the patient had no symptoms of angina and coronary angiogram was performed and revealed patent grafts, including an interposed saphenous vein graft (Fig. 3A). The myocardial SPECT test was also performed and demonstrated that there was no perfusion decrease including the inferior wall (Fig. 3B).

DISCUSSION

Reoperations for coronary artery disease have been increased due to the increased number of isolated CABG [1]. The Society of Thoracic Surgeons statistics indicated that nearly 5% of the current CABG procedures done in the US were repeat surgical revascularization [2]. Angiographic indications for reoperation are progression of native coronary atherosclerosis, previous graft failure or a combination of both. One previous study demonstrated that 4 out of 400 patients who underwent CABG using the RGEA graft needed percutaneous interventions due to the RGEA graft failure during postoperative follow-up of 22 ± 11 months [3]. One of those 4 patients required an angioplasty for a newly developed stenosis of the celiac trunk. In the present case, an indication for reoperation was recurrent angina symptom even in the presence of all patent grafts. The patient had been free of angina, and the angiographic and myocardial SPECT follow-up studies revealed no abnormal findings at postoperative 5 years. When the patient suffered from recurrent angina at postoperative 7 years, coronary angiography showed a faint visualization of the *in situ* RGEA graft associated with significant stenosis at the os of the celiac axis. The 10-year follow-up myocardial SPECT test demonstrated a newly developed reversible perfusion decrease in the inferior wall.

The prevalence of celiac axis stenosis was 7.3% in a Korean population although it was lower than the previously reported incidence of celiac axis stenosis in Western populations ranged from 12.5% to 24% [4]. In the present case, significant celiac ostial stenosis was newly detected in a pa-

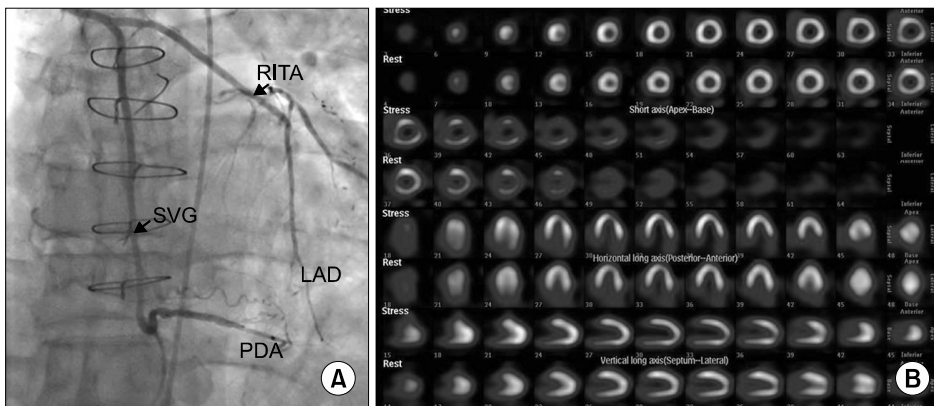


Fig. 3. (A) Postoperative 1-year coronary angiogram showing patent grafts including an interposed saphenous vein graft. (B) Postoperative 1-year single photon emission computed tomography demonstrating an improved perfusion in the inferior wall. RITA, right internal thoracic artery; SVG, saphenous vein graft; LAD, left anterior descending coronary artery; PDA, posterior descending coronary artery.

tient with recurrent angina. Celiac artery stenting could be an alternative option in such a case. However, we performed a redo operation because celiac axis stenting was associated with a high incidence of late restenosis [5]. There are several strategies in redo CABG. The aorta or another *in situ* arterial graft could be chosen as a blood source. Alternatively, patent *in situ* grafts used previously may be re-used as an inflow conduit [6]. With regards to our patient, the 3 *in situ* arterial grafts had already been used. We used the patent *in situ* right ITA graft as an inflow conduit. The saphenous vein graft was interposed between the middle part of right ITA and distal part of *in situ* RGEA grafts used previously.

REFERENCES

1. Ferguson TB Jr, Hammill BG, Peterson ED, DeLong ER, Grover FL; STS National Database Committee. *A decade of change--risk profiles and outcomes for isolated coronary artery bypass grafting procedures, 1990-1999: a report from the STS National Database Committee and the Duke Clinical Research Institute. Society of Thoracic Surgeons.* Ann Thorac Surg 2002;73:480-9.
2. Zacharias A, Schwann TA, Riordan CJ, et al. *Late outcomes after radial artery versus saphenous vein grafting during reoperative coronary artery bypass surgery.* J Thorac Cardiovasc Surg 2010;139:1511-8.e4.
3. Jegaden O, Eker A, Montagna P, et al. *Technical aspects and late functional results of gastroepiploic bypass grafting (400 cases).* Eur J Cardiothorac Surg 1995;9:575-80.
4. Park CM, Chung JW, Kim HB, Shin SJ, Park JH. *Celiac axis stenosis: incidence and etiologies in asymptomatic individuals.* Korean J Radiol 2001;2:8-13.
5. AbuRahma AF, Stone PA, Bates MC, Welch CA. *Angioplasty/stenting of the superior mesenteric artery and celiac trunk: early and late outcomes.* J Endovasc Ther 2003;10:1046-53.
6. Min HK, Lee YT, Kim WS, et al. *Complete revascularization using a patent left internal thoracic artery and variable arterial grafts in multivessel coronary reoperation.* Heart Surg Forum 2009;12:E244-9.