

Percutaneous Dilatational Tracheostomy

Young-Jae Cho, M.D., M.P.H.

Division of Pulmonary and Critical Care Medicine, Department of Internal Medicine and Lung Institute, Seoul National University Bundang Hospital, Seoul National University College of Medicine, Seongnam, Korea

For decades, the standard technique for tracheostomy was the open, surgical technique. However, during the past 20 years, the use of percutaneous dilatational tracheostomy has been increased and shown to be a feasible and safe procedure in critically ill patients. The purpose of this report is to review the percutaneous dilatational tracheostomy technique, describe the role of bronchoscopy as guidance for the procedure, and identify the available evidences comparing percutaneous dilatational tracheostomy to surgical tracheostomy.

Key Words: Tracheostomy; Surgical Procedures, Minimally Invasive; Critically Illness; Bronchoscopy

Introduction

Tracheostomy (or tracheotomy) has a long history dating back many centuries as it was first depicted on Egyptian pyramid artifacts in 3600 BC. Afterwards, it is considered that this procedure had been acknowledged as a systematic surgical method since Dr. Jackson had established a standard tracheostomy in 1909¹. Tracheostomy of that time had been used to remove a respiratory obstruction or tracheal foreign materials but due to later development of bronchoscopy and reduction of triggering diseases such as diphtheria, the needs of tracheostomy had been gradually decreased. Nevertheless, in the early 20th century, the number of patients required the mechanical ventilations began to increase in conjunction with the epidemic of paralytic poliomyelitis, the needs of tracheostomy was reconsidered in the treatment of patients. In fact, the most frequently per-

formed tracheostomy was for the airway maintenance of patients being treated with the mechanical ventilation at intensive care unit (ICU)².

In the acute setting like ICU, indications for general tracheotomy include 1) failure of weaning from mechanical ventilation, 2) such conditions which need a long-term mechanical ventilation based on neurological disorders, 3) when securing the airway patency is required to maintain proper expectoration of bronchial secretion³. Through this method, it is possible to reduce respiratory dead space and the bronchial resistance in terms of respiratory physiology and to make the suction of bronchial secretion and airway maintenance much easier in terms of nursing at ICU as well as it has advantages of mitigating discomforts from orotracheal or nasotracheal intubation in terms of patient⁴.

As tracheostomy had been performed mainly in ICU patients, other alternative surgical procedures were considered that could substitute the existing surgical tracheostomy (ST) which had been implemented in the operation room. In 1985, Dr. Ciaglia as a thoracic surgeon presented the results of successful performance of "percutaneous dilatational tracheostomy" (PDT) in 24 patients by improving the problems of existing standard tracheostomy and at the same time by using Seldinger's technique that has been widely known already and this is still cited as the first report on PDT at the most even

Address for correspondence: Young-Jae Cho, M.D., M.P.H.

Division of Pulmonary and Critical Care Medicine, Department of Internal Medicine, Seoul National University Bundang Hospital, Seoul National University College of Medicine, 166, Gumi-ro, Bundang-gu, Seongnam 463-707, Korea

Phone: 82-31-787-7058, Fax: 82-31-787-4051

E-mail: lungdrcho@snuhb.org

Received: Dec. 24, 2011

Revised: Feb. 24, 2012

Accepted: Mar. 13, 2012

up to now⁵.

Various Methods of PDT

In fact, there had been other percutaneous tracheostomies with different methods before the method developed by Dr. Ciaglia was introduced⁶⁻⁸, but they are not in current use because of their inappropriateness in terms of the procedure-related easiness and complications (Figure 1).

Ciaglia technique also had undergone modification and variations for several times since its first pre-

sentation (Figure 2), for example, in 1996, the same research group had performed this procedure in 254 patients during 10 years by using commercially produced exclusive set (Cook Critical Care Inc., Bloomington, IN, USA), resulting in very encouraging outcomes of major complications in only 4 patients including 1 death⁹.

As a single dilator with hydrophilic coating has been introduced in order to improve any discomforts and complications of the procedure likely to incur from a series of sequential dilatations, the relevant study results are constantly being presented. As a matter of fact, when studied the results of an initial stage German

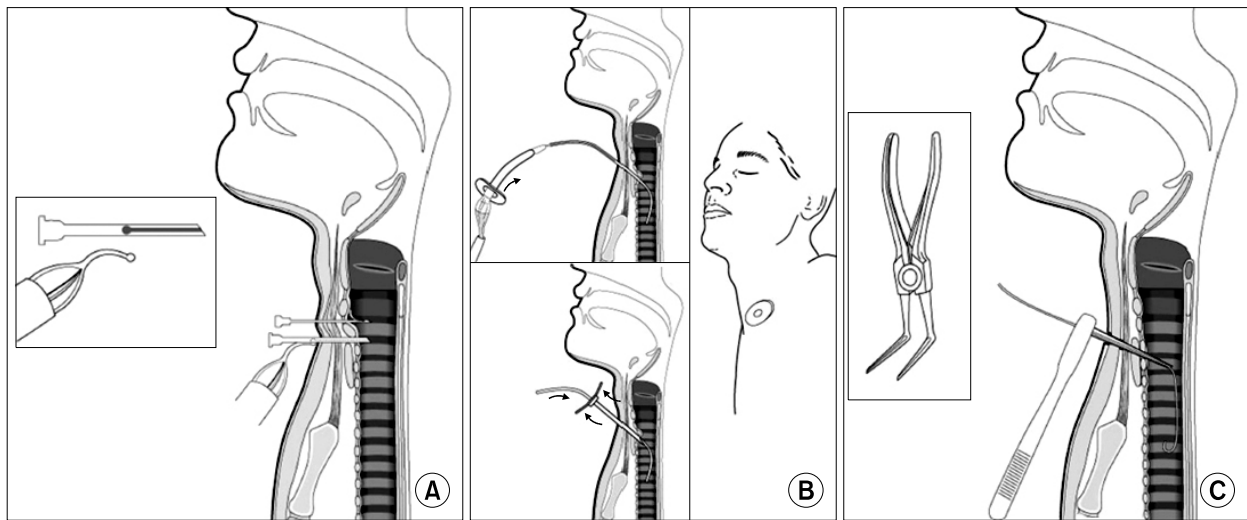


Figure 1. Methods of percutaneous tracheostomy used before Ciaglia's technique, (A) Shelden 1955, (B) Toy and Weinstein 1969, (C) Schachner 1986; quoted in Kost KM³. Reprinted from Kost KM, Laryngoscope 2005;115:1-30³.

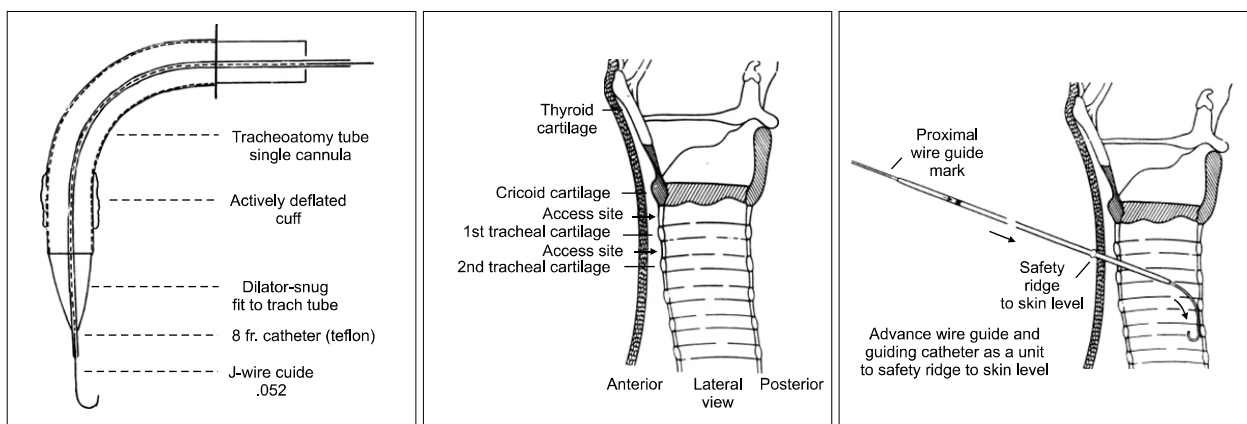


Figure 2. Ciaglia's technique. Reprinted from Ciaglia P, et al. Chest 1985;87:715-9⁵; Marx WH, et al. Chest 1996;110:762-6⁹.

study conducted in 50 patients in total in comparison to the existing methods, it was identified that the serious complications such as posterior tracheal wall injury or pneumothorax had been occurred less in the single dilator use group¹⁰, and as the result of a study conducted by a single institution of UK in 576 patients during 6 years in use of a single dilator, the researchers had defined the patients for whom PDT performance was "technically difficult" from a separate standard, which took up about 26% of total study subjects. Among them, only 3% of the entire patients had shown serious acute complications that required surgical interventions such as bleeding, subcutaneous emphysema or pneumothorax and incorrect placement of tracheostomy tube while only 0.7% of the entire patients had shown long-term complications such as tracheoinnominate artery fistula and bronchostenosis¹¹. According to one review article, it had reported that Ciaglia's technique was the most widely used technique including either single graded tracheal dilator or multiple dilators in the entire area of North America¹².

Apart from the evolution of Ciaglia's technique, different technical solutions for PDT have been attempted steadily and among them, Griggs' technique¹³⁻¹⁵ in 1990, Fantoni's technique¹⁶ in 1993 and "PercuTwist" techni-

que¹⁷ which was suggested by Frova and Quintel in 2002 are known as representative techniques. However, each respective technique was either similar or non-superior than Ciaglia's technique in actual utilization or in technical aspects in spite that they were all attempted to resolve the disadvantages of Ciaglia's technique but rather had shown worse outcomes in terms of complications, thus they are not being used to wider extent in comparison to Ciaglia's technique up to now (Figure 3).

Comparison between Surgical Tracheostomy and Percutaneous Dilatational Tracheostomy

Separately from the fact that PDT had been down to resolution to a certain extent by Ciaglia technique, far more researchers were interested in whether PDT is competitive enough or even better when compared it to existing ST in reality. It cannot be overlooked that there were some attempts to degrade the value of PDT by many otorhinolaryngology literatures at the time when PDT was introduced. In fact, the Journal of American Society of Critical Care Medicine (SCCM) had published a meta-analysis which had compared the results of ST and PDT performed before and after the introduction of Ciaglia technique, with a report that the

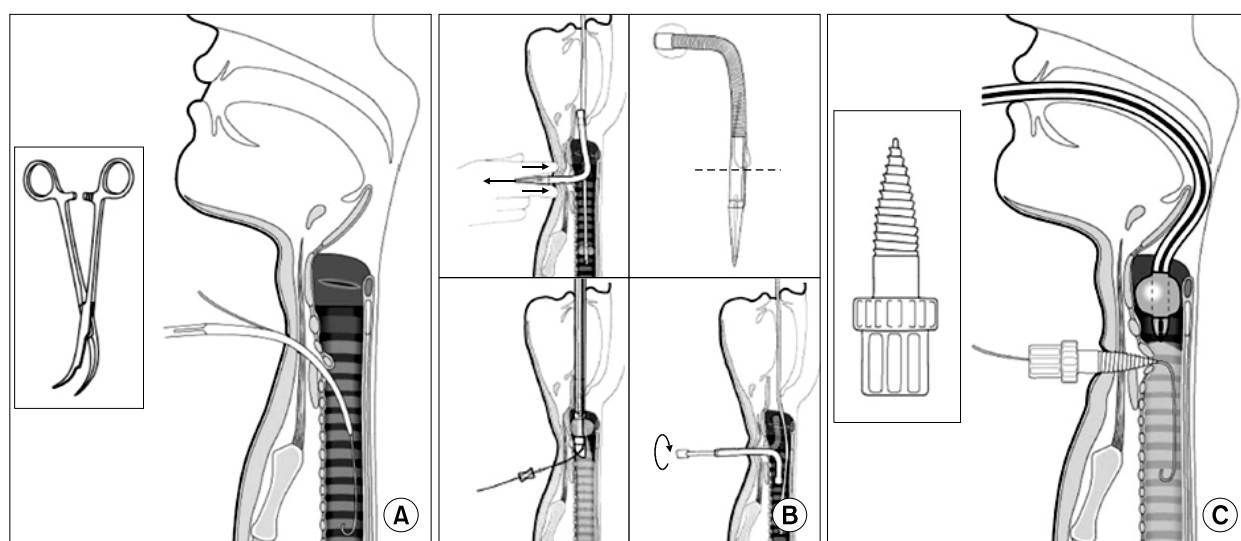


Figure 3. Post-Ciaglia's technique attempted for percutaneous tracheostomy. (A) Griggs 1990, (B) Fantoni 1993, (C) "PercuTwist" 2002; quoted in Kost KM³. Reprinted from Kost KM, *Laryngoscope* 2005;115:1-30³.

ratio of intra-procedure complications and other serious complications such as death was higher in PDT¹⁸.

However, that meta-analysis had an error of analyzing by including each different percutaneous technique all together, in the following year, another report that had analyzed researches using Ciaglia technique only did not show any statistically large differences in PDT compared to ST in terms of complications, but rather better outcomes in any infection-related problems (Figure 4) emphasizing the necessity of randomized controlled study on PDT¹⁹. In fact, when compared the results of PDT to ST in the following year, a study result had presented that PDT was much better in cost-effectiveness aspect than ST (PDT \$1,569 vs. ST \$3,172; p

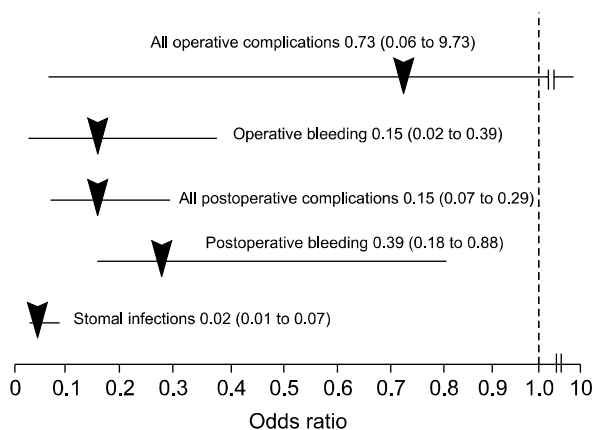


Figure 4. Odds ratio of percutaneous dilatational tracheostomy related complications in comparison to surgical tracheostomy. Reprinted from Freeman BD, et al. Chest 2000;118:1412-8¹⁹.

<0.0001)²⁰.

In 2005, Dr. Kost, a ear, nose, and throat (ENT) physician of McGill University Hospital in Canada had put the history of tracheostomy in order as well as organized all techniques of PDT existed at the time and at the same time, Dr. Kost presented an analysis result by a single institution in 191 cases with the sequential multiple dilations and 301 cases with single tapered dilation³. In this study, 9.2% of study subjects had shown the whole procedures-related complications and it was 13.6% in cases with the sequential multiple dilations and 6.5% in with the single tapered dilation, which have shown relatively lower prevalence. It was identified that the lack of procedure experience was the main factor related to complications in case of the sequential multiple dilations (Table 1). In particular, this study has not shown any single case of pneumothorax or pneumomediastinum already known in connection to PDT, and such fact was interpreted as because it was assisted by fiberoptic bronchoscopy. Consequently, it had shown that PDT could be performed safely at the equal level but with less complication when compared to ST.

Afterwards, from another meta-analysis performed in 17 randomized studies (n=1,212) PDT had shown no statistically significant difference in bleeding and death as complications when compared to ST and it was analyzed as even better in terms of infection²¹. From a randomized study that had investigated long term complications of PDT in 203 subjects, the whole procedures-related complications were shown from 3.5% as

Table 1. Comparison between the sequential multiple dilations and the single tapered dilation³

		Subgroups	Multiple	Single
Complication rates		First 30 cases	12/30 (40%)*	3/30 (10%)
		Later cases	14/161 (9%)	17/279 (6%)
		Overall	26/191 (14%)	20/309 (6%)
Subgroup characteristics	Obese among	First 30 cases	3%	13%
		Later cases	16%	20%
	ASA 4 among	First 30 cases	30%	60%
		Later cases	58%	49%

*p<0,0001.

Adapted from Kost KM. Laryngoscope 2005;115:1-30³.

Table 2. Recent randomized controlled studies by comparison of PDT to ST¹²

Patients, n	Population	Method of PDT	Procedure setting for PDT/OT
139	Medical/Surgical ICU	Translaryngeal	ICU/OR
53	Medical/Surgical ICU	Multiple dilator	ICU/OR
80	Medical/Surgical ICU	Multiple dilator	ICU/OR
53	Medical/Surgical ICU	Multiple dilator	ICU/OR
70	Medical/Surgical ICU	Multiple dilator	ICU or OR/ICU or OR
46	Medical/Surgical ICU	Multiple dilator	ICU/ICU or OR
57	Medical/Surgical ICU	Forceps	ICU/ICU
60	Medical/Surgical ICU	Multiple dilator	OR/OR
38	Medical ICU	Multiple dilator	ICU/ICU
100	Medical/Surgical ICU	Multiple dilator	ICU/ICU
50	Medical/Surgical ICU	Multiple dilator	ICU/ICU or OR
24	Surgical ICU	Multiple dilator	ICU/ICU
100	Medical/Surgical ICU	Forceps	ICU/ICU
200	Medical/Surgical ICU	Multiple dilator	ICU/ICU
16	Neurosurgical ICU	Forceps	ICU/OR
43	Medical/Surgical ICU	Single dilator	ICU/ICU
83	Medical/Surgical ICU	Multiple dilator	ICU/OR

PDT: percutaneous dilational tracheostomy; OT: open surgical tracheostomy; ICU: intensive care unit; OR: operating room. Adapted from Susarla SM, et al. *J Oral Maxillofac Surg* 2012;70:74-82¹².

lower than before, and in particular the time of procedure performance was identified with statistically significant shorter than ST. In addition, there was no difference in the procedure-related mortality rate from both groups, and no large difference in long term complications such as tracheal stenosis²².

Based on aforementioned results, there would be no problem for considering PDT in current ICU area had almost replaced ST (Table 2). However, studies in the cost-effectiveness aspect are relatively insufficient, yet even these studies reported so far had identified PDT as better.

The Reality of Percutaneous Dilatational Tracheostomy

1. Performance location

In relation to the location where PDT is to be performed, there are differences by reports, but in reality, where to perform the procedures is a problem that makes whoever, if introducing the procedures for the first time, to struggle, taking into account the ICU patient transport-related morbidity is leveled in the range

between 13~33%¹².

As prescribed by the Guideline for Transport of Critically Ill Patients, when the benefits from the procedures is higher than the transport and procedures-based risks, the transport of critically ill patients is to be considered as the extension of intensive care, and it will be possible if such transport is implemented under suitable medical supervision²³. However, it also tells a checklist of substantially detailed level should be confirmed during the process in connection to the transporting personnel, transporting equipments and intra-transporting patient monitoring. And it is questionable whether this can be applicable to ICUs of all hospitals and to all of critically ill patients in the current context of Korea.

From the literatures reported in overseas, most of them stated that the bedside PDT performance in the ICU has far better effects in terms of anesthesia-related personnel savings and the cost savings²⁴ and taking the surgical priority in the operating room into account as where the tracheostomy is postponed or canceled frequently, therefore, if safe surgical environment is provided where it can guarantee the quality level of care

and prevent any infection, it is considered that temporary use of ICU as the place to perform PDT will be possible sufficiently enough as same as other percutaneous procedures.

The issue for safe transport of patient is related to whether the early tracheostomy (ET) can be performed or not, thus such matters to consider should be regarded as more important in the medical ICU where the severity of patient is relatively higher in Korea.

2. Technical process

1) **Patient preparation (Figure 5):** First check again that the patient is a suitable subject to the tracheostomy and pre-procedure preparation should be completed. Check the results of blood coagulation test and general blood test. The patient is to be pre-treated with sedatives, analgesics and muscle relaxant and the mechanical ventilator is to be switched to the control mode followed by pre-oxygenation with 100% FiO₂. Thereafter, place two folded-sheets under the shoulders and extend the neck as much as possible. At this time, it should be checked whether there are any contraindications for the neck extension. Prep the patient for insertion of bronchoscope and arrange electrocautery in preparation of bleeding while preparing the tracheostomy set and PDT set in conformity to the surgical requirements. Prepare T-tube of appropriate size for the patient, and also ensure to prepare an adapter to connect to the mechanical ventilator after performance of PDT in advance. Adequate lighting is an essential element and the light above the bed should be ready to turn off in order to

have better look at the tip illumination of bronchoscope when checking the puncture site through a bronchoscopy later. In addition, all personnel participating in the procedures should wear sterile gowns, gloves, caps and masks in conformity to the surgery, and the aseptic field requiring for the surgery should be secured by using the surgical drape.

2) **Identification of anatomical position (Figure 6):** Ensure to make preparation for potential situation that may require ST by conducting C-spine AP/Lat in advance. Because the most patients are highly likely undergone the chest computed tomography (CT), pre-confirmations on the flow of tracheoinnominate artery or the positions of thyroids through prior-confirmations on the neck area included in the CT will be helpful. The actual incision site is usually under 1 FB from cricothyroid membrane or 1.5 or 2 FB from sternal notch. For more accuracy, below the first and above the second tracheal rings or below the second and above the third tracheal rings are the most suitable as incision site. Pre-marking of such anatomical positions and the mid-line with surgical pen will be useful. In fact, the bleeding-related structures among those structures applicable in this area are mostly anterior jugular veins and because it flows in vertical direction, it could be one of the reasons to have vertical incision in order to reduce bleeding during PDT.

3) **Preparation of local anesthesia and equipment (Figure 7):** In general a mixed solution of 2% lidocaine and epinephrine is used for local anesthesia. Before incision, PDT apparatus should be checked for readiness once again, and 14 Fr dilator and single tapered dilator

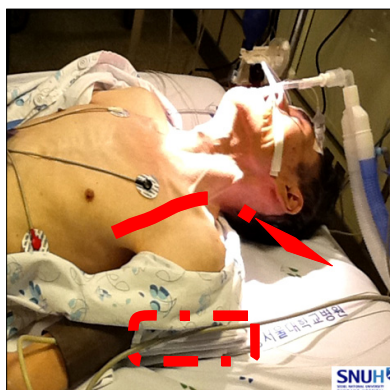
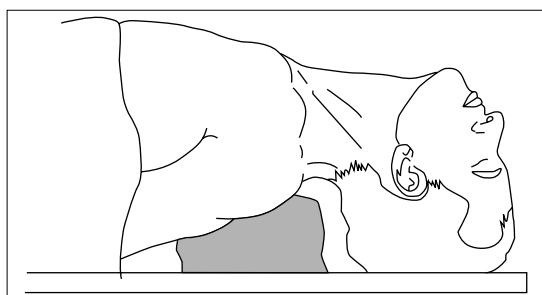


Figure 5. Look of patient with neck extension. Adapted from Kim KH, Tracheostomy. Seoul: Korean Institute of Medicine; 2007²⁵.

with hydrophilic coating should be merged in saline solution prepared in advance. Ensure the pre-mounting T-cannula to a proper sized loader is to be done using lubricant included in the set for prompt loading of T-cannula after using the single tapered dilator. If the size is not adequate, the loader may not be taken out after the final procedure is finished therefore it requires

extra-cautions.

4) **Incision and dissection (Figure 8):** Incision is to begin after checking anatomic positions. If required, prepare an electrocautery to perform the hemostasis properly. The depth of subcutaneous dissection does not need to be too deep to the extent of exposing the tracheal ring like performing ST in general, and just the

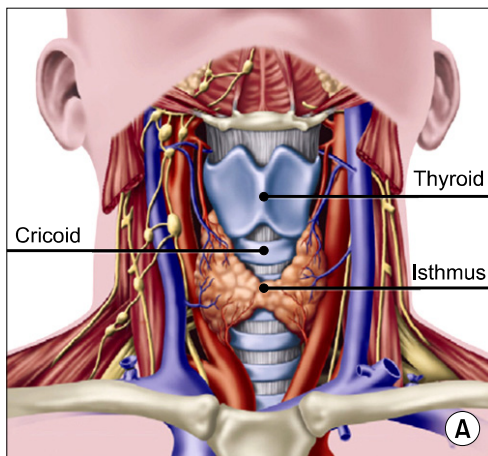


Figure 6. Anatomy of anterior neck area (A), actual look of marking on the surgical area (B). Adapted from De Leyn P, et al. *Eur J Cardiothorac Surg* 2007; 32:412-21²⁶.

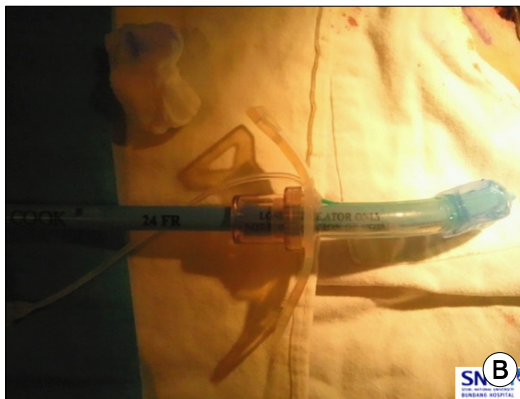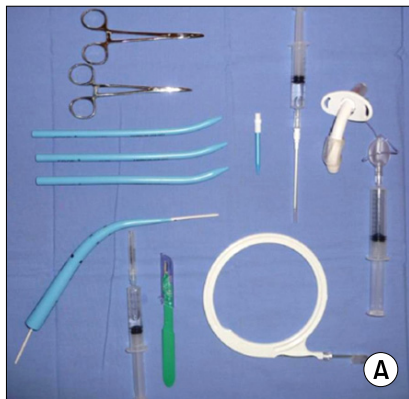


Figure 7. Percutaneous dilatational tracheostomy set (A), T-cannula with pre-mounted loader (B). Adapted from Susarla SM, et al. *J Oral Maxillofac Surg* 2012;70:74-82¹².

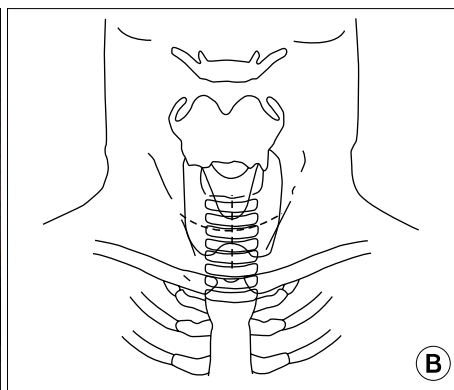
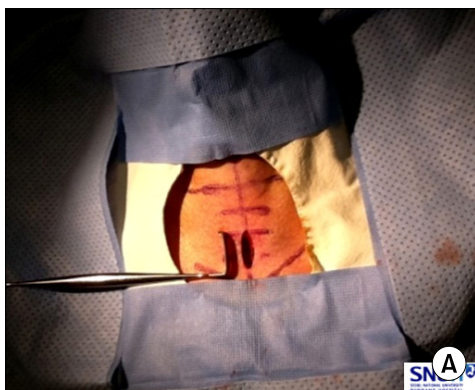

Figure 8. Post-vertical incision look compared to the retractor (A). Mimetic diagrams of the transverse incision and the longitudinal incision (B). Adapted from Kim KH. *Tracheostomy*. Seoul: Korean Institute of Medicine; 2007²⁵.

appropriate depth is to the extent that the location under bronchoscopic illumination can be checked visually from outside and the post-puncture dilator insertion does not interfere with skin or hypodermis. Whether the vertical incision or the horizontal incision is better

had been reported differently by literatures so far and in the text book, it is stated that both of them have pros and cons²⁵. Initially, it was known as Dr. Ciaglia had performed the vertical incision, and in case of the author, the vertical incision is to be done more frequently

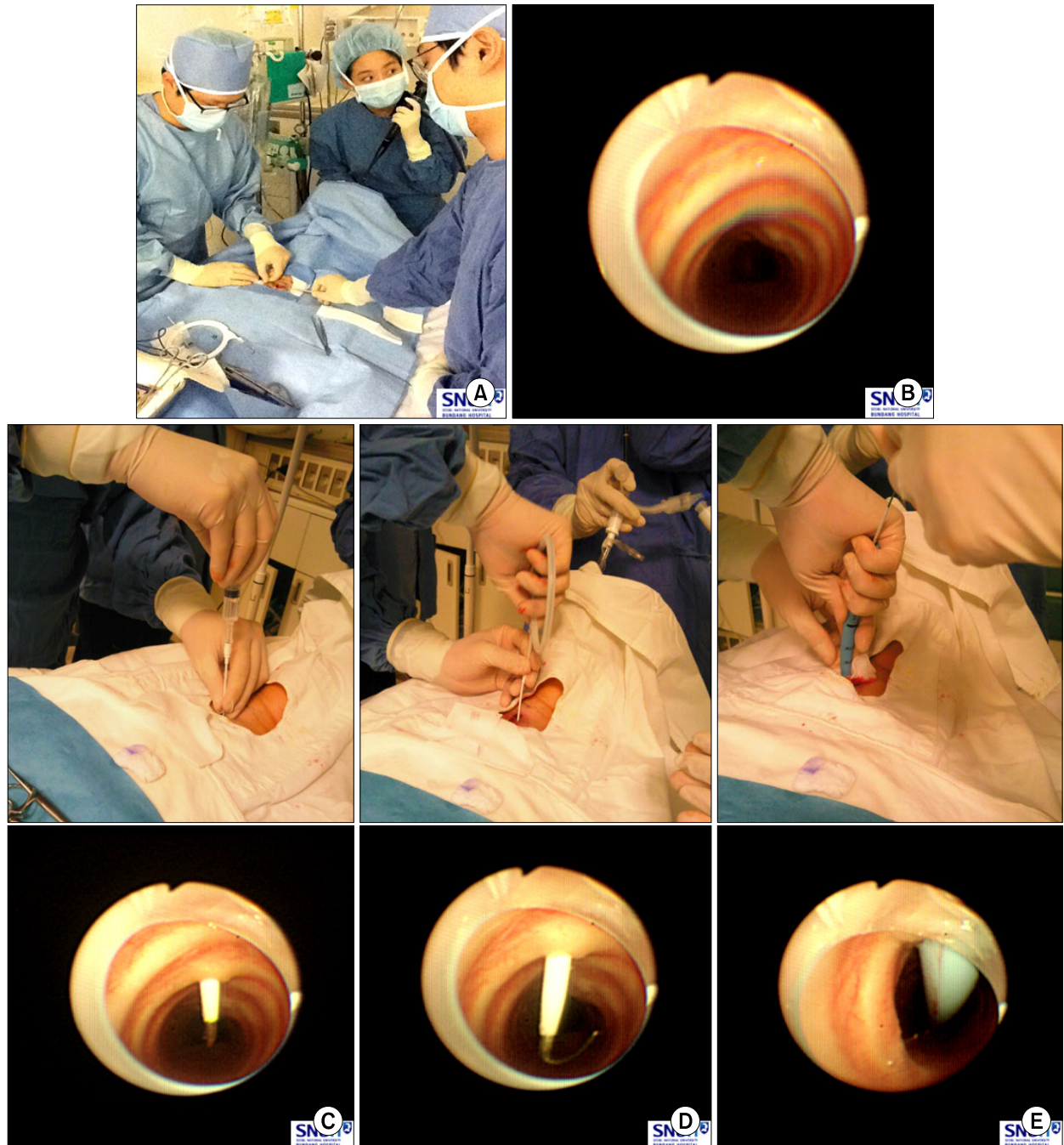


Figure 9. Personnel disposition for the procedure (A); bronchoscope positioned ensuring the tip of E-tube is visible (B); puncture, guide-wire insertion and dilator insertion (C~E).

in terms of minor bleeding, easiness of traction and selecting the position of puncture, and as the length of skin incision is far shorter than existing ST, there was nearly no cases having aesthetic problem.

5) Bronchoscope-guided tracheal puncture (Figure 9):

The most important issue is to identify the accurate point of needle insertion into the trachea where to perform the puncture. Once the incision is done, the operator put the finger for palpation to ensure the placement of E-tube right above the location of tracheal puncture, looking at the bronchoscope and confirms the position of needle to enable the puncture to be done at direction of 12 o'clock to the median while aspirating the needle. It is possible to have some bleeding in this process, but it is more important to perform the first puncture fast and accurately while compressing the bleeding with gauze if it is minor. Thereafter, the guide-wire is to be inserted while leaving the sheath inside, at this time, placing the direction of guide-wire and holding it up to carina level to that the round side in J shape can be placed at the posterior tracheal wall.

6) Dilation (Figure 10): The first dilation of soft tissue shall be done using a short dilator of about 14 Fr after removing the sheath. After having this process, a single tapered dilator shall be inserted to the white color support of guide-wire and while maintaining such state, the trans-tracheal insertion of the support shall be done along the guide wire, and the single tapered dilator is to be placed up to the level of incision entrance. When the single tapered dilator is slowly progressed with con-

sistent pressure rotating downward in conformity to the curving direction, there will be a feeling that the tissues are easily dilating by the hydrophilic film. Even if so the dilator should be inserted very gently to the position marked with the black line of single dilator without being hasty in particular. If this state is prolonged long time, ventilation by the dilator cannot be maintained, and if withdrawn the dilator, air leak will incur toward the direction, decreasing the tidal volume.

7) Insertion of tracheostomy tube and confirmation under direct bronchoscopic vision (Figure 11):

Thereby, the pre-loaded T-tube shall be inserted simultaneously with removing the dilator and then the guide wire, support and loader should be removed at the same time, only except T-tube. Perform a ballooning and detach the mechanical ventilator from E-tube and attach to T-tube, checking the tidal volume is well controlled and whether there is any problem in oxygen saturation. Before extracting E-tube, the condition of area where PDT has been evaluated by the bronchoscope, together with checking presence of tracheal ring fracture at the same time. Thereafter, the bronchoscope is to be inserted through T-tube and check the carina level as well as post-surgical bleeding, with additional performance of secretion elimination. As the final step, the originally placed E-tube is to be removed and the tracheostomy site shall be treated with dressings and the tube is secured to the skin with sutures. Tagging suture may be implementable to prevent unexpected extubation of T-tube at the early stage of operation. But once being

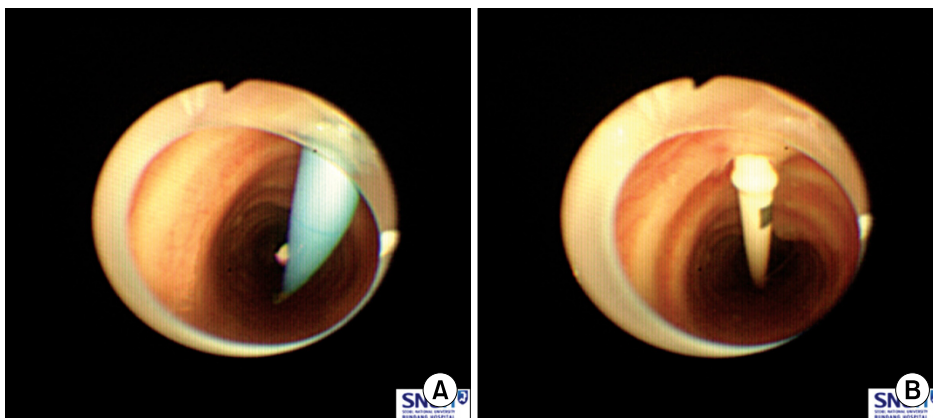


Figure 10. Insertion of a short guide dilator (A). Insertion of a support (B).

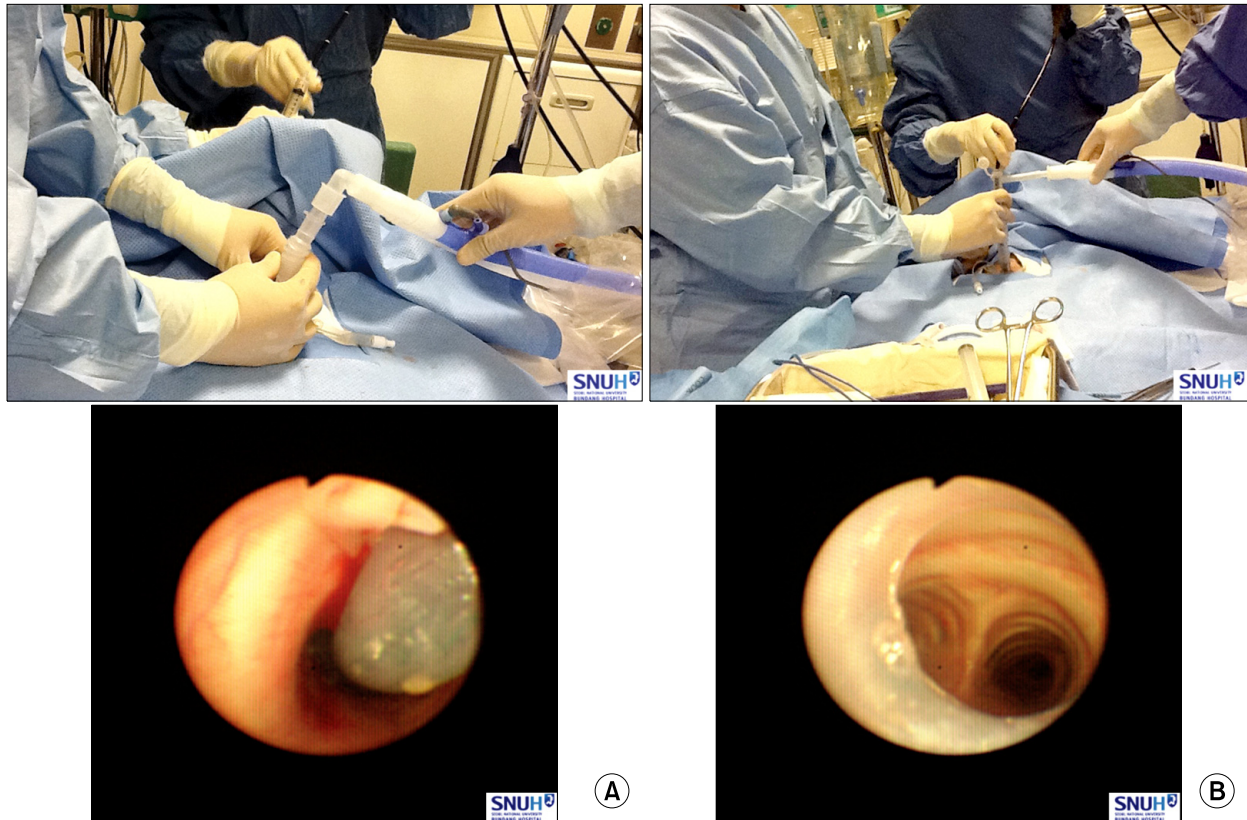


Figure 11. Checking T-tube insertion from above before E-tube removal immediately after the procedures (A). Checking below carina through T-tube immediately after the procedures (B).

familiarized with the procedure, securing with suture would not be necessary.

8) Completion of the procedures: When the procedure is completed, the vital signs of patient as well as the graph display of mechanical ventilator are to be checked. Also confirm whether any subcutaneous emphysema is developed at peri-PDT procedure site while checking the presence/absence of pneumothorax by physical examinations, and in addition, perform the chest X-ray and artery blood analysis, if necessary.

3. Role of bronchoscope

As aforementioned, Dr. Kost had emphasized the bronchoscopy should be routinely performed as compulsory during PDT because it is especially important to prevent complications. Bronchoscopic guidance during PDT was first reported by Dr. Paul in 1989²⁷, and the bronchoscopy accurately identifies the trachea's location

for the first time puncture in PDT and it plays an important role to minimize any unexpected damages to posterior tracheal wall or to esophagus, to prevent any inappropriate extubation during the procedure and also the post-procedure use of a bronchoscope enables to identify whether the tracheostomy tube is inserted correctly.

In some literatures, they recommend not to use any thin inner diameter endoscopes which are being used for children or for intubation because the intra-procedure suction of sputum is important or recommend to use the intubation tube ≥ 7.5 ID at least because the endoscope insertion escalates the peak pressure leading rather to the elevation of airway resistance in connection to the intra-procedure mechanical ventilation. However, it would be better to let the endoscopist make proper adjustment on the use of endoscope depending on the procedural status.

In particular, in order to prevent any unintentional peri-procedure extubation, the safest method is to check the puncture location by moving E-tube not the endoscope while maintaining the tip of endoscope at the directly upper side of the tip of E-tube when monitoring the location of puncture.

4. Post-procedural checklist

Through the post-operative chest X-ray, check the presence/absence of pneumothorax or pneumomediastinum. In case of subcutaneous emphysema, it can be identified mostly by the physical examination immediately after the procedure completion, but since there were cases that had shown pneumothorax or pneumomediastinum after some time was over from accidentally occurred minor posterior tracheal wall injury, it is important to make confirmation.

Replacement of endotracheal tube is not so different from ST in general. There are many cases to have the first replacement of endotracheal tube after about 7 days from completion of ST in recent days, and it has been known that the skin-tracheal fistula would be formed well mostly after 5 days later. In connection to the replacement process, some recommends to conduce the replacement by using the exchanger catheter as a must-to-do, but depending on patients, the operator can make determination with sufficient consideration. However, if the performer is inexperienced and still too early to perform, it is likely safer to have the replacement by arranging the standardized endotracheal intubation as preparation to any unexpected situation.

In some cases, any bleeding and infection are being checked by dividing the post-operative time into Day 3 and Day 7²², but in fact the procedure-related bleeding and infection are reported as very low rate by the recent reports, and even some of them argues that even the intra-procedure electrocautery is not required and that the infections are more frequently reported from ST rather than PDT. Although the literatures had not cover, but when performed with the vertical incision, some had found the lower side of tube had a bit of split of the wound when checked on it at a few days after

which requires cautions.

One of problems that should not be overlooked easily among those post-procedural complications is "tracheal ring fracture." Although each report had shown some differences, but it has been known to incur approximately from 25% to 36% and in particular some hypotheses are presented the calcified tracheal ring has high risk of fracture in the elderly patient or in rapid dilation incidence when used a single tapered dilator. Nevertheless, because there is no known data whether problems such as tracheal stenosis is likely to incur after extubation of tracheal tube at the event of tracheal ring fracture from long term follow up observation, thus it requires extra caution¹⁰.

Other Considerations

1. Contraindications for PDT

Contraindications for PDT are still controversial for its interpretation can be different by each report, but when compiled the contents described by reports from recent literatures and by those ENT specialists in Korea, it can be summarized as follows^{3,25,26,28}.

- Children (small, mobile airway)
- Unprotected airway (difficult bronchoscopic visualization)
- Emergencies in the case of essential speed
- Anterior neck anatomical problem
 - Thyroid goiter or cervical innominate artery
 - Inability to palpate cricoid cartilage
 - Obese or short-neck
 - Spinal cord injury
- Previous tracheostomy
- Severe thrombocytopenia, uncorrectable coagulopathy
- Inexperienced practitioner

However, already through many studies, there had been steady reports on the cases that PDT had been successfully performed in such existing applicable contraindications, it is considered that such criteria can be changed in the future. In spite of small sample population in the studies conducted so far, there had been

Table 3. Results when performed the early tracheostomy (ET)⁴

	ET group	LT group	p-value
No.	256	250	
VAP, n (%)	29 (11.3)	31 (12.4)	NS
Duration of MV (mean±SD, day)	13.3±9.6	16.7±8.3	0.0001
ICU LOS (mean±SD, day)	16.9±13.1	20.8±9.2	<0.0001
Hospital LOS (mean±SD, day)	41.5±26.6	42.6±23.1	NS
ICU mortality, n (%)	46 (18)	56 (22.4)	NS
Hospital mortality, n (%)	63 (24.6)	72 (28.8)	NS

Each value represents mean±SD. Percent data are referred to the total population of each group (ET and LT).

Statistical analysis: two-tailed Mann-Whitney U-test, two-tailed Fisher exact test.

LT: late tracheostomy; VAP: ventilator-associated pneumonia; NS: not significant; MV: mechanical ventilation; ICU: intensive care unit; LOS: length of stay.

Adapted from Zagli G, et al. J Trauma 2010;68:367-72⁴.

cases presented for successful performance of PDT in patients with short-neck²⁹, obesity³⁰, use of dual anti-platelet drugs³¹, hepatic diseases³² and cervical surgery³³.

2. Application of percutaneous procedures as a method of early tracheostomy⁴

There had been a discussion on the ET in the area of ICU, that indicated the physicians time to time encountered cases that the PDT could not be performed substantially because the patient whose transport became a matter of concern due to excessive hemodynamic instability or whose demand of mechanical ventilation was too high even though the physicians wanted to perform the procedures as quickly as possible. Zagli et al.⁴ in their retrospective study on PDT performed in 506 patients, had presented there were statistically significant good outcomes from the group undergone the early PDT in terms of mechanical ventilation application duration and ICU stay period (Table 3).

3. Use of ultrasound in PDT techniques³⁴

Lately, the ultrasound guided techniques are in the limelight in the area of critically ill respiratory patients, and there are quite a lot of rooms for its applications in PDT as well. In the area of neurointensivist, the safety of procedures had been improved with prior screening of anterior neck anatomy as pre-PDT procedure

preparation³⁵, whereas the real time ultrasound guided PDT being performed in patients with neurological damages had shown the results that the procedures were performed relatively successful, safe and convenient manner³⁶.

Conclusions

PDT in ICU is a safe and feasible procedure performed at bedside with minimal invasive technique. The use of single tapered dilator is preferred currently during procedure and bronchoscope-assistance is recommended to prevent peri-procedural complications. In Korea, further well-designed studies should be done to establish the clinical evidences and values, especially in the aspect of cost-effectiveness. It is expected that the Korean intensivist's promising role of this 'not-too-new' technique.

References

1. Jackson C, Jackson CL. The larynx and its diseases. Philadelphia: W. B. Saunders; 1937.
2. Zeitouni AG, Kost KM. Tracheostomy: a retrospective review of 281 cases. J Otolaryngol 1994;23:61-6.
3. Kost KM. Endoscopic percutaneous dilatational tracheostomy: a prospective evaluation of 500 consecutive cases. Laryngoscope 2005;115(10 Pt 2):1-30.
4. Zagli G, Linden M, Spina R, Bonizzoli M, Cianchi G,

- Anichini V, et al. Early tracheostomy in intensive care unit: a retrospective study of 506 cases of video-guided Ciaglia Blue Rhino tracheostomies. *J Trauma* 2010;68:367-72.
5. Ciaglia P, Firsching R, Syniec C. Elective percutaneous dilatational tracheostomy. A new simple bedside procedure; preliminary report. *Chest* 1985;87:715-9.
 6. Shelden CH, Pudenz RH, Freshwater DB, Crue BL. A new method for tracheotomy. *J Neurosurg* 1955;12:428-31.
 7. Toy FJ, Weinstein JD. A percutaneous tracheostomy device. *Surgery* 1969;65:384-9.
 8. Schachner A, Ovil Y, Sidi J, Rogev M, Heilbronn Y, Levy MJ. Percutaneous tracheostomy: a new method. *Crit Care Med* 1989;17:1052-6.
 9. Marx WH, Ciaglia P, Graniero KD. Some important details in the technique of percutaneous dilatational tracheostomy via the modified Seldinger technique. *Chest* 1996;110:762-6.
 10. Byhahn C, Wilke HJ, Halbig S, Lischke V, Westphal K. Percutaneous tracheostomy: ciaglia blue rhino versus the basic ciaglia technique of percutaneous dilatational tracheostomy. *Anesth Analg* 2000;91:882-6.
 11. Dempsey GA, Grant CA, Jones TM. Percutaneous tracheostomy: a 6 yr prospective evaluation of the single tapered dilator technique. *Br J Anaesth* 2010;105:782-8.
 12. Susarla SM, Peacock ZS, Alam HB. Percutaneous dilatational tracheostomy: review of technique and evidence for its use. *J Oral Maxillofac Surg* 2012;70:74-82.
 13. Griggs WM, Worthley LI, Gilligan JE, Thomas PD, Myburg JA. A simple percutaneous tracheostomy technique. *Surg Gynecol Obstet* 1990;170:543-5.
 14. Ambesh SP, Pandey CK, Srivastava S, Agarwal A, Singh DK. Percutaneous tracheostomy with single dilatation technique: a prospective, randomized comparison of Ciaglia blue rhino versus Griggs' guidewire dilating forceps. *Anesth Analg* 2002;95:1739-45.
 15. Fikkers BG, Staatsen M, van den Hoogen FJ, van der Hoeven JG. Early and late outcome after single step dilatational tracheostomy versus the guide wire dilating forceps technique: a prospective randomized clinical trial. *Intensive Care Med* 2011;37:1103-9.
 16. Westphal K, Byhahn C, Wilke HJ, Lischke V. Percutaneous tracheostomy: a clinical comparison of dilatational (Ciaglia) and translaryngeal (Fantoni) techniques. *Anesth Analg* 1999;89:938-43.
 17. Frova G, Quintel M. A new simple method for percutaneous tracheostomy: controlled rotating dilation. A preliminary report. *Intensive Care Med* 2002;28:299-303.
 18. Dulguerov P, Gysin C, Perneger TV, Chevrolet JC. Percutaneous or surgical tracheostomy: a meta-analysis. *Crit Care Med* 1999;27:1617-25.
 19. Freeman BD, Isabella K, Lin N, Buchman TG. A meta-analysis of prospective trials comparing percutaneous and surgical tracheostomy in critically ill patients. *Chest* 2000;118:1412-8.
 20. Freeman BD, Isabella K, Cobb JP, Boyle WA 3rd, Schmiegl RE Jr, Kolleff MH, et al. A prospective, randomized study comparing percutaneous with surgical tracheostomy in critically ill patients. *Crit Care Med* 2001;29:926-30.
 21. Delaney A, Bagshaw SM, Nalos M. Percutaneous dilatational tracheostomy versus surgical tracheostomy in critically ill patients: a systematic review and meta-analysis. *Crit Care* 2006;10:R55.
 22. Silvester W, Goldsmith D, Uchino S, Bellomo R, Knight S, Seevanayagam S, et al. Percutaneous versus surgical tracheostomy: A randomized controlled study with long-term follow-up. *Crit Care Med* 2006;34:2145-52.
 23. Fanara B, Manzoni C, Barbot O, Desmettre T, Capellier G. Recommendations for the intra-hospital transport of critically ill patients. *Crit Care* 2010;14:R87.
 24. Seder DB, Lee K, Rahman C, Rossan-Ragunath N, Fernandez L, Rincon F, et al. Safety and feasibility of percutaneous tracheostomy performed by neurointensivists. *Neurocrit Care* 2009;10:264-8.
 25. Kim KH. Tracheostomy. 1st ed. Seoul: Korean Institute of Medicine; 2007.
 26. De Leyn P, Bedert L, Delcroix M, Depuydt P, Lauwers G, Sokolov Y, et al. Tracheotomy: clinical review and guidelines. *Eur J Cardiothorac Surg* 2007;32:412-21.
 27. Paul A, Marelli D, Chiu RC, Vestweber KH, Mulder DS. Percutaneous endoscopic tracheostomy. *Ann Thorac Surg* 1989;47:314-5.
 28. Al-Ansari MA, Hijazi MH. Clinical review: percutaneous dilatational tracheostomy. *Crit Care* 2006;10:202.
 29. Tabaee A, Geng E, Lin J, Kakoullis S, McDonald B, Rodriguez H, et al. Impact of neck length on the safety of percutaneous and surgical tracheotomy: a prospective, randomized study. *Laryngoscope* 2005;115:1685-90.
 30. Romero CM, Comejo RA, Ruiz MH, Gálvez LR, Llanos OP, Tobar EA, et al. Fiberoptic bronchoscopy-assisted percutaneous tracheostomy is safe in obese critically ill patients: a prospective and comparative study. *J Crit Care* 2009;24:494-500.
 31. Cabrini L, Bergonzi PC, Mamo D, Dedola E, Colombo

- S, Morero S, et al. Dilatative percutaneous tracheostomy during double antiplatelet therapy: two consecutive cases. *Minerva Anesthesiol* 2008;74:565-7.
32. Auzinger G, O'Callaghan GP, Bernal W, Sizer E, Wendon JA. Percutaneous tracheostomy in patients with severe liver disease and a high incidence of refractory coagulopathy: a prospective trial. *Crit Care* 2007;11:R110.
 33. Romero-Ganuza J, Gambarrutta C, Merlo-Gonzalez VE, Marin-Ruiz MÁ, Diez De La Lastra-Buigues E, Oliviero A. Complications of tracheostomy after anterior cervical spine fixation surgery. *Am J Otolaryngol* 2011;32:408-11.
 34. Rodríguez SJ, Esteves LE. Real-time ultrasound-guided percutaneous dilatational tracheostomy. *Crit Care* 2011;15:443.
 35. Flint AC, Middle R, Rao VA, Lasman TE, Ho PT. Bedside ultrasound screening for pretracheal vascular structures may minimize the risks of percutaneous dilatational tracheostomy. *Neurocrit Care* 2009;11:372-6.
 36. Rajajee V, Fletcher JJ, Rochlen LR, Jacobs TL. Real-time ultrasound-guided percutaneous dilatational tracheostomy: a feasibility study. *Crit Care* 2011;15:R67.