

Removal of Bone Cement through Right Anterolateral Thoracotomy

Jin Woo Chung, M.D., Je Kyoung Shin, M.D., Hyun Keun Chee, M.D., Jun Seok Kim, M.D.,
Dong Chan Kim, M.D., Jae Bum Park, M.D.

A 55-year-old woman who had a history of percutaneous vertebroplasty was referred to our institution with sudden onset of chest pain. Computed tomography (CT) scan demonstrated a long, linear, highly-attenuated segment in the right side of the heart and fragmented pieces in the right pulmonary artery. The CT scan and echocardiogram revealed no pericardial effusion or hemothorax. Based on these findings, we performed surgery through right anterolateral thoracotomy without cardiac arrest. As a result, we safely removed the foreign body. This approach may be a feasible and effective procedure for selected cases.

Key words: 1. Foreign bodies
2. Thoracotomy
3. Bone cements

CASE REPORT

A 55-year-old woman was referred to our institution with sudden onset of chest pain. She had a history of percutaneous vertebroplasty at the 12th thoracic vertebra for osteoporotic fracture 3 weeks before she was referred to the institution. Administering sublingual nitroglycerin partially relieved the chest pain. An electrocardiogram (ECG) did not show ST-segment elevation; sinus rhythm, creatine kinase, and troponin-I were all within their respective normal limits. The patient underwent a coronary computed tomography (CT) scan and transthoracic echocardiogram (TTE) under suspicion of stable angina. The CT scan demonstrated a long, linear, highly-attenuated segment (10.5 cm in length) in the right atrium and ventricle, as well as fragmented pieces in the right pulmonary artery and its branches, causing a pulmonary embolism (Fig. 1). TTE also revealed a piece of long,

linear, echogenic material (10 cm in length) in the right atrium and ventricle. The patient was transferred to our department for emergency surgery with a diagnosis of pulmonary embolism and foreign body in the right side of the heart due to an injection of polymethylmethacrylate (PMMA, bone cement) via an injured azygos vein after percutaneous vertebroplasty. After the right anterolateral thoracotomy through the 4th intercostal space, a cardiopulmonary bypass was performed using the femoral artery, femoral vein, and superior vena cava. Immediately after incising the right atrium, a long, needle-shaped segment was located and removed under the beating heart. There were no other PMMA segments or fragmented pieces in the right atrium or ventricle. After the right atrial incision was closed, the right pulmonary artery was longitudinally incised and we removed as many fragmented pieces as possible (Fig. 2). The cardiopulmonary bypass was weaned without difficulty. The operating time was

Department of Thoracic and Cardiovascular Surgery, Konkuk University Medical Center, Konkuk University School of Medicine

Received: October 4, 2011, Revised: December 9, 2011, Accepted: December 12, 2011

Corresponding author: Je Kyoung Shin, Department of Thoracic and Cardiovascular Surgery, Konkuk University Medical Center, Konkuk University School of Medicine, 120-1 Neungdong-ro, Gwangjin-gu, Seoul 143-729, Korea
(Tel) 82-2-2030-5042 (Fax) 82-2-2030-5009 (E-mail) jekshin@kuh.ac.kr

© The Korean Society for Thoracic and Cardiovascular Surgery. 2012. All rights reserved.

© This is an open access article distributed under the terms of the Creative Commons Attribution Non-Commercial License (<http://creativecommons.org/licenses/by-nc/3.0>) which permits unrestricted non-commercial use, distribution, and reproduction in any medium, provided the original work is properly cited.

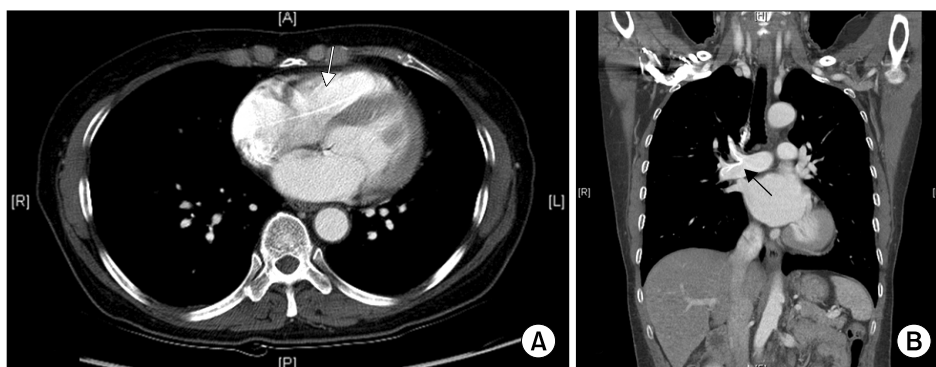


Fig. 1. A preoperative computed tomography scan. (A) A long, linear body is in the right side of the heart (arrow). (B) Fragmented pieces are present in the right pulmonary artery (arrow).

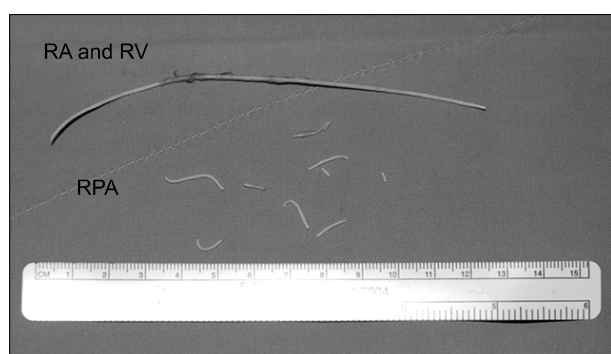


Fig. 2. Polymethylmethacrylate segments from the right atrium (RA), right ventricle (RV), and right pulmonary artery (RPA). The longer segment is present in the RA and RV, while the shorter segments are present in the RPA.

140 minutes and cardiopulmonary bypass time was 43 minutes. A post-operative TTE did not reveal residual foreign bodies in the right atrium or ventricle, and the patient did not have pulmonary hypertension. The patient recovered uneventfully and was discharged on the 10th postoperative day. The follow-up CT scan demonstrated no linear, highly-attenuated segments in the intracardiac or right pulmonary arteries; however, residual fragmented pieces that were observed pre-operatively on CT were observed in the anterior segmental artery and middle lobar artery. Six months later, the patient is doing well.

DISCUSSION

Percutaneous vertebroplasty is a widely performed and a minimally invasive surgical technique used to enhance mechanical strength by injecting PMMA into the vertebral body.

Although this procedure is effective, easy, and minimally invasive, complications, such as leakage of PMMA, may occur. A 26% to 65% incidence of PMMA leakage from the targeted vertebral body has been reported in the literature; however, the majority of leakage incidents were asymptomatic and did not require surgical treatment [1-3]. Perivertebral venous leakage has also been reported at an incidence rate of 5% to 48% in the literature, and is also usually asymptomatic [2,3]. However, some serious complications have been reported, such as massive pulmonary embolism and cardiac perforation necessitating surgical treatment [4-7].

We report a case of pulmonary embolectomy and removal of a free-floating PMMA segment in the right side of the heart via a right anterolateral thoracotomy without cardiac arrest after percutaneous vertebroplasty. Many surgical procedures to repair a perforated right ventricle, tricuspid regurgitation, incision of the main pulmonary artery, and pulmonary embolism have been performed via median sternotomy with cardiac arrest [4-7]. However, in this case, pulmonary embolism was limited to the right pulmonary artery and the PMMA segment was located in the right heart. Therefore, a right-side approach was a possible alternative. We also wanted to avoid performing a median sternotomy, if possible, due to osteoporosis. Fortunately, CT and TTE revealed no pericardial effusion or hemopericardium. Lim et al. [4] presumed that a PMMA segment in the right ventricle could not move into the pulmonary artery because of its long and stiff nature. We thought that we could remove the foreign body in the right side of the heart in a single attempt because it was long enough. Based on these findings, we performed a right anterolateral thoracotomy without cardiac arrest. We safely re-

moved the PMMA segment from the right atrium and ventricle, and successfully completed a pulmonary embolectomy. This approach may be a feasible and effective procedure for selected cases.

REFERENCES

1. Al-Assir I, Perez-Higueras A, Florensa J, Munoz A, Cuesta E. *Percutaneous vertebroplasty: a special syringe for cement injection*. AJNR Am J Neuroradiol 2000;21:159-61.
2. Cotten A, Dewatre F, Cortet B, et al. *Percutaneous vertebroplasty for osteolytic metastases and myeloma: effects of the percentage of lesion filling and the leakage of methyl methacrylate at clinical follow-up*. Radiology 1996;200:525-30.
3. Perez-Higueras A, Alvarez L, Rossi RE, Quinones D, Al-Assir I. *Percutaneous vertebroplasty: long-term clinical and radiological outcome*. Neuroradiology 2002;44:950-4.
4. Lim SH, Kim H, Kim HK, Baek MJ. *Multiple cardiac perforations and pulmonary embolism caused by cement leakage after percutaneous vertebroplasty*. Eur J Cardiothorac Surg 2008;33:510-2.
5. Son KH, Chung JH, Sun K, Son HS. *Cardiac perforation and tricuspid regurgitation as a complication of percutaneous vertebroplasty*. Eur J Cardiothorac Surg 2008;33:508-9.
6. Tozzi P, Abdelmoumene Y, Corno AF, Gersbach PA, Hoogewoud HM, von Segesser LK. *Management of pulmonary embolism during acrylic vertebroplasty*. Ann Thorac Surg 2002;74:1706-8.
7. Dash A, Brinster DR. *Open heart surgery for removal of polymethylmethacrylate after percutaneous vertebroplasty*. Ann Thorac Surg 2011;91:276-8.