

## Leiomyosarcoma of the Posterior Mediastinum Extending into the Adjacent Spinal Canal

Deok Heon Lee, M.D.<sup>1</sup>, Chang-Kwon Park, M.D.<sup>1</sup>, Dong-Yoon Keum, M.D.<sup>1</sup>,  
Jae-Bum Kim, M.D.<sup>1</sup>, Ilseon Hwang, M.D.<sup>2</sup>

Leiomyosarcoma of the mediastinum and primary leiomyosarcoma of the spine are exceedingly rare. In most cases, spinal leiomyosarcoma is metastatic. In this report, we describe the case of a 58-year-old man who presented with a large leiomyosarcoma of the posterior mediastinum that extended into the adjacent spinal canal. The tumor was completely resected from the mediastinum, but only subtotally removed from the spinal canal because the spinal mass had tightly invaded the spinal cord. Because the patient's postoperative condition was poor, no adjuvant radiotherapy or chemotherapy was administered. He expired 3 months after the surgery due to relapse; the spinal and mediastinal tumor remained at the preoperative size.

Key words: 1. Sarcoma  
2. Mediastinal neoplasms  
3. Spinal cord

### CASE REPORT

Leiomyosarcoma of the mediastinum and primary leiomyosarcoma of the spine are exceedingly rare [1-6]. Mediastinal leiomyosarcoma accounts for only about 11% of primary mediastinal sarcomas; therefore, the treatment strategy is not well established. Despite an aggressive surgical approach, as well as the use of radiation therapy and/or chemotherapy, the local recurrence rate and distant metastasis rate are high [7]. For these reasons, mediastinal leiomyosarcoma has a dismal prognosis despite multimodality treatment. In this report, we describe a leiomyosarcoma arising from the posterior mediastinum and extending into the adjacent spinal canal.

A 58-year-old man visited the hospital complaining of pleuritic chest pain on the left side, which had been present

for the previous 2 weeks. A chest radiograph revealed a large left mediastinal mass. A computed tomography scan of the chest revealed a 10×10×9 cm, well-defined, heterogeneous left posterior mediastinal mass. The mass did not appear to have invaded the bronchus, descending thoracic aorta, esophagus, vertebrae, or ribs. We then performed a computed tomography-guided percutaneous needle biopsy. Histologic evaluation revealed a low-grade spindle cell neoplasm of smooth muscle cell origin. We recommended surgical removal of the mass, but the patient refused to undergo the operation for personal reasons. After 3 months, the patient returned to the hospital due to motor weakness of both legs and urinary retention. Sensory disturbance below the T9 dermatome was also noted. A magnetic resonance imaging (MRI) scan revealed a suspected metastatic lesion involving the T7 to T10

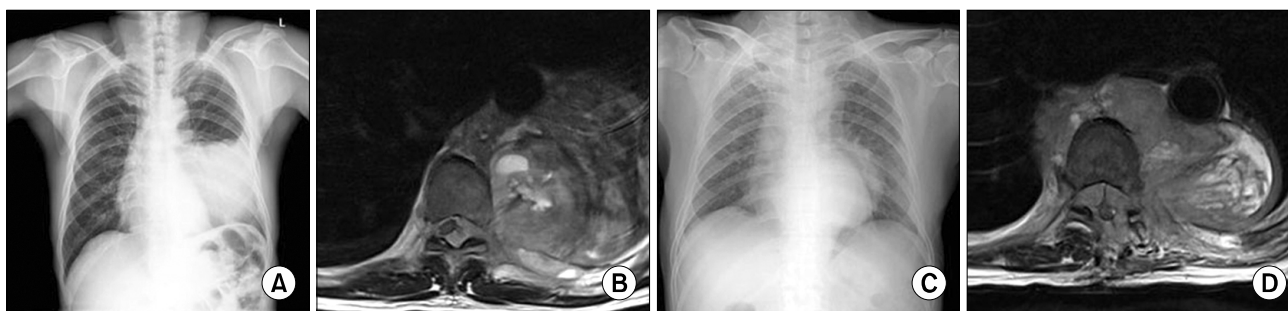
Departments of <sup>1</sup>Thoracic and Cardiovascular Surgery and <sup>2</sup>Pathology, Keimyung University Dongsan Medical Center, Keimyung University School of Medicine

Received: September 28, 2011, Revised: October 26, 2011, Accepted: November 11, 2011

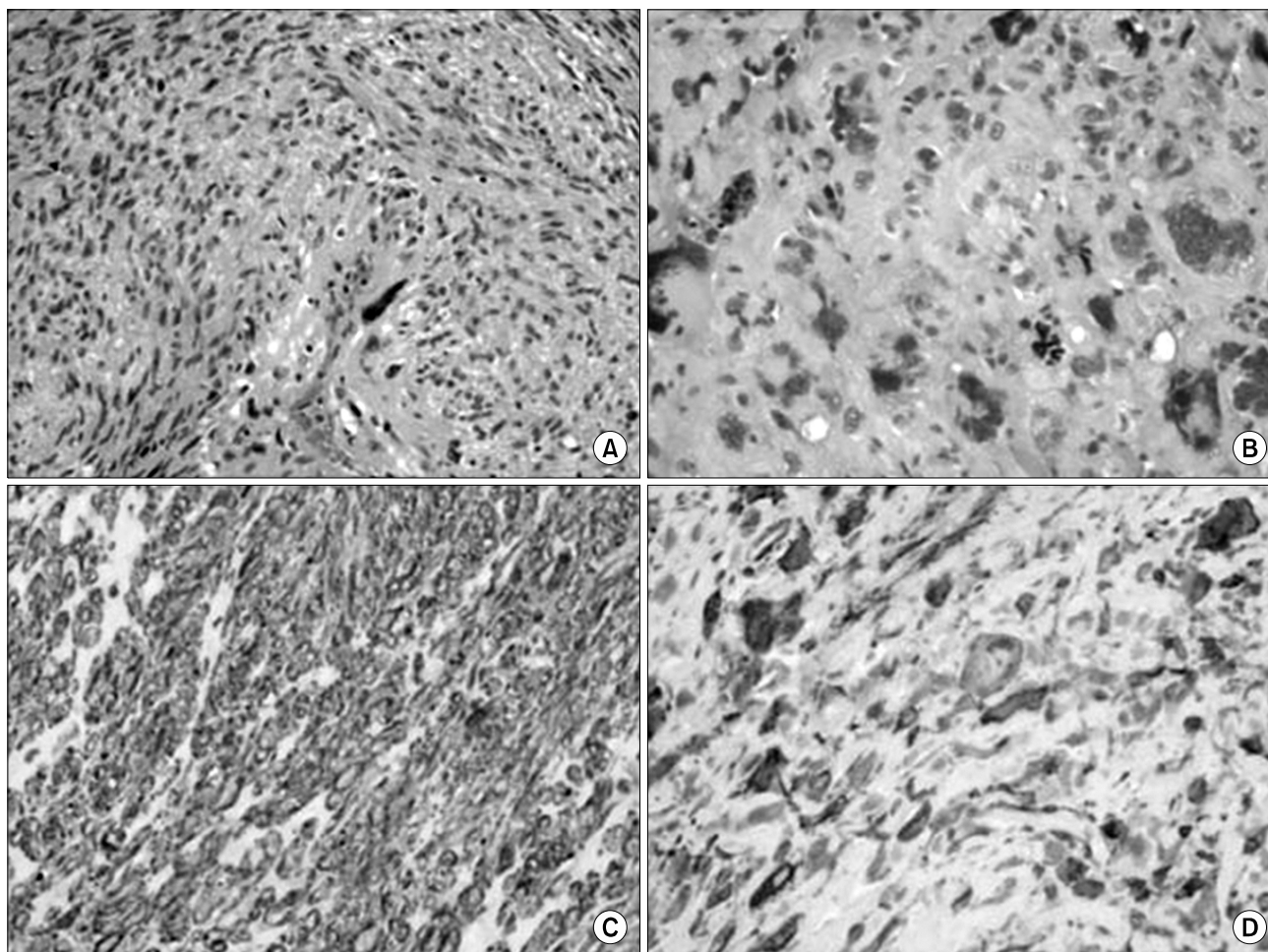
Corresponding author: Chang-Kwon Park, Department of Thoracic and Cardiovascular Surgery, Keimyung University Dongsan Medical Center, Keimyung University School of Medicine, 56 Dalseong-ro, Jung-gu, Daegu 700-712, Korea  
(Tel) 82-53-250-7342 (Fax) 82-53-250-7307 (E-mail) [ckpark80@dsmc.or.kr](mailto:ckpark80@dsmc.or.kr)

© The Korean Society for Thoracic and Cardiovascular Surgery. 2012. All right reserved.

© This is an open access article distributed under the terms of the Creative Commons Attribution Non-Commercial License (<http://creativecommons.org/licenses/by-nc/3.0>) which permits unrestricted non-commercial use, distribution, and reproduction in any medium, provided the original work is properly cited.



**Fig. 1.** Preoperative chest radiography (A) and a magnetic resonance imaging (MRI) scan (B) reveal that the tumor is invading the spinal canal. Two months after the operation, a chest radiography (C) and MRI scan (D) reveal that the tumor has relapsed in the mediastinum and spinal canal.



**Fig. 2.** (A) The mediastinal tumor contains sheets of cigar-shaped spindle cells (H&E,  $\times 400$ ). (B) The spinal tumor contains severely pleomorphic cells with frequent atypical mitoses (H&E,  $\times 400$ ). (C) The cells of the mediastinal tumor are strongly positive for smooth muscle actin ( $\times 400$ ). (D) The cells of the spinal tumor are moderately positive for smooth muscle actin ( $\times 400$ ).

vertebral bodies and a large left paravertebral soft tissue mass invading the epidural space through the left lateral spinal canal (Fig. 1A, B). A thoracotomy was performed, followed by neurosurgery. During the surgery of the mediastinum, there was no pleural adhesion despite the fact that the mass was adhered to the surrounding organs. We found that the mass was closely adhered to the descending thoracic aorta but it had not directly invaded the aorta, heart, lung, esophagus, or diaphragm. Therefore, the mass could be removed completely from the mediastinal space. However, unfortunately, we did not notice that the mediastinal mass had extended into the spinal canal because of severe fibrotic change around the spine. After the thoracotomy was completed, a laminectomy was performed from T7 to T10. We found that a yellowish soft tissue mass invading the dura mater was displacing the spinal cord to the right. Because the mass was adhering tightly to the spinal cord, it was only subtotally removed.

Gross examination revealed that the tissue resected from the mediastinum was well circumscribed and 14×10×9 cm in size with a soft and yellowish white cut surface. The tissues resected from the spinal canal area were multiple fragments of soft tissue and the cut surface was similar to that of mediastinal lesion. Microscopically, the mediastinal tumor showed variable histological findings, including sheets of cigar-shaped spindle cells with mild pleomorphism or patternless patterns of irregularly-shaped cells with severe pleomorphism. However, the spinal tumor contained sheets of severely pleomorphic cells and frequent atypical mitoses without cigar-shaped low-grade spindle cells. Immunohistochemical staining revealed that the mediastinal and spinal tumor cells were positive for smooth muscle actin, vimentin, and desmin, but negative for pancytokeratin, S-100, CD34, and CD117. The tumor was diagnosed as leiomyosarcoma. The mediastinal tumor consisted of mixed low-grade and high-grade leiomyosarcoma components but the spinal tumor consisted of only a high-grade leiomyosarcoma component (Fig. 2).

Motor weakness of the lower leg, sensory disturbance, and bladder dysfunction were resolved after the operation. Although the symptoms improved, we recommended that adjuvant radiotherapy be administered as soon as possible because the spinal mass had been removed subtotally. However, therapy was not administered because of postoperative pneu-

monia and wound infection. The tumor recurred locally 2 months later. Motor weakness rapidly worsened and finally led to paraplegia. A follow-up MRI scan showed an enlarged paravertebral soft tissue mass and epidural mass with spinal cord compression. Moreover, the left posterior mediastinal tumor recurred and invaded the ribs on the right side (Fig. 1C, D). The neurological symptoms, pneumonia, and back wound deteriorated and the patient expired 3 months after the operation.

## DISCUSSION

Leiomyosarcoma of the mediastinum and primary leiomyosarcoma of the spine are exceedingly rare. In our patient, we observed both of these rare tumors simultaneously. However, we believe that these tumors did not develop independently. We hypothesize that the tumor arising within the posterior mediastinum had extended into the adjacent spinal canal because of the following 4 reasons. 1) Primary leiomyosarcoma of the spine is extremely rare, and most spinal leiomyosarcomas are metastatic. 2) The patient showed no neurological symptoms on first admission, but the symptoms appeared 3 months later. 3) Radiological evaluations revealed that the mediastinal mass had enlarged and the spinal mass was probably metastatic and had invaded into the epidural space through the left lateral spinal canal. 4) Microscopically, the mediastinal tumor consisted of low and high-grade leiomyosarcoma components, but the spinal tumor consisted of only high-grade leiomyosarcoma components. Therefore, high-grade sarcoma of the spinal cord must have resulted from the high-grade area of the mediastinal lesion, which in turn was derived from the low-grade mediastinal lesion.

In this patient, the spinal mass was subtotally removed. In addition, adjuvant therapy was not administered because of postoperative morbidity. In the end, we lost our patient only three months after surgery.

Burt et al. [7] reported that in cases of primary sarcoma of the mediastinum, only complete resection offers a survival benefit. They also recommended aggressive adjuvant therapy because of the high incidence of local recurrence of these sarcomas despite complete resection. Hirano et al. [1] and Kidooka et al. [6] reported that leiomyosarcoma of the me-

diastinum or spinal cord progresses rapidly and relapse often occurs. Their patients expired 8 and 7 months, respectively, after the operation. However, neither commented on whether adjuvant chemotherapy or radiotherapy should be administered in such cases.

In conclusion, though complete resection is an established cure for leiomyosarcoma, radiation therapy and/or chemotherapy is still a controversial treatment. We recommend that rapid and aggressive adjuvant therapy should be administered if the tumor is subtotally removed.

## REFERENCES

1. Hirano H, Kizaki T, Sashikata T, Maeda T, Yoshii Y. *Leiomyosarcoma arising from soft tissue tumor of the mediastinum*. Med Electron Microsc 2003;36:52-8.
2. Eroglu A, Kurkcuoglu C, Karaoglanoglu N, Gursan N. *Primary leiomyosarcoma of the anterior mediastinum*. Eur J Cardiothorac Surg 2002;21:943-5.
3. Conner WC, Fink GW, McGinnis KM, Alfieris GM. *Surgical management of leiomyosarcoma of the mediastinum*. Ann Thorac Surg 2004;77:334-6.
4. Ido K, Matsuoka H, Yoshida M, Urushidani H. *Paraparesis due to spinal leiomyosarcoma lesion in the thoracic spine accompanied by two leiomyosarcoma lesions in the back and the thigh over an interval of 4 years*. J Clin Neurosci 2002;9:325-8.
5. Lo TH, van Rooij WJ, Teepen JL, Verhagen IT. *Primary leiomyosarcoma of the spine*. Neuroradiology 1995;37:465-7.
6. Kidooka M, Okada T, Takayama S, Nakasu S, Handa J. *Primary leiomyosarcoma of the spinal dura mater*. Neuroradiology 1991;33:173-4.
7. Burt M, Ihde JK, Hajdu SI, et al. *Primary sarcomas of the mediastinum: results of therapy*. J Thorac Cardiovasc Surg 1998;115:671-80.