

Extracorporeal Membrane Oxygenation Support in a Patient with Status Asthmaticus

Min Ho Ju, M.D.¹, Jeong-Jun Park, M.D.¹, Won Kyoung Jhang, M.D.²,
Seong Jong Park, M.D.², Hong Ju Shin, M.D.³

Status asthmaticus is a rare, fatal condition, especially in children. Sometimes respiratory support is insufficient with a mechanical ventilator or medical therapy for patients with status asthmaticus. In such situations, early extracorporeal membrane oxygenation application is a useful method for treating refractory respiratory failure. We report on a case of a six-year-old, male child who underwent venovenous extracorporeal membrane oxygenation support for refractory status asthmaticus.

Key words: 1. Extracorporeal circulation
2. Asthma

CASE REPORT

A six-year-old, male child with intubation status was transferred to us from another hospital. The patient had no medical history except for having had atopic dermatitis. He had been admitted to the previous hospital five days earlier due to fever and dyspnea. He was diagnosed with asthma and suspected pneumonia and was treated with antibiotics, bronchodilator nebulizers, and steroids. However, these treatments were ineffective. The patient was transferred to the intensive care unit after intubation was performed as his dyspnea had intensified with carbon dioxide (CO₂) retention, as seen on arterial blood gas analysis (ABGA). Following admission to our hospital, the patient experienced severe respiratory failure even though he was on conventional ventilator support (Table 1). We decided to perform an early application of venovenous extracorporeal membrane oxygenation (ECMO) for res-

piratory support. The patient's body weight was 20 kg, and his height was 119 cm. An outflow catheter (22 Fr; DLP, Medtronic Inc., Minneapolis, MN, USA) was inserted via the right internal jugular vein, and an inflow catheter (16 Fr; RMI, Edwards Lifesciences LLC, Irvine, CA, USA) was inserted via the right femoral vein (Fig. 1). Pump flow was maintained at 100% to 120% of the cardiac index (2.4 L/min/m²), and ECMO operated smoothly during the entire time of its use. A chest X-ray and the ABGA results showed marked improvement two days after application of the ECMO. The ECMO weaning was possible due to the significant improvement in the ABGA results along with the fact that the ventilator was on the moderate setting three days following the application of the ECMO (Fig. 2). The total support time was 62 hours. Due to the patient's continued improvement, extubation was performed the day after weaning from the ECMO was complete. The patient made a full

Departments of ¹Thoracic and Cardiovascular Surgery and ²Pediatrics, Asan Medical Center, University of Ulsan College of Medicine, ³Department of Thoracic and Cardiovascular Surgery, Konkuk University Medical Center, Konkuk University School of Medicine

Received: August 19, 2011, Revised: January 10, 2012, Accepted: January 25, 2012

Corresponding author: Jeong-Jun Park, Department of Thoracic and Cardiovascular Surgery, Asan Medical Center, University of Ulsan College of Medicine, 88 Olympic-ro 43-gil, Songpa-gu, Seoul 138-736, Korea
(Tel) 82-2-3010-3587 (Fax) 82-2-3010-6966 (E-mail) pkjj@amc.seoul.kr

© The Korean Society for Thoracic and Cardiovascular Surgery. 2012. All right reserved.

© This is an open access article distributed under the terms of the Creative Commons Attribution Non-Commercial License (<http://creativecommons.org/licenses/by-nc/3.0>) which permits unrestricted non-commercial use, distribution, and reproduction in any medium, provided the original work is properly cited.

Table 1. Arterial blood gas analysis and ventilator profiles

	On admission	Immediately after ECMO application	Shortly before ECMO weaning	After ECMO weaning
Ventilator				
PEEP (cmH ₂ O)	7	5	5	5
PIP (cmH ₂ O)	38	31	25	PS
MAP (cmH ₂ O)	20	14	20	PS
FiO ₂ (%)	100	70	50	45
ABGA				
PaO ₂ (cmH ₂ O)	60	46	65	70
PaCO ₂ (cmH ₂ O)	104	45	40	44
pH	7.06	7.49	7.51	7.48
SaO ₂ (%)	77	85	94	95

ECMO, extracorporeal membrane oxygenation; PEEP, peak end expiratory pressure; PIP, peak inspiratory pressure; MAP, mean airway pressure; FiO₂, fraction of inspired oxygen; ABGA, arterial blood gas analysis; PaO₂, partial pressure of oxygen; PaCO₂, partial pressure of arterial carbon dioxide; SaO₂, saturation of arterial blood; PS, pressure support mode.

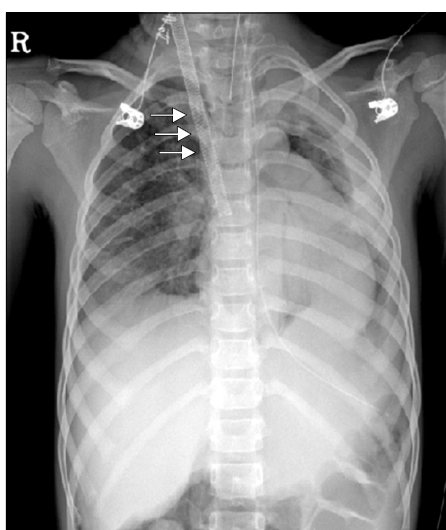


Fig. 1. Chest X-ray immediately after application of extracorporeal membrane oxygenation. There was consolidation in the left upper lung zone, and an outflow catheter was inserted into the right internal jugular vein (arrows). R, right.

mental recovery, and no neurological deficit was noted on clinical evaluation. A brain computed tomography and electroencephalography revealed no specific abnormalities. A Doppler sonography was performed on the catheter insertion

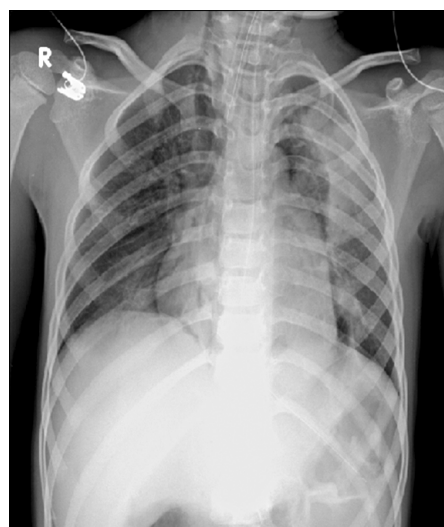


Fig. 2. Chest X-ray obtained immediately after weaning of extracorporeal membrane oxygenation. The outflow catheter was removed, and consolidation of the left upper lung zone was mildly improved. R, right.

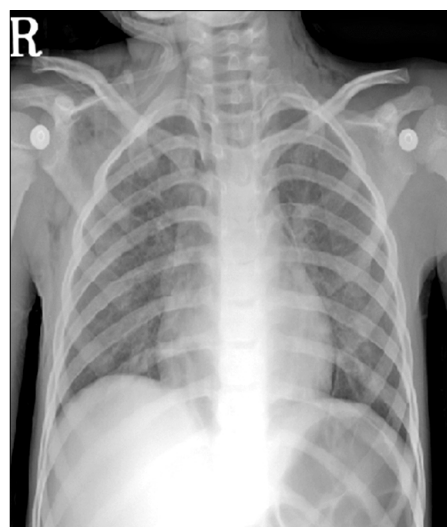


Fig. 3. Chest X-ray obtained on the day of discharge. Consolidation of the left upper lung zone was resolved. R, right.

sites, which revealed smooth luminal narrowing but showed patent vascular flow in the right internal jugular vein. The right femoral vein showed luminal narrowing and mild wall thickening, but it had patent vascular flow at the catheter insertion site. The patient's transfer to the general ward was possible on the next day following extubation. Because of the continued improvement in his general condition, the patient

was discharged without other complications (Fig. 3).

DISCUSSION

Status asthmaticus is a rare, often fatal condition, especially in children. It generally requires mechanical ventilation for acute respiratory failure [1,2]. However, occasionally CO₂ removal and respiratory support are insufficient. In such situations, ECMO has been used to treat refractory respiratory failure [3-5]. The Extracorporeal Life Support Organization (ELSO) has reported a significant increase in use of ECMO for status asthmaticus since 1995. This rise could be the result of an increasing number of centers performing ECMO, an increasing regional incidence or severity of asthma, or an overall increasing severity of the illness [4]. According to the ELSO registry, 2% (n=72) of the pediatric patients treated with ECMO were diagnosed as status asthmaticus between 1993 and 2007. Their survival rate was excellent (83%) compared to the survival rates of other diseases requiring ECMO [5]. However, there are some problems with the use of ECMO in young children. When possible, ECMO should be avoided in small children because it requires percutaneous catheter insertion, which in turn requires skin incision and major vessel exposure. Small children have small vessels, which presents the difficulty of determining accurate vessel sizing and avoiding vessel injury during this procedure [3,4]. However, despite the difficulty in accessing vessels, ECMO has several advantages for treating respiratory failure in children. The use of ECMO in asthmatic children allows their lungs to rest, thereby providing time for bronchiolar relaxation, aggressive pulmonary toilet, and even a controlled bronchoscopy, if needed for the treatment of plastic bronchitis [6]. In particular, venovenous ECMO offers the advantages of

preserved pulmonary blood flow, carotid artery preservation, improved oxygenation of the myocardium, and physiological left ventricular cardiac output to provide pulsating blood flow and normal cerebral blood flow velocities [7]. In addition, the internal jugular and femoral veins are readily accessible even in small children.

In conclusion, early ECMO application is a useful method for treating pediatric patients with refractory status asthmaticus despite the necessity of treating them with a mechanical ventilator and conventional medical therapies. In our case, we performed early ECMO and obtained positive results.

REFERENCES

1. Werner HA. *Status asthmaticus in children: a review*. Chest 2001;119:1913-29.
2. Chiang BL, Hsieh CT, Wang LC, et al. *Clinical course and outcome of children with status asthmaticus treated in a pediatric intensive care unit: a 15-year review*. J Microbiol Immunol Infect 2009;42:488-93.
3. Shapiro MB, Kleaveland AC, Bartlett RH. *Extracorporeal life support for status asthmaticus*. Chest 1993;103:1651-4.
4. Hebbbar KB, Petrillo-Albarano T, Coto-Puckett W, Heard M, Rycus PT, Fortenberry JD. *Experience with use of extracorporeal life support for severe refractory status asthmaticus in children*. Crit Care 2009;13:R29.
5. Zabrocki LA, Brogan TV, Statler KD, Poss WB, Rollins MD, Bratton SL. *Extracorporeal membrane oxygenation for pediatric respiratory failure: survival and predictors of mortality*. Crit Care Med 2011;39:364-70.
6. Nussbaum E. *Pediatric fiberoptic bronchoscopy: clinical experience with 2,836 bronchoscopies*. Pediatr Crit Care Med 2002;3:171-6.
7. Pettignano R, Fortenberry JD, Heard ML, et al. *Primary use of the venovenous approach for extracorporeal membrane oxygenation in pediatric acute respiratory failure*. Pediatr Crit Care Med 2003;4:291-8.