

Early Results of Cryosurgery in Varicose Veins in Korea: Safety and Feasibility

Eun Jue Yi, M.D., Sung Ho Lee, M.D., Jong Ho Cho, M.D., Kwang-Taik Kim, M.D.

Background: Cryosurgery was recently introduced as a treatment for varicose veins in the lower extremities. Cryosurgery with freezing probes can be used to remove the great saphenous vein (GSV) via an inguinal incision alone. The aim of this study was to assess early outcomes and the feasibility of cryosurgery for varicose veins. **Materials and Methods:** Forty patients were enrolled in the present study from March 2009 to July 2010. All patients underwent careful physical examinations, and their GSV reflux was demonstrated by duplex ultrasonography. Clinical severity was measured according to the clinical-etiology-anatomy-pathophysiology (CEAP) classification. The impaired GSVs were removed with rigid cryoprobes after freezing. Patients had follow-up appointments at 1 week, 1 month, 3 months, and 6 months after surgery. Sclerotherapy was performed during follow-up on an outpatient basis as needed. **Results:** A total of 19 men and 21 women were enrolled. The mean follow-up duration was 3.4 months (range, 1 to 12 months). The clinical severity ranged from CEAP 2 to CEAP 6a. Thirty-eight patients underwent concomitant phlebectomy during surgery. No recurrences were reported during follow-up. There were three cases of minor complications. Two patients had paresthesia, and one had thrombophlebitis. **Conclusion:** Using cryosurgery techniques to treat varicose veins, the complication rates were minimal and outcomes were comparable to those of previous reports. This procedure is a safe and feasible treatment modality for varicose veins.

Key words: 1. Saphenous vein
2. Cryosurgery
3. Varicose veins
4. Safety

INTRODUCTION

Although there are many treatment modalities for varicose veins, no single method represents a gold standard. Most varicose veins are caused by incompetent saphenofemoral junctions (SFJ) and great saphenous vein (GSV) reflux, and therefore most treatment modalities are designed to address these problems. The standard treatment for varicose veins caused by GSV reflux is ligation of the vein at the SFJ, followed by

stripping of the GSV from the groin to just below the knee.

Cryosurgery, including SFJ ligation and cryostripping of the GSV, is an effective treatment for varicose veins. The use of cryosurgery was introduced in 1978, and was first clinically applied in 1982. It is not considered the gold standard for treating SFJ incompetence or GSV reflux, but it is widely used because it is a less traumatic procedure and has lower rates of postoperative morbidity, and the complication rates are similar to those of traditional stripping [1].

Department of Thoracic and Cardiovascular Surgery, Korea University Anam Hospital, Korea University College of Medicine

Received: September 19, 2011, Revised: November 17, 2011, Accepted: November 25, 2011

Corresponding author: Kwang-Taik Kim, Department of Thoracic and Cardiovascular Surgery, Korea University Anam Hospital, Korea University College of Medicine, 73 Incheon-ro, Seongbuk-gu, Seoul 136-705, Korea
(Tel) 82-2-920-5369 (Fax) 82-2-928-8793 (E-mail) ktkim@korea.ac.kr

© The Korean Society for Thoracic and Cardiovascular Surgery. 2012. All right reserved.

© This is an open access article distributed under the terms of the Creative Commons Attribution Non-Commercial License (<http://creativecommons.org/licenses/by-nc/3.0>) which permits unrestricted non-commercial use, distribution, and reproduction in any medium, provided the original work is properly cited.




Fig. 1. The cryomachine used for the cryosurgery of varicose veins (Metrum CryoFlex).

We have applied cryosurgery to treat varicose vein patients with SFJ incompetence, GSV reflux, and visible trunk varicosities since 2009 at our institution. Cryosurgery is cheaper than other less invasive techniques and requires less surgical time than conventional methods. In this report, we outline the clinical results of our experiences and describe the feasibility of cryosurgery for the treatment of varicose veins.

MATERIALS AND METHODS

A total of 40 patients underwent cryosurgery for the treatment of varicose veins from March 2009 to July 2010 at our institution. The physicians performed a careful examination of the patients and took their histories, and duplex ultrasonography was obtained for all of the enrolled patients. The patients with incompetent SFJ and GSV reflux as demonstrated by duplex ultrasonography were enrolled in this study. Clinical severity was assessed according to clinical-etiology-anatomy-pathophysiology (CEAP) classification.

Our goal was to achieve one-day surgery for each patient. Exceptions were made when patients desired a longer hospital stay for personal reasons or when the physicians concluded that the patients required additional treatment such as intravenous antibiotic injections due to skin ulcers or phlebitis before or after surgery. General anesthesia was preferred, but




Fig. 2. Conventional straight cryoprobe.

was avoided when comorbidities were expected to increase post-surgical morbidity.

The duplex ultrasonography investigations were performed with an ultrasound system (Zone Ultra; Zonare Medical Systems, Mountain View, CA, USA). Reflux in the GSV and the SFJ was defined as retrograde flow lasting longer than 0.5 seconds. The GSV was mapped before surgery on the skin from the SFJ to the most distal point at the knee via ultrasonography.

Examination by duplex ultrasonography was performed again during surgery. Cryostripping involves ligation and division of the GSV at the confluence of the GSV and the femoral vein at the level of the hiatus saphenous, followed by vein removal with a cryomachine and cryoprobe (Metrum CryoFlex; Spolka, Blizne, Poland) (Figs. 1, 2).

Under the guidance of duplex ultrasonography, a small incision was made in the skin 1 cm below the SFJ. Entrance to the SFJ was confirmed, and the proximal part of the GSV was ligated (Fig. 3). The cryoprobe was then inserted into the opening of the ligated GSV. The location of the cryoprobe was identified with duplex ultrasonography.

Tumescence (injection of 100 to 200 mL of 0.1% lidocaine) was induced around the cryoprobe to protect the surrounding structures. The tip was frozen for 10 to 15 seconds. Expansion of N_2O in the tip of the cryoprobe produced temperatures of $-85^{\circ}C$ in only a few seconds. During freezing, an iceball forms at the tip of the cryoprobe, which enables attachment of the tip to the vascular wall. Dissection of the GSV was obtained by withdrawing the cryoprobe in the direction of the entrance (Fig. 4).

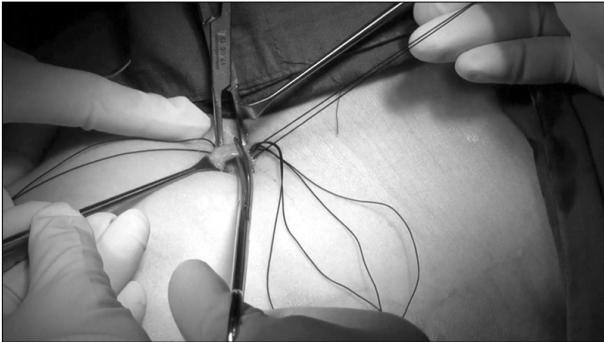


Fig. 3. Ligation and division at the confluence of the great saphenous vein with the femoral vein.

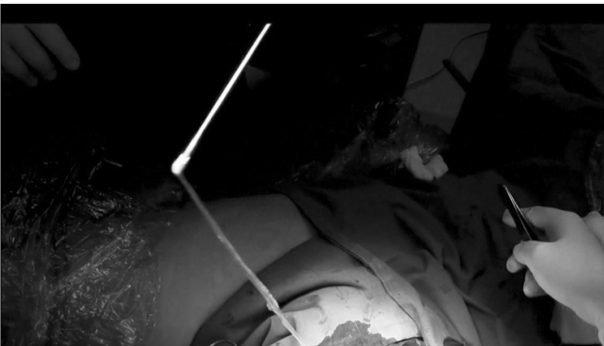

Fig. 4. The great saphenous vein was removed with a cryoprobe.

Compression was performed to control bleeding after the removal of the vein. Dissection of remnant varicosities in the tributary veins with tiny stab avulsions was performed if needed. Compression bandages were applied at the end of the procedure. Conservative therapy such as wearing compression stockings for 6 to 8 weeks, physical exercise, or elevation of the affected limbs was recommended as supplementary treatments.

It was recommended that patients revisit the hospital 1-week, 1-month, 3-months, and 6-months after surgery. At each visit, physical examinations and ultrasonography were performed to identify complications or recurrence. Sclerotherapy was performed to treat remnant varicosities in the tributary veins that remained after the 1-month follow-up. Surgical results were estimated by duplex ultrasonography.

Table 1. Preoperative demographics and data

Variables	Data (n=40)
Age (yr)	51.52±13.00
Sex (male:female)	21:19
Symptoms	
Asymptomatic	8 (20)
Pain	27 (67.5)
Heaviness	4 (10)
Fatigue	1 (2.5)
CEAP classification	
Stage 2	28 (70.0)
Stage 3	6 (15.0)
Stage 4a	4 (10.0)
Stage 4b	1 (2.5)
Stage 6	1 (2.5)

Values are presented as mean±standard deviation or number (%). CEAP, clinical-etiology-anatomy-pathophysiology.

RESULTS

The mean patient age was 51.52 years old (range, 19 to 72 years). The male to female ratio was 19:21. Four patients had histories of previous operations to treat varicose veins with endovenous laser therapy, and all four required reoperation due to recanalization.

The preoperative symptoms of the patients and the CEAP classifications are noted in Table 1. The most common symptom was pain (67.5%), and 27 patients presented with aches of the lower extremities at night or after working. Eight patients had no symptoms despite obvious trunk varicosity and GSV reflux. The CEAP stages of the patients varied from C2 to C6, with 95% of limbs CEAP 2, 3, or 4. The most common stage was CEAP 2. One patient had a severe ulcer, classified as CEAP stage 6, and needed antibiotic therapy before and after surgical treatment.

Twenty-six (65%) patients were treated in the day-surgery program. One patient was recommended to stay in the hospital for 2 weeks due to severe leg ulcers that required extra treatment. Eleven patients spent about 3 days in the hospital each for personal reasons. The average hospital stay was 2.68 days.

Fourteen patients underwent cryosurgery on both legs, 13 patients on the right leg, and the remainder on the left leg.

Table 2. Postoperative complications

	No. of patients (n=40)	%
Deep vein thrombus	0	0.0
Skin burn	0	0.0
Hyperpigmentation	0	0.0
Ecchymosis	0	0.0
Erythema	0	0.0
Hematoma	0	0.0
Clinical phlebitis	1	2.5
Paresthesia	2	5.0

Ambulatory phlebectomy was performed in all patients except for two during surgery. The average operation time was 65.75 minutes.

The mean follow-up period was 3.4 months. No recurrences were reported. Sclerotherapy was performed as an outpatient procedure when remnant varicosity was detected during follow-up in 13 patients. Postoperative complications are summarized in Table 2. All complications were minor and recovered without any sequelae.

DISCUSSION

Lower extremity varicose veins are common. The prevalence ranges from 20% to 25% in women and 10% to 15% in men [2]. In many studies, female sex has tended to be a risk factor for this disorder. However, in the Edinburgh Vein Study, 32% of randomly selected women and 40% of randomly selected men showed trunk varicosities [3]. Currently, family history is the most important risk factor for varicose veins; other risk factors are age, pregnancy, obesity, and prior deep vein thrombosis [4].

The failure of superficial venous systems in the lower extremities is a known cause of the disease. Such failure occurs when one-way valves located at intervals along the main superficial veins, which contribute to normal drainage of the venous system, lose their function. If the valves are damaged, the affected veins are referred to as incompetent, and the blood refluxes. As a result, venous hypertension develops in the affected veins and tributaries, and causes these veins to become enlarged, which results in "varicose veins."

The most common clinical presentations of varicose veins

are large and bulging varicosities in the lower extremities. Patients with chronic superficial venous incompetence often have edema, hyperpigmentation, or skin ulceration. Many patients also have symptoms such as itching, pain, heaviness, or edema. However, the existence of trunk varicosity is not directly related to these symptoms. About 40% of patients with visible varicose veins have no symptoms. Of these patients, only a small portion will develop complications such as thrombophlebitis, eczema, lipodermatosclerosis ulceration, or deep vein thrombosis.

Treatments are as variable as the clinical appearances of varicose veins. Many modalities including conservative therapy, surgical intervention, and other newly developed, less invasive techniques can be employed. Treatment choices depend on the results of clinical examination and the findings of duplex ultrasonography.

Most treatment modalities focus on the elimination of GSV reflux, as the majority of varicose veins are explained by SFJ incompetence. The ligation and stripping of the GSV may become a standard treatment. Minimally invasive techniques such as endovenous laser therapy or radiofrequency ablation are also acceptable.

Before attempting interventional therapy, patients are often encouraged to pursue conservative management, and compression stockings are most commonly used. Other options include exercise, weight loss, and elevation of the affected legs. These methods reduce pressure on impaired vein valves, and therefore may improve symptoms. Except for patients with minor problems, however, most patients prefer to pursue more definitive interventional treatments.

As mentioned above, several methods can be applied for the treatment of GSV reflux and associated large varicosities. Conventional surgery may be related to more adverse events, more pain, more frequent hospital stays, or greater requirements for analgesic drugs. Many efforts have been made to seek less invasive techniques.

Endovenous laser therapy was first reported in 1999, and was approved as a treatment in 2002 by the United States Food and Drug Administration [5]. Endovenous radiofrequency ablation was first described by Goldman in 2000 [3]. Both treatments use heat-generating material, like laser fibers or catheters, which are positioned intravenously through small

catheters puncturing the impaired vein. Heat generated by the laser or radiofrequency energy causes endothelial damage, contraction of the vein wall, and ultimately destruction of the impaired vein.

Both types of therapies constitute minimally invasive treatments. Many studies have reported their superiority to conventional surgery and that they result in less pain, a shorter operation time, and better cosmetic effects. However, some patients have reported higher rates of paresthesia and skin burns, which are probably related to the application of heat energy. Radiofrequency ablation may increase the risk of deep venous thrombosis. Although both therapies seem to reduce the length of hospital stay, they also cost more than other treatment modalities.

The long-term benefits are equivocal. Initial occlusion rates for endovenous laser therapy were reported to be 90% to 95% [6], and those of endovenous radiofrequency ablation were reported to be 90% to 96% [7]. However, without SFJ ligation, there remains a risk for recanalization. No long-term results regarding these minimally invasive endovenous techniques in comparison with conventional surgery have been reported. Some guidelines recommend that these techniques are suitable for non-tortuous and less enlarged veins [8].

Cryosurgery, which is basically similar to conventional surgery, consists of SFJ ligation and GSV removal. This method requires a small incision in the groin area, unlike the minimally invasive techniques described above, but does not require additional small incisions above the knee, which are required in conventional surgery to fix the GSV before extraction. Cryosurgery eliminates the GSV so that varicose veins cannot recur via recanalization.

The concept of using cryosurgery in the lower extremity varicose veins was first introduced in 1978, and its clinical applications were achieved in 1982 with the invention of the vascular cryoprobe [9]. The basic principle of the treatment is simple: perform ligation and division of the GSV at the junction of the femoral vein and GSV at the level of the hiatus saphenous, and then GSV removal with the cryoprobe by freezing.

Low temperatures can be produced using N₂O or CO₂ gas, as low as -85°C. In a few seconds, an ice ball can form at the tip of an endovenous cryoprobe, which makes endovas-

cular cryoadhesion possible without requiring a distal incision. Cryoprobes are usually straight rods, but some clinicians use curved cryoprobes with flexible guide tips [10]. New cryoprobes easily advance from the root of the GSV intravenously far enough to avoid being mistaken by enlarged tributaries and entering the wrong vein. We use conventional straight cryoprobes, and we are able to identify the location of the tip during surgery to prevent the cryoprobe from entering the wrong veins.

The superiority of cryosurgery over conventional surgery is clear. Cryosurgery requires less surgical time, leads to fewer complications, and necessitates fewer hospital days. Cryosurgery can be performed in one-day programs, and therefore allows patients to return earlier to the activities of daily life. The only disadvantage compared to conventional surgery is that cryosurgery is more expensive because it requires a cryoprobe and nitrogen tank [11].

Considering its costs, cryosurgery is expected to be slightly superior to minimally invasive techniques. In a study comparing the cost-effectiveness of cryosurgery and endovenous laser therapy, the total costs of endovenous laser therapy were higher than cryosurgery, although both therapies yielded similar therapeutic results [12]. We were unable to find randomized clinical studies regarding the differences in costs between radiofrequency ablation therapy and cryosurgery, but the former is expected to be more expensive because of the use of ablation catheters and power sources. Cryosurgery has also proved to have advantages over other therapeutic techniques for treating incompetent perforating veins [13].

In combination with phlebectomy or sclerotherapy, cryosurgery is expected to be more successful. Phlebectomy, which requires performing several tiny stab incisions and extracting small veins with specially designed hooks, is essential for the removal of small varicose veins that belong to neither the GSV nor the small saphenous vein. All of our patients except for two underwent phlebectomy during surgery after extraction of the GSV with the cryoprobe for the removal of visible varicosities.

Sclerotherapy, or the injection of liquid chemicals (usually called sclerosants) into varicose veins, causes inflammation, occlusion, and scarring. Sclerotherapy is usually an outpatient procedure performed under local anesthesia. Thirteen of our

patients underwent this treatment during follow-up for the treatment of small remnant varicosities. We used 1% sotradecol, 1:1 diluted with normal saline. No complications associated with these therapies were observed in our study.

Complications after cryosurgery can vary post-operational pain, hematoma, skin pigmentation, and paresthesia are the primary problems. Two patients in our sample complained of skin pigmentation, and one patient complained of superficial thrombophlebitis. Our complication rate was extremely low, perhaps due to clinician expertise, usage of tumescence, combination with phlebectomy, and the application of compression bandages and compression stockings for 6 to 8 weeks. We observed no neurologic complications. In a previous clinical study of cryosurgery, the neurologic complication rate was 0.10% [14].

Severe or fatal complications have not been reported in the treatment of varicose veins, regardless of which kinds of modalities are used. Comparisons of cost-effectiveness among therapeutic modalities remain inconclusive despite the large amount of research data that has been accumulated [15]. Therefore, no single therapeutic modality is considered a gold standard. The choice for treatment depends on the extent of varicose veins.

Cryosurgery is a good option for treating varicose veins with GSV reflux and visible trunk varicosities. In combination with phlebectomy and sclerotherapy, cryosurgery could resolve almost all types of varicose veins (from CEAP 2 to CEAP 6). Cryosurgery is more rapid and has lower rates of complications than conventional surgery, and may be less expensive than minimally invasive techniques for patients. Cryosurgery may be performed under either local or general anesthesia, and can be performed as day surgery.

CONCLUSION

Cryosurgery is feasible for the treatment of varicose veins with GSV reflux. It is less invasive than conventional stripping and less expensive for patients than endovenous laser therapy or radiofrequency ablation.

REFERENCES

- Schouten R, Mollen RM, Kuijpers HC. *A comparison between cryosurgery and conventional stripping in varicose vein surgery: perioperative features and complications.* Ann Vasc Surg 2006;20:306-11.
- Callam MJ. *Epidemiology of varicose veins.* Br J Surg 1994;81:167-73.
- Beale RJ, Gough MJ. *Treatment options for primary varicose veins: a review.* Eur J Vasc Endovasc Surg 2005;30:83-95.
- Kouri B. *Current evaluation and treatment of lower extremity varicose veins.* Am J Med 2009;122:513-5.
- Min RJ, Khilnani N, Zimmet SE. *Endovenous laser treatment of saphenous vein reflux: long-term results.* J Vasc Interv Radiol 2003;14:991-6.
- van den Bos RR, Kockaert MA, Neumann HA, Nijsten T. *Technical review of endovenous laser therapy for varicose veins.* Eur J Vasc Endovasc Surg 2008;35:88-95.
- Harris EJ Jr. *Endovascular obliteration of saphenous vein reflux: a perspective.* J Vasc Surg 2002;35:1292-4.
- Sybrandy JE, Wittens CH. *Initial experiences in endovenous treatment of saphenous vein reflux.* J Vasc Surg 2002;36:1207-12.
- Le Pivert P. *Controlled cryosurgery of varices of the lower extremities: a new therapeutic approach. Apropos of 350 cases.* Phlebologie 1987;40:123-48.
- Breuninger H. *Cryostripping of the long saphenous vein with a percutaneously guided probe.* Dermatol Surg 2001;27:545-8.
- Schouten R, Mollen RM, Kuijpers HC. *A comparison between cryosurgery and conventional stripping in varicose vein surgery: perioperative features and complications.* Ann Vasc Surg 2006;20:306-11.
- Disselhoff BC, Buskens E, Kelder JC, der Kinderen DJ, Moll FL. *Randomised comparison of costs and cost-effectiveness of cryostripping and endovenous laser ablation for varicose veins: 2-year results.* Eur J Vasc Endovasc Surg 2009;37:357-63.
- Klem TM, Wittens CH. *Cryoperforator surgery: a new treatment of incompetent perforating veins.* Vasc Endovascular Surg 2008;42:239-42.
- Shim YK, Soh DM. *Cryosurgical treatment of varicose vein in 1,157 cases.* J Korean Soc Phlebol 2011;10:1-10.
- Leopardi D, Hoggan BL, Fitridge RA, Woodruff PW, Maddern GJ. *Systematic review of treatments for varicose veins.* Ann Vasc Surg 2009;23:264-76.