

Original Article

Enhancement Pattern of the Normal Facial Nerve on Three - Dimensional (3D) - Fluid Attenuated Inversion Recovery (FLAIR) Sequence at 3.0 T MR Units

Dongho Hyun¹, Hyun Kyung Lim¹, Jee Won Park¹, Jong Lim Kim¹, Ha Young Lee¹, Soonchan Park¹, Joong Ho Ahn², Jung Hwan Baek¹, Choong Gon Choi¹, Jeong Hyun Lee¹

¹Department of Radiology and Research Institute of Radiology, University of Ulsan College of Medicine, Asan Medical Center

²Department of Otolaryngology (J.H.A.), University of Ulsan College of Medicine, Asan Medical Center

Purpose : To compare the enhancement pattern of normal facial nerves on 3D-FLAIR and 3D-T1-FFE-F) sequences at 3.0 T MR units.

Materials and Methods: We assessed 20 consecutive subjects without a history of facial nerve abnormalities who underwent temporal bone MRI with contrast enhancement between January 2008 and March 2009. Two neuroradiologists independently reviewed pre-/post-enhanced 3D-T1-FFE-FS and 3D-FLAIR images respectively with 2-week interval to assess the enhancement of normal facial nerves divided into five anatomical segments. The degree of enhancement in each segment was graded as none, mild or strong, and the results of 3D-FLAIR and 3D-T1-FFE-FS image sets were compared.

Results: On 3D-FLAIR images, one of the two reviewers observed mild enhancement of the genu segment in two (10%) subjects. On 3D-T1-FFE-FS images, at least one segment of the facial nerve was enhanced in 13 (65%) subjects. At least one reviewer found that 17 of the 100 segments showed enhancement on 3D-T1-FFE-FS images, with the mastoid segment being the most commonly enhanced. Interobserver agreement on 3D-T1-FFE-FS images was good for enhancement of the normal facial nerve ($\kappa = 0.589$).

Conclusion: In contrast to 3D-T1-FFE-FS, normal facial nerve segments rarely showed enhancement on 3D-FLAIR images.

Index words : Temporal bone · Facial nerve · 3D-FLAIR · Enhancement

INTRODUCTION

MR imaging of patients with facial neuritis is not usually indicated except in patients with facial palsy with atypical manifestations and those with intractable

palsy despite therapy. In most patients, the diagnosis of facial neuritis is clinically evident and is confirmed by EPS. EPS can also provide prognostic information on outcomes in patients with acute facial paralysis. The major disadvantage of EPS is its inability to detect diagnostic abnormalities of the nerve distal to the stylomastoid foramen within 1 week of symptom onset.

Although the diagnostic utility of MRI in patients with facial neuritis has been studied over the past 20 years, its results have been largely disappointing (1-5). For example, Gd-DTPA-enhanced T1-weighted spin echo or T1-weighted fast field echo (T1-FFE) MRI analyses have shown significant limitations in diagnos-

• Received; November 7, 2011 • Revised; December 22, 2011

• Accepted; December 27, 2011

Corresponding author : Jeong Hyun Lee, M.D., Department of Radiology and Research Institute of Radiology, Asan Medical Center, 86 Asanbyeongwon-gil, Poongnap-2dong, Songpa-gu, Seoul 138-736, Korea.

Tel. 82-2-3010-4352, Fax. 82-2-476-4719

E-mail : jeonghlee@hanmir.com

ing and evaluating prognosis in patients with facial neuritis. For example, the geniculate ganglion, tympanic or mastoid segment of the normal facial nerve may be significantly enhanced in up to 76% of patients due to the distribution of arteriovenous plexus along this facial nerve (6, 7). This, in turn, may block evaluation of the relatively minor pathologic enhancement of the nerves resulting from breakdown of the blood nerve barrier on conventional MR images (6, 7). Thus, compared with EPS, MRI plays a limited role in the diagnosis and evaluation of patients with facial neuritis (8).

Recently, a new MR sequence, three - dimensional (3D) fluid attenuated inversion recovery (FLAIR), has been used to image temporal bone pathologies. In contrast to conventional MRI sequences, 3D-FLAIR sequences have been reported to be useful in diagnosing mumps deafness and sudden sensorineural hearing loss and in predicting the prognosis of patients with sudden sensorineural hearing loss (9–11). FLAIR imaging is highly sensitive to subtle changes in longitudinal magnetization in the fluid space, which, in contrast to T1-weighted images, decrease as the concentration of contrast agent increases (12, 13). 3D-FLAIR sequences can also suppress signal from the fluid at a velocity exceeding 1.0 cm/s (14). We hypothesized that facial neuritis may be more accurately imaged on 3D-FLAIR images than on T1-FFE images without normal enhancement of the arteriovenous plexus along the facial nerve. We therefore, evaluated the pattern of enhancement of the normal facial nerve on 3D-FLAIR sequence at 3.0 T MRI, to provide baseline data for future studies re-evaluating the

clinical utility of MRI for patients with facial neuritis.

MATERIALS AND METHODS

Patients

We evaluated 20 consecutive subjects with no history of facial nerve abnormalities, who underwent temporal bone MRI with contrast enhancement between January 2008 and March 2009. The MRI images analyzed were those from the contralateral normal side in all subjects. In all patients, there was no symptoms related facial nerve abnormality according to medical records. Our study was approved by the institutional review board of our hospital, and informed consent was waived due to the retrospective of this study.

MR imaging

All MR scans were performed using a 3.0-T MR unit (Intera Achieva, Philips Medical Systems, Best, the Netherlands) and an 8-element phased array sensitivity-encoding (SENSE) head coil. MR images analyzed were pre-, and post-contrast-3D-FLAIR sequences and 3D-T1-FFE-FS sequences using Gd-DOTA (0.1 mmol/kg body weight; Dotarem; Guerbet, Paris, France). The mean time from contrast administration to post-contrast 3D-FLAIR imaging was 7 min.

The parameters for 3D-FLAIR were: TR, 8,000 ms; TE, 268 ms; TI, 2,400 ms; ET L, 80; modulation of flip angle for refocusing pulses; section thickness, 0.6 mm; over contiguous slices; 60 sections; FOV, 18 × 18 cm; matrix size, 512 × 512; NEX, 1; and acquisition time,

Table 1. Enhancement of the normal facial nerve on 3D-FLAIR and 3D-T1-FFE-FS sequences, as determined by each of two reviewers

	Segment (%)				
	Canalicular	Labyrinthine	Genu	Tympanic	Mastoid
3D-FLAIR					
Reviewer 1	0	0	0	0	0
Reviewer 2	0	0	2 (10)	0	0
3D-T1-FFE-FS					
Reviewer 1	0	0	2* (10)5 (1)	9* (45)	
Reviewer 2	0	0	4 (20)0	9 (45)	

Note.— Numbers in parentheses indicate the number of subjects.

*All the patients positively read by the reviewer 1 were also marked as positive by the reviewer 2.

6 minutes 6 seconds. The parameters for 3D-T1-FFE-FS were: TR, 25 ms, TE, 4.6 ms; flip angle, 30°; ETL, 319; FOV, 18 × 18 cm; matrix size, 512 × 512; section thickness, 0.6 mm; over contiguous slices; 60 sections; NEX, 1; and acquisition time, 3 minutes 57 seconds.

Image analysis

Each facial nerve was divided into five segments; canalicular, labyrinthine, genu, tympanic and mastoid segments. The pattern of enhancement was visually assessed by two neuro-radiologists, one with 5 years and one with 13 years of experience, who independently reviewed pre-/post-enhanced 3D-T1-FFE-FS sequences, and, 2 weeks later, evaluated pre-/post-

enhanced 3D-FLAIR sequences. The two image sets for each patient were randomly interpreted during different sessions. The degree of enhancement in each segment was estimated using a 3-point rating scale, with grade 0 indicating no enhancement; grade 1 indicating mild enhancement, but only when compared with the corresponding precontrast scan; and grade 2 indicating strong enhancement, when enhancement was obvious without comparison.

Statistical analysis

For both 3D-FLAIR and 3D-T1-FFE-FS sequences, we evaluated the degree of enhancement for each segment of the facial nerve. We also calculated interobserver agreement between two neuroradiolo-

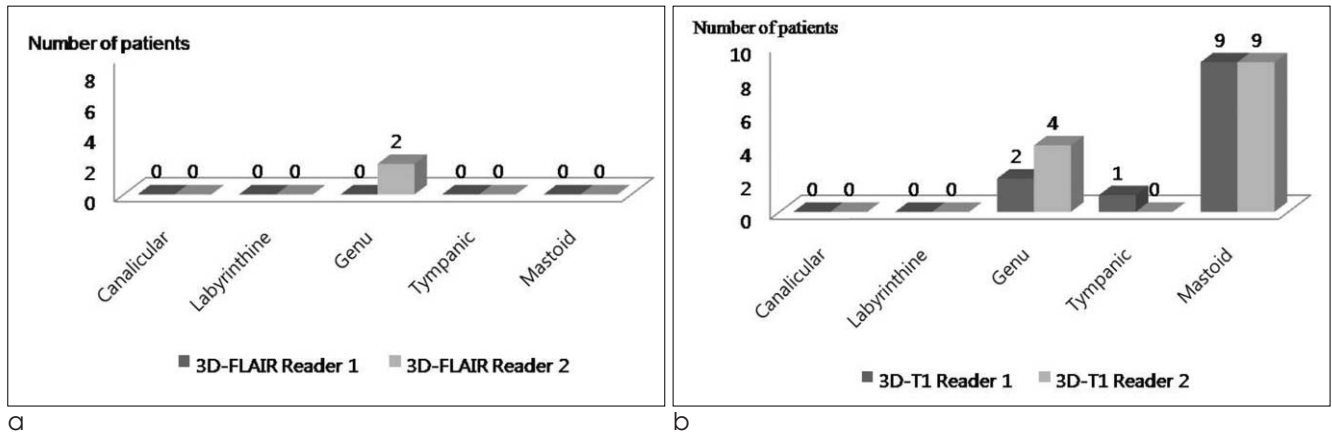


Fig. 1. Segmental distribution of contrast enhancement of the facial nerve on 3D-FLAIR and 3D-T1-FFE-FS according to the two reviewers
 a. 3D-FLAIR MRI
 b. 3D-T1-FFE-FS MRI

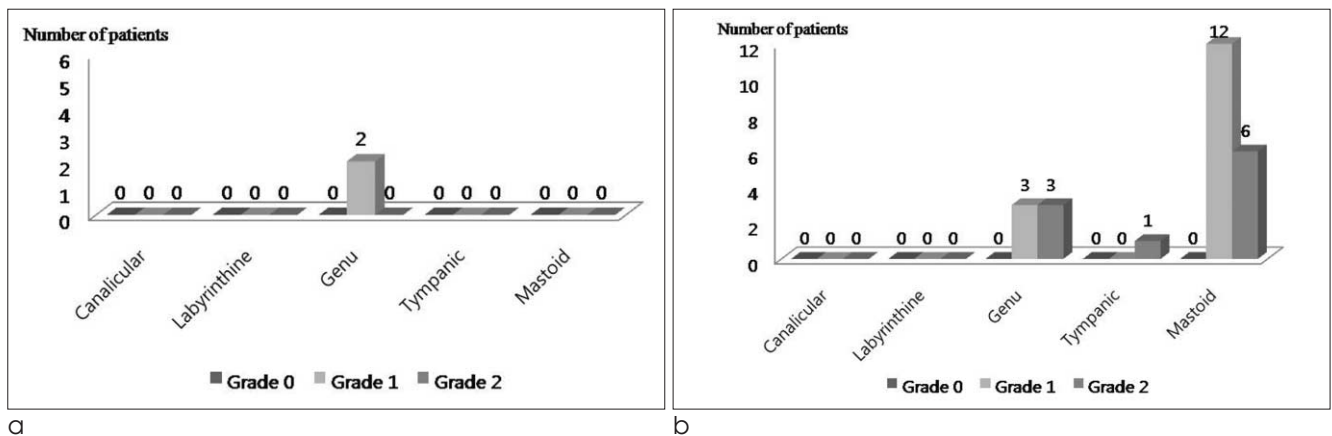


Fig. 2. Segmental distribution of the degree of enhancement of the normal facial nerve on 3D-FLAIR and 3D-T1-FFE-FS images
 a. 3D-FLAIR MRI
 b. 3D-T1-FFE-FS MRI

gists. All statistical analyses were performed using Medcalc for Windows (version 11.2.1; MedCalc Software; Mariakerke, Belgium).

RESULTS

There were 5 men and 15 women with a mean age of 50 years, ranging from 8 to 71. Twelve patients were diagnosed with unilateral sudden sensorineural hearing loss and 8 with acoustic neuroma.

On 3D-FLAIR sequences, only two subjects showed contrast enhancement, showing a mild (grade 1) degree of enhancement on the genu segment, as assessed by at least one of the reviewers. In contrast, 13 (65%) of 20 subjects showed enhancement of at least one segment on 3D-T1-FFE-FS images (Table 1).

Of the 100 segments examined, 17 were positive on 3D-T1-FFE-FS images, as determined by at least 1

reviewer, with the mastoid segment being the most common site of enhancement (Fig. 1). The two reviewers differed on the presence of enhancement in nine segments and on the degree in three segments. Distribution of the degree of enhancement in all 17 segments is shown in Fig. 2. Although the interobserver agreement on the occurrence of enhancement of normal facial nerve segments on 3D-T1-FFE-FS images was good ($\kappa = 0.589$), the interobserver agreement on the degree of enhancement was only moderate ($\kappa = 0.459$). An example is shown in Fig. 3.

DISCUSSION

On Gd-DTPA-enhanced T1-weighted MRI, the geniculate ganglion, the greater superficial petrosal nerve, and the proximal tympanic and mastoid segments of the normal facial nerve may be enhanced

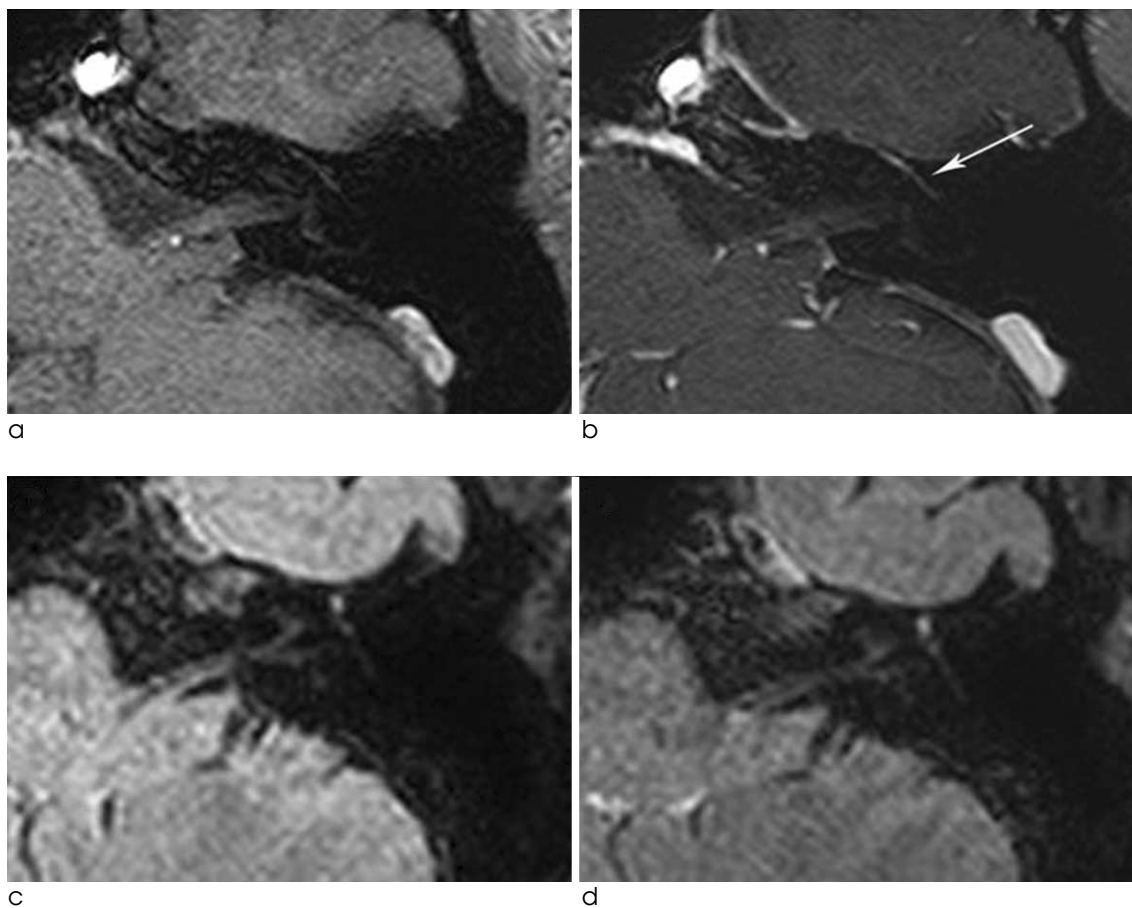


Fig. 3. Example of a normal facial nerve on 3D-FLAIR and 3D-T1-FFE-FS images before and after administration of a contrast agent. Axial MR images of the left temporal bone on 3D-T1-FFE-FS (a, b) and 3D-FLAIR (c, d) images. On 3D-T1-FFE-FS, the tympanic segment of the left facial nerve was mildly enhanced (arrow on b) compared with that on the pre-contrast image (a). However, there was no demonstrable enhancement on the corresponding pre- (c) and post- (d) contrast images of the 3D-FLAIR sequence.

due to the flux of contrast material in the lush circumneural arteriovenous plexus. In contrast, the normal cisternal, intracanalicular and labyrinthine segments are not enhanced. Therefore, on Gd-DTPA-enhanced T1-weighted MRI, it may be difficult to determine whether enhancement of the facial nerve is indicative of disease (6, 15).

Our results indicate that 3D-FLAIR sequences may have advantages over 3D-T1-FFE-FS sequences in evaluating the actual enhancement of the normal facial nerve. While 1 of 2 reviewers observed only mild enhancement of the genu segment in 2 patients on 3D-FLAIR sequences, at least 1 reviewer observed enhancement of at least one segment of the facial nerve on 3D-T1-FFE-FS sequences in 13 of 20 (65%) subjects. Segments enhanced included the genu, the tympanic and the mastoid, corresponding to previous results showing that at least one segment of the normal facial nerve is enhanced in 76% of patients on post-contrast 2D - or 3D - T1 - weighted sequences (6, 15-17).

Our results supported by the characteristics of the 3D-FLAIR sequence. This sequence is not only more sensitive to lower gadolinium concentrations but is less sensitive to high gadolinium concentrations than T1-weighted sequences. Thus, regions with higher concentrations of gadolinium do not appear enhanced because the signal-reducing T2 effect will obscure the signal-enhancing T1 effect (18). Furthermore, this sensitivity of 3D-FLAIR sequences to gadolinium contrast is abruptly reduced as flow velocity above is increased above 1.0 cm/sec (14).

Due to these characteristics of 3D-FLAIR sequences despite there is no known report about the gadolinium concentration or flow velocity of the arteriovenous plexus of the human facial nerve, we can assume that the prominent contrast enhancement of the lush circumneural arteriovenous plexus surrounding the normal facial nerve, visible on post-contrast T1-weighted images, was no longer visible on 3D-FLAIR sequences. Therefore, in the absence of normal enhancement of the arteriovenous plexus along the facial nerve, facial neuritis may be more accurately imaged on 3D-FLAIR than on T1-FFE images. This, however, requires validation in future studies.

Our study had several limitations. First, the interpretation of MR images may have been biased because the reviewers knew prior to evaluation that these facial

nerves were normal. This may have resulted in underestimation of the normal enhancement of the facial nerve on MR images. To minimize the interpretation bias, we strictly defined the grade of enhancement on MR images and evaluated interobserver agreement to determine the consistency of our interpretation of 3D-T1-FFE-FS images. However, interobserver agreement could not be estimated for 3D-FLAIR images because too few subjects showed positive results. Therefore, the results of our preliminary study should be validated by further evaluations, including both normal controls and patients with facial neuritis. Second limitation of our study was that the number of normal subjects was relatively small, and the age and sex were not corrected statistically. However, previous studies of the enhancement pattern of facial nerves on MRI had included similar numbers of subjects (6). Moreover the number of subjects analyzed (20) seems to be sufficient for statistical analysis. Finally, twelve patients enrolled in this study had a history of sudden sensorineural hearing loss, of which etiologies might be viral or autoimmune process. However, the possibility of subclinical involvement of the facial nerve might be extremely low because we evaluated the facial nerves located in the contralateral asymptomatic side of the temporal bones.

CONCLUSION

Our results indicate that 3D-FLAIR sequences could substantially eliminate the normal enhancement of the arteriovenous plexus surrounding the normal facial nerve that has been observed with previous MR sequences such as post-contrast 2D- and 3D-T1-weighted images. The use of contrast-enhanced 3D-FLAIR sequences, we may increase the diagnostic specificity of MRI for facial neuritis.

References

1. Kress B, Griesbeck F, Stippich C, Bahren W, Sartor K. Bell palsy: quantitative analysis of MR imaging data as a method of predicting outcome. *Radiology* 2004;230:504-509
2. Sugiura M, Naganawa S, Nakata S, Kojima S, Nakashima T. 3D-FLAIR MRI findings in a patient with Ramsay Hunt syndrome. *Acta Otolaryngol* 2007;127:547-549
3. Song MH, Kim J, Jeon JH, et al. Clinical significance of quantitative analysis of facial nerve enhancement on MRI in Bell's palsy. *Acta Otolaryngol* 2008;128:1259-1265

4. Tien R, Dillon WP, Jackler RK. Contrast-enhanced MR imaging of the facial nerve in 11 patients with Bell's palsy. AJR Am J Roentgenol 1990;155:573-579
5. Brandle P, Satorretti-Schefer S, Bohmer A, Wichmann W, Fisch U. Correlation of MRI, clinical, and electroneuronographic findings in acute facial nerve palsy. Am J Otol 1996;17:154-161
6. Hong HS, Yi BH, Cha JG, et al. Enhancement pattern of the normal facial nerve at 3.0 T temporal MRI. Br J Radiol 2010;83: 118-121
7. Kinoshita T, Ishii K, Okitsu T, Okudera T, Ogawa T. Facial nerve palsy: evaluation by contrast-enhanced MR imaging. Clin Radiol 2001;56:926-932
8. Yetiser S, Kazkayas M, Altinok D, Karadeniz Y. Magnetic resonance imaging of the intratemporal facial nerve in idiopathic peripheral facial palsy. Clin Imaging 2003;27:77-81
9. Yoshida T, Sugiura M, Naganawa S, Teranishi M, Nakata S, Nakashima T. Three-dimensional fluid-attenuated inversion recovery magnetic resonance imaging findings and prognosis in sudden sensorineural hearing loss. Laryngoscope 2008;118: 1433-1437
10. Sugiura M, Naganawa S, Sato E, Nakashima T. Visualization of a high protein concentration in the cochlea of a patient with a large endolymphatic duct and sac, using three-dimensional fluid-attenuated inversion recovery magnetic resonance imaging. J Laryngol Otol 2006;120:1084-1086
11. Otake H, Sugiura M, Naganawa S, Nakashima T. 3D-FLAIR magnetic resonance imaging in the evaluation of mumps deafness. Int J Pediatr Otorhinolaryngol 2006;70:2115-2117
12. Deliganis AV, Fisher DJ, Lam AM, Maravilla KR. Cerebrospinal fluid signal intensity increase on FLAIR MR images in patients under general anesthesia: the role of supplemental O2. Radiology 2001;218:152-156
13. Maeda M, Tsuchida C. "Ivy sign" on fluid-attenuated inversion-recovery images in childhood moyamoya disease. AJNR Am J Neuroradiol 1999;20:1836-1838
14. Fukuoka H, Hirai T, Okuda T, et al. Comparison of the added value of contrast-enhanced 3D fluid-attenuated inversion recovery and magnetization-prepared rapid acquisition of gradient echo sequences in relation to conventional postcontrast T1-weighted images for the evaluation of leptomeningeal diseases at 3T. AJNR Am J Neuroradiol 2010;31:868-873
15. Gebarski SS, Telian SA, Niparko JK. Enhancement along the normal facial nerve in the facial canal: MR imaging and anatomic correlation. Radiology 1992;183:391-394
16. Kress BP, Griesbeck F, Efinger K, et al. Bell's palsy: what is the prognostic value of measurements of signal intensity increases with contrast enhancement on MRI? Neuroradiology 2002;44:428-433
17. Kumar A, Mafee MF, Mason T. Value of imaging in disorders of the facial nerve. Top Magn Reson Imaging 2000;11:38-51
18. Mathews VP, Caldemeyer KS, Lowe MJ, Greenspan SL, Weber DM, Ulmer JL. Brain: gadolinium-enhanced fast fluid-attenuated inversion-recovery MR imaging. Radiology 1999;211:257-263

3.0T 자기공명영상기기에서 시행한 3D-FLAIR 영상에서의 정상 안면신경의 조영증강 양상

¹울산대학교 의과대학 서울아산병원 영상의학과학교실

²울산대학교 의과대학 서울아산병원 이비인후과학교실

현동호¹ · 임현경¹ · 박지원² · 김종림¹ · 이하영¹ · 박순찬¹ · 안중호² · 백정환¹ · 최충곤¹ · 이정현¹

목적: 3-T 자기공명영상장치에서 시행한 3D-FLAIR 및 3D-T1-FFE-FS영상에서의 정상안면신경의 조영증강 양상의 비교가 그 목적이다.

대상과 방법: 측두골 자기공명영상을 촬영한 환자 중 안면신경이상의 과거력이 없는 20명의 환자를 대상으로 하였다. 두 명의 영상의학전문의가 정상안면신경의 조영증강을 평가하기 위해 조영증강 전후의 3D-T1-FFE-FS영상과 3D-FLAIR영상을 2주 간격으로 독립적으로 분석하였다. 안면신경은 5개의 분절로 나누었고 조영증강의 정도는 없거나 약하게 혹은 강하게 되는 경우로 나누어 분석하였다.

결과: 3D-FLAIR영상에서 한 명의 평가자가 두 예의 안면신경 슬부에 약한 조영증강이 있다고 보았다. 3D-T1-FFE-FS영상에서는 13예의 안면신경에서 최소 한 분절 이상 조영증강이 있다고 하였고, 최소 한 명의 평가자가 안면신경의 총 100개 분절 중 17개의 분절에서 조영증강이 있다고 분석하였으며, 유양분절의 빈도가 가장 높았다. 3D-T1-FFE-FS영상에서 정상안면신경의 조영증강에 대한 평가자간의 일치도는 κ 값 0.589로 우수하였다.

결론: 3D-T1-FFE-FS영상과 달리 3D-FLAIR영상에서 정상안면신경은 거의 조영증강되지 않는다.