

Acute Type II Aortic Dissection with Severe Aortic Regurgitation and Chronic Descending Aortic Dissection in Pregnant Patient with Marfan Syndrome

Seok-Soo Lee, M.D., Tae-Eun Jung, M.D., Dong Hyup Lee, M.D.

Aortic dilatation and dissection are severe complications during pregnancy that can be fatal to both the mother and the fetus. The risks of these complications are especially high in pregnant patients with Marfan syndrome; however, incidents of descending aortic dissection are very rare. This case report involves a successful Bentall procedure for and recovery from a rare aortic dissection in a pregnant Marfan patient who developed acute type II aortic dissection with severe aortic regurgitation and chronic descending aortic dissection immediately after Cesarean section. Regular follow-up will be needed to monitor the descending aortic dissection.

Key words: 1. Aortic dissection
2. Pregnancy
3. Aortic valve
4. Surgery

CASE REPORT

A 37-year-old female patient with no previous medical history underwent a Cesarean section early in the morning at a local medical center, and then experienced chest pain and dyspnea. She was referred to the Yeungnam University Hospital when these symptoms worsened and when a systolic blood pressure of 60 mmHg and a heart rate of 40 beats/min were recorded. She had undergone a normal pregnancy two years prior and experienced short breath during her most recent pregnancy, but she thought nothing of it. On arrival, besides mild fever and chest discomfort, her vital signs were stable. A chest computed tomography (CT) was performed to evaluate the dyspnea and revealed sinus of Valsalva dilatation at 78 mm in diameter and descending aorta dissection from

the left subclavian artery to the renal artery, but there was no dissection of the aortic arch (Fig. 1). On physical examination, a grade IV/VI diastolic murmur was heard, and rales in both lung fields were also heard. A transthoracic echocardiogram revealed severe aortic regurgitation (grade IV), dilated sinus of Valsalva (74 mm), and left ventricular enlargement; however, left ventricular systolic function was maintained with an ejection fraction of 56%.

Conservative treatment of the descending aorta and the Bentall procedure for the ascending aorta were planned because the descending aorta was measured at 4 cm in diameter, both the true and false lumen blood flows were stable, malperfusion symptoms were absent, and the blood pressure in both lower extremities was stable. Surgery was performed through a median sternotomy. Above the aneurysm of the as-

Department of Thoracic and Cardiovascular Surgery, Yeungnam University College of Medicine

Received: June 26, 2012, Revised: August 14, 2012, Accepted: August 16, 2012

Corresponding author: Dong Hyup Lee, Department of Thoracic and Cardiovascular Surgery, Yeungnam University College of Medicine, 170 Hyeonchung-ro, Nam-gu, Daegu 705-717, Korea
(Tel) 82-53-620-3883 (Fax) 82-53-626-8660 (E-mail) dhlee@med.yu.ac.kr

© The Korean Society for Thoracic and Cardiovascular Surgery. 2012. All right reserved.

© This is an open access article distributed under the terms of the Creative Commons Attribution Non-Commercial License (<http://creativecommons.org/licenses/by-nc/3.0>) which permits unrestricted non-commercial use, distribution, and reproduction in any medium, provided the original work is properly cited.

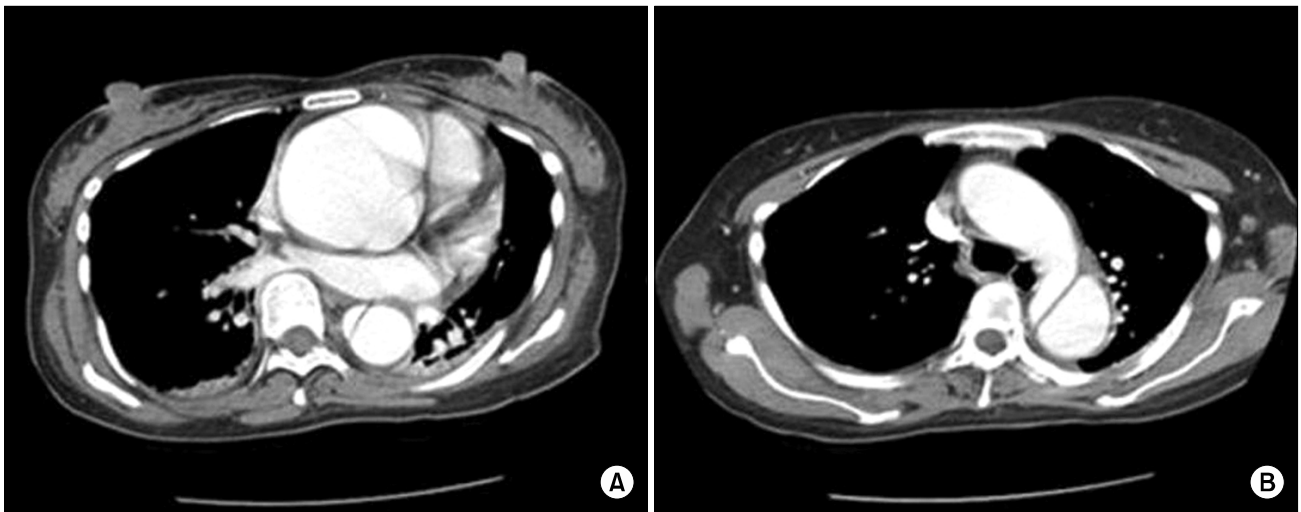


Fig. 1. Computed tomography. (A) Huge dilatation of the aortic root with descending aortic dissection. (B) Normal aortic arch.

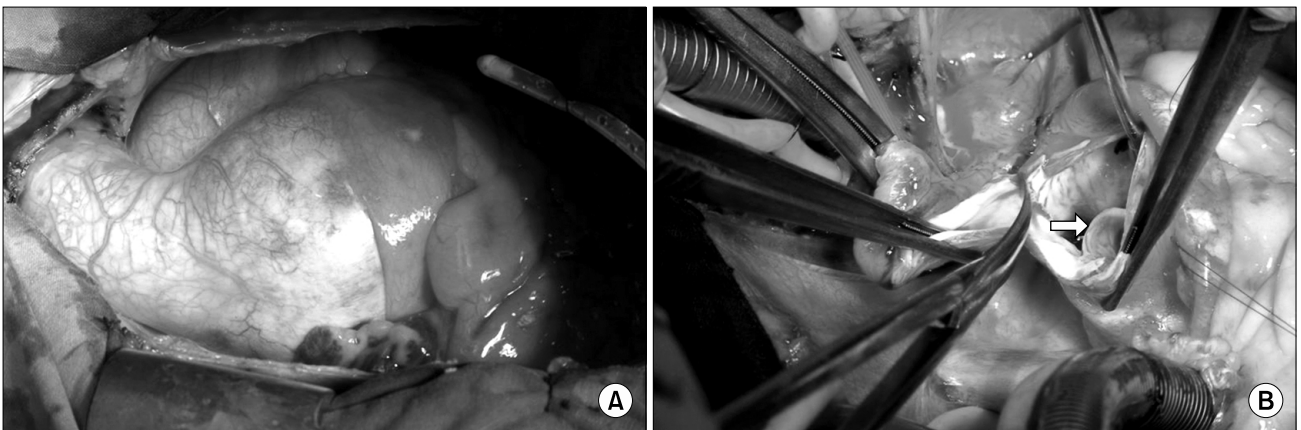


Fig. 2. Intraoperative gross findings. (A) A huge aortic ectasia was noted, aortic cross-clamping was performed, and the aneurysm sac was opened. Normal tissue was found in the distal area of the ascending aorta, and then aortotomy was performed. (B) A dissection flap (arrow) was noted in the non-coronary cusp area.

ending aorta, there was a normal aorta where aortic cross-clamping was possible; therefore, arterial cannulation was performed on the proximal aortic arch, and venous cannulation was performed on the right atrium. After aortic cross-clamping and aortotomy, the dissection flap at the aortic root was observed, and aortic dissection, which is thought to cause huge aneurysms, had occurred (Fig. 2). A composite graft (SJM valved graft conduit 25 mm; St. Jude Medical Inc., St. Paul, MN, USA) was used for the operation. With no total circulatory arrest, the total pump time was 208 minutes and the aortic cross clamp time was 160 minutes. After

30 hours in the intensive care unit, the patient was weaned from the ventilator and transferred to the general ward. An echocardiogram on postoperative day 20 revealed a normal graft and valve function, and the left ventricular end-diastolic volume decreased from 68 to 48 mm. The patient was followed up on postoperative day 34 with 3D CT, which revealed a well-maintained surgical region of the ascending aorta and a stable lesion on the descending aorta (Fig. 3). The patient has been monitored since she was discharged.

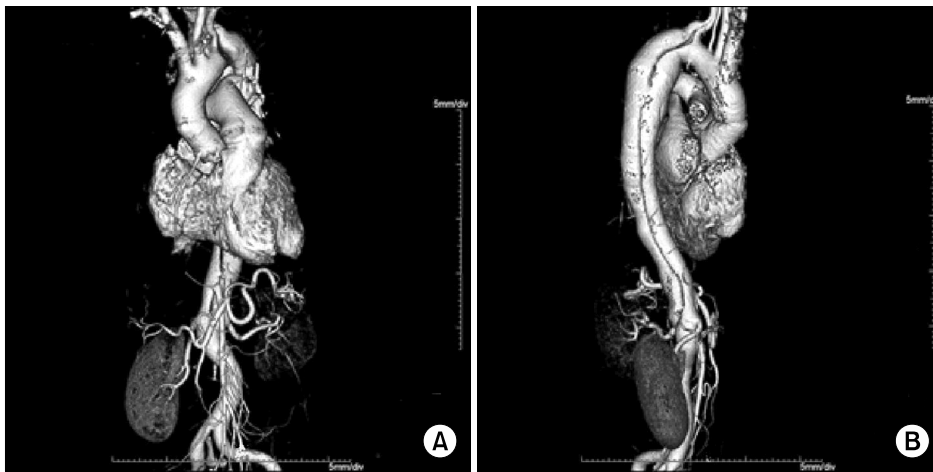


Fig. 3. Follow-up 3-dimensional computed tomography angiogram. (A) Normal ascending aorta (after the Bentall operation). (B) No interval change of the descending aortic dissection.

DISCUSSION

We experienced an unusual aortic dissection in a pregnant patient with Marfan syndrome who developed acute type II aortic dissection with severe aortic regurgitation and chronic descending aortic dissection immediately after Cesarean section. Aortic dissection during pregnancy is rare, but it can be fatal to both the mother and the fetus if not treated properly [1,2]. A pregnancy can be made because of the increase in heart rate, stroke volume, cardiac output, and end-diastolic dimensions during pregnancy [1-3]. These changes and aortic dissection occur most often during the third trimester [4,5]. During pregnancy, the uterus compresses both the aorta and iliac artery, causing an increase in the vessel outflow resistance [1]. An increased ejection fraction caused by an intimal injury of the aorta causes aortic dissection [1,5]. Changes in hormone levels during pregnancy are related to the reduction of acid mucopolysaccharides and the loss of normal corrugation of elastic fiber, which cause reticulin fiber fragmentation [1,2]. Moreover, Marfan syndrome is the primary factor of aortic dissection in pregnant females. Marfan patients carry the risk of dissection at any time before or after labor [1]. It is known that even Marfan patients with a normal aortic root diameter still have about a 1% chance of aortic dissection [1,6]. Aortic root dilatation or dissection occurs more frequently with connective tissue disorder. Also, with the added burden on the aortic wall, aortic dissection occurs more frequently in pregnant Marfan patients [1,2]. A woman with Marfan syndrome, who has an aortic root diameter greater

than 4 cm, has a high risk of aortic dissection during pregnancy. Therefore, conception is not advised if the root diameter is greater than 4.5 cm [6,7]. In this case, the patient was diagnosed with Marfan syndrome due to an abnormal musculoskeletal system of 175 cm in height, a 'thumb sign,' scoliosis, and dilatation of the proximal aorta. The patient had rare Stanford type B aortic dissection with absolutely no lesion on the aortic arch [2], which was unusual because most reported cases have been of type A dissection [1-3]. The dissection occurred right after Cesarean section. And during observing the lesion on the descending aortic dissection, conservative treatment was deemed possible. So a Bentall on the descending aortic dissection, conservative treatment was deemed possible and a Bentall procedure was performed to fix the markedly dilated proximal aorta and severe aortic regurgitation. All pregnant Marfan patients need an echocardiogram, and if enlargement of the aortic root is discovered, periodic follow-up echocardiography is also needed along with the testing of fetal development. If aortic dissection occurs before 30 weeks' gestation, then an immediate aortic root repair operation is needed. However, if it occurs after 30 weeks' gestation, Cesarean section has to be performed cautiously just before heart surgery [2]. As shown in this case, where aortic dissection occurred right after giving birth, dissection can still occur for up to 3 months; therefore, regular echocardiography is necessary for 6 months after giving birth [8].

In conclusion, a pregnant patient with Marfan syndrome requires accurate diagnosis from a regular heart examination,

and if aortic dissection occurs, an appropriate surgical method should be performed to save both the mother and the fetus. Occurrence of an unusual aortic dissection right after Cesarean section was treated using the Bentall procedure, and the progress of the descending aortic dissection is being monitored with periodic follow-up examinations along with medication.

CONFLICT OF INTEREST

No potential conflict of interest relevant to this article was reported.

REFERENCES

1. Vranes M, Velinovic M, Kovacevic-Kostic N, Savic D, Nikolic D, Karan R. *Pregnancy-related aortic aneurysm and dissection in patients with Marfan's syndrome: medical and surgical management during pregnancy and after delivery.* Medicina (Kaunas) 2011;47:604-6.
2. Aziz F, Penupolu S, Alok A, Doddi S, Abed M. *Peripartum acute aortic dissection: a case report & review of literature.* J Thorac Dis 2011;3:65-7.
3. Houston L, Tuuli M, Macones G. *Marfan syndrome and aortic dissection in pregnancy.* Obstet Gynecol 2011;117:956-60.
4. Guo C, Xu D, Wang C. *Successful treatment for acute aortic dissection in pregnancy: Bentall procedure concomitant with cesarean section.* J Cardiothorac Surg 2011;6:139.
5. McDermott CD, Sermer M, Siu SC, David TE, Colman JM. *Aortic dissection complicating pregnancy following prophylactic aortic root replacement in a woman with Marfan syndrome.* Int J Cardiol 2007;120:427-30.
6. European Society of Gynecology; Association for European Paediatric Cardiology; German Society for Gender Medicine, et al. *ESC guidelines on the management of cardiovascular diseases during pregnancy: the Task Force on the Management of Cardiovascular Diseases during Pregnancy of the European Society of Cardiology (ESC).* Eur Heart J 2011;32:3147-97.
7. Hall ME, George EM, Granger JP. *The heart during pregnancy.* Rev Esp Cardiol 2011;64:1045-50.
8. Rossiter JP, Repke JT, Morales AJ, Murphy EA, Pyeritz RE. *A prospective longitudinal evaluation of pregnancy in the Marfan syndrome.* Am J Obstet Gynecol 1995;173:1599-606.