

Brace Compression for Treatment of Pectus Carinatum

Joonho Jung, M.D., Sang Ho Chung, R.N., Jin Kyoung Cho, R.N.,
Soo-Jin Park, M.D., Ho Choi, M.D., Sungsoo Lee, M.D.

Background: Surgery has been the classical treatment of pectus carinatum (PC), though compressive orthotic braces have shown successful results in recent years. We propose a non-operative approach using a lightweight, patient-controlled dynamic chest-bracing device. **Materials and Methods:** Eighteen patients with PC were treated between July 2008 and June 2009. The treatment involved fitting of the brace, which was worn for at least 20 hours per day for 6 months. Their degree of satisfaction (1, no correction; 4, remarkable correction) was measured at 12 months after the initiation of the treatment. **Results:** Thirteen (72.2%) patients completed the treatment (mean time, 4.9±1.4 months). In patients who completed the treatment, the mean overall satisfaction score was 3.73±0.39. The mean satisfaction score was 4, and there was no recurrence of pectus carinatum in patients who underwent the treatment for at least 6 months. Minimal recurrence of pectus carinatum after removal of the compressive brace occurred in 5 (38.5%) patients who stopped wearing the compressive brace at 4 months. **Conclusion:** Compressive bracing results in a significant improvement in PC appearance in patients with an immature skeleton. However, patient compliance and diligent follow-up appear to be paramount for the success of this method of treatment. We currently offer this approach as a first-line treatment for PC.

Key words: 1. Chest wall
2. Device
3. Pectus carinatum

INTRODUCTION

Pectus carinatum is a deformity that is characterized by the protrusion of the anterior chest wall caused by overgrowth of the costal cartilage. The incidence is not well-known, but it is less frequent than pectus excavatum. Males are 4 times more susceptible to the deformity than females, and it is sometimes related to connective tissue diseases such as Marfan syndrome and scoliosis [1]. There are two different types of pectus carinatum. One is the chondrogladiolar type, in which the gladiolus and inferior costal cartilage protrude along the most

prominent aspect of the sternum. The other is the chondromanubrial type, in which the manubrium and superior costal cartilage protrude. Most of the cases are chondrogladiolar types, and sometimes they may show rotational deformity due to asymmetric growth [2]. In some rare cases, pectus carinatum may cause an increase in residual volume and exercise intolerance. Most of such patients, however, remain asymptomatic, because derangement of the cardiopulmonary function from external compression is minimal, unlike in patients with pectus excavatum [3]. Instead, the majority of the patients complain of the cosmetic problem, which is not easi-

Department of Thoracic and Cardiovascular Surgery, Ajou University School of Medicine

Received: June 11, 2012, Revised: August 9, 2012, Accepted: August 16, 2012

Corresponding author: Sungsoo Lee, Department of Thoracic and Cardiovascular Surgery, Ajou University School of Medicine, 206 World cup-ro, Yeongtong-gu, Suwon 443-721, Korea
(Tel) 82-31-219-5210 (Fax) 82-31-219-5215 (E-mail) chestlee@ajou.ac.kr

© The Korean Society for Thoracic and Cardiovascular Surgery. 2012. All rights reserved.

© This is an open access article distributed under the terms of the Creative Commons Attribution Non-Commercial License (<http://creativecommons.org/licenses/by-nc/3.0>) which permits unrestricted non-commercial use, distribution, and reproduction in any medium, provided the original work is properly cited.



Fig. 1. This photograph shows a compression treatment brace designed by our medical team. It is light and self-adjustable.

ly concealed with clothes. This issue tends to worsen as the deformity develops during puberty when growth accelerates [1-4].

During the past 50 years, surgery has been at the center of pectus carinatum treatment. The procedure involves the removal of abnormal costal cartilage and sternal osteotomy, commonly known as the modified Ravitch procedure. Recently, however, sternal compression, using a Nuss bar or the modified Nuss procedure is also being widely performed [5]. Scarring and postoperative pain are inevitable when such modalities are applied, and in rare cases, patients may experience surgical complications [5-7].

Correction of pectus carinatum with an external compression brace currently has a high profile, and favorable results have been reported [1-4,8]. In this article, the authors report on the outcomes of pectus carinatum patients treated conservatively with compression braces.

MATERIALS AND METHODS

Eighteen patients with pectus carinatum, who were treated at Ajou University Hospital from July 2008 to June 2009,

were included in this study. The patients with Marfan or Poland syndrome and those who presented with complex carinatum or excavatum malformations were excluded from this study. All of the patients included in the study were treated with a compression device. In the outpatient clinic, flexibility of the chest wall was evaluated with a manual compression test. Through collaboration with a certified orthotist, we designed a custom-fitted chest compression brace (Fig. 1) that is easily concealed under clothing (Fig. 2D). Two light aluminum bars were positioned on the anterior and the posterior chest. An adjustable buckle and strap ratchet kit was attached on each end of each bar, and two straps were connected to the buckles for fastening. The pad was made of a plastic plate covered by a soft cushion to decrease the effect of friction on the skin. The anterior pad was used for compression of the pectus carinatum. After fitting for the wearing of the compression brace, two ink marks were made on the two straps to identify the point of fastening. Even if the patients removed the brace for a bath or to change clothes, it could be refastened using this ink mark. The patients were instructed to wear the brace over a t-shirt (Fig. 2C) for 20 hours per day and to symmetrically tighten the straps as tolerated. We did not have a pressure monitoring system, but the pressure on the anteroposterior projection of the chest is easy to monitor; when pressure is sufficient, a red mark over the area of sternal protrusion persists for several hours after brace removal. Patient satisfaction was measured using a scoring sheet at 12 months after the initiation of the treatment (Table 1). The initial follow-up visit was scheduled to take place 2 to 3 weeks after initiating treatment to assess the patients' compliance and the fit of the orthosis, followed by visits every 3 months until the treatment was deemed successful.

RESULTS

The mean age of the patients was 12.9 years (range, 3.4 to 19). Of all the patients, there were 17 males (94.4%). Classified by the location and shape of the pectus carinatum, 17 were lower sternum type. Symmetric deformities occurred twice as frequently as asymmetric deformities (12:6).

The compression brace treatment was completed by 13 out

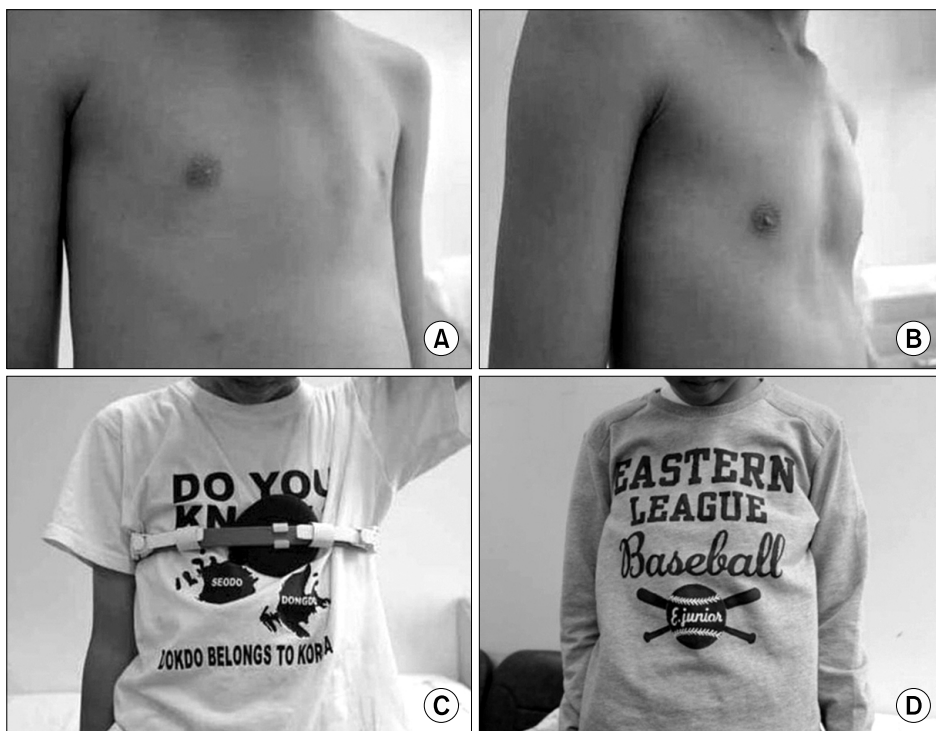


Fig. 2. (A) A picture of a pectus carinatum patient before brace treatment. (B) A picture of the same patient when brace treatment was completed. (C) Wearing of the compression brace over the patient's shirt. (D) The compression brace is not easily noticeable when clothes are worn over it.

Table 1. Satisfaction score

Satisfaction score	Contents
1	No correction
2	Minimal correction
3	Improved
4	Remarkable improvement

A telephone survey was performed at 12 months after initiation of the treatment. The score was measured in a 4-step grading system.

of 18 patients. The mean bracing time was 4.9 ± 1.4 months, and 5 patients (27.8%) were noncompliant and withdrawn. The mean satisfaction score among the 13 patients who completed the compression brace treatment was 3.73 ± 0.39 . Those who were treated for more than 6 months showed a mean satisfaction score of 4.0 and had no recurrence. Among the 5 patients who dropped out, 3 were infants who were uncooperative and 2 were late adolescences who complained of severe pain. A minimal recurrence of pectus carinatum occurred in 5 out of 13 patients (38.5%). These patients stopped treatment at 4 months. All of the treated patients showed improvement and minimal recurrence.

A dramatic improvement in protrusion of the chest wall is noted in a picture and computed tomography (CT) scan of a pectus carinatum patient before and after brace treatment (Figs. 2A, B, 3). As an objective result, the Haller index (HI) was measured. The mean pre-treatment HI was 2.13 ± 0.18 , and the mean post-treatment HI was 2.98 ± 0.24 . The pectus carinatum deformity (post-treatment HI) had significantly improved over the pre-treatment status ($p < 0.001$).

There were no intractable sequelae due to wearing the brace, even with continuous daily wear. None of the patients required analgesics while wearing the brace. Although mild erythema was noted at the point of greatest pressure applied by the brace, there was no skin breakdown.

DISCUSSION

The conventional treatment of pectus carinatum is the modified Ravitch procedure and the modified Nuss procedure that uses a Nuss bar. These surgical modalities require general anesthesia and cause cosmetic problems and post-operative pain [5,9]. Some of the patients have had functional problems such as recurrent upper respiratory tract infection

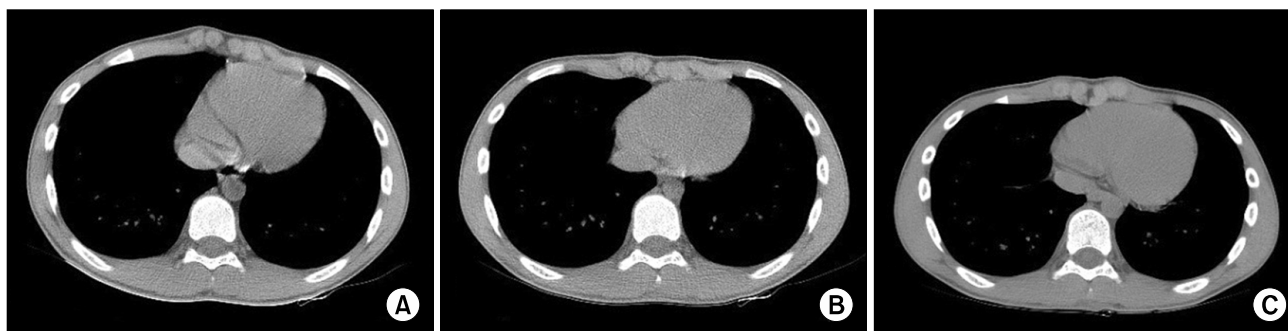

Fig. 3. These computed tomography scan images show three consecutive images taken from the same patient before, during, and after the recommended cycle of bracing treatment. A dramatic improvement in protrusion of chest wall is noted. (A) Before brace. (B) 2 months after brace. (C) 6 months after brace.

and a decrease in lung compliance due to chest wall rigidity. However, in the majority of them, the problems are confined to psychological and cosmetic issues. This has caused a strong desire for developing a less invasive treatment. Correction by bracing was first reported by Haje [10] in the 1990s, and many clinical trials are actively being performed worldwide. The majority of the trials have reported good responses.

Brace treatment does not require general anesthesia and surgery, and does not leave an operative scar. The treatment is performed at an outpatient clinic. It also more cost effective, and moreover, the result is not inferior to that of the surgical treatment [1-4,8]. The single most important factor that contributed to the results has been patient compliance, which is also proven in this study [3,8]. The patients who have completed the treatment protocol, which the medical staff has recommended, showed satisfaction scores superior to that of those who did not complete the treatment. Of the total patients, 27.8% were noncompliant and dropped out during treatment. In 2008, Stephenson and Du Bois [3] reported that 8 of 36 patients (22.2%) were noncompliant and dropped out during the treatment, and only 4 (14.2%) of the 28 who had completed the treatment required a modified Ravitch procedure [3].

There is no standardized protocol for the treatment of pectus carinatum using braces, but the methods are substantially similar. Long-term results of brace therapy are still rarely being reported, but it is well-known that brace therapy is more effective if applied before a growth spurt [2]. Brace therapy

was less effective in young adults over 19 years of age, and this is thought to be due to differences in chest wall flexibility [4]. Selection of ideal patients for brace therapy is important, but there is no general consensus.

The improvement of pectus carinatum is measured using a chest CT scan. However, considering that most patients are concerned about the cosmetic results, satisfaction can be a better tool to measure clinical outcome. A telephone survey was performed 12 months after initiation of the treatment, and continuous follow-up is required.

As noted by other authors [2,8], patient compliance with regular brace wear and diligent follow-up are paramount to the success of this method of treatment. Bracing is effective when the brace is worn for the required number of hours per day. Early improvement in the pectus deformities was seen in the majority of patients. However, total correction required prolonged use of the device. This should be explained to patients upon initiation of treatment to prevent unrealistic expectations.

CONCLUSION

Brace therapy has shown favorable outcomes and has made it possible to avoid surgical complications. For these reasons, we adopted bracing as the first-line treatment for pectus carinatum. The surgical treatment was used as a second-line treatment in patients who were noncompliant to the brace treatment. Patient compliance was the single most important factor to the treatment outcomes, and poor compliance can be

improved by technical improvement and systematic education.

CONFLICT OF INTEREST

No potential conflict of interest relevant to this article was reported.

REFERENCES

1. Martinez-Ferro M, Fraire C, Bernard S. *Dynamic compression system for the correction of pectus carinatum*. *Semin Pediatr Surg* 2008;17:194-200.
2. Egan JC, DuBois JJ, Morphy M, Samples TL, Lindell B. *Compressive orthotics in the treatment of asymmetric pectus carinatum: a preliminary report with an objective radiographic marker*. *J Pediatr Surg* 2000;35:1183-6.
3. Stephenson JT, Du Bois J. *Compressive orthotic bracing in the treatment of pectus carinatum: the use of radiographic markers to predict success*. *J Pediatr Surg* 2008;43:1776-80.
4. Lee SY, Lee SJ, Jeon CW, Lee CS, Lee KR. *Effect of the compressive brace in pectus carinatum*. *Eur J Cardiothorac Surg* 2008;34:146-9.
5. Poullis M. *Modified Nuss repair for pectus carinatum*. *Interact Cardiovasc Thorac Surg* 2010;11:221-2.
6. Robicsek F, Watts LT, Fokin AA. *Surgical repair of pectus excavatum and carinatum*. *Semin Thorac Cardiovasc Surg* 2009;21:64-75.
7. Del Frari B, Schwabegger AH. *Ten-year experience with the muscle split technique, bioabsorbable plates, and postoperative bracing for correction of pectus carinatum: the Innsbruck protocol*. *J Thorac Cardiovasc Surg* 2011;141:1403-9.
8. Frey AS, Garcia VF, Brown RL, et al. *Nonoperative management of pectus carinatum*. *J Pediatr Surg* 2006;41:40-5.
9. Nuss D, Kelly RE Jr. *Minimally invasive surgical correction of chest wall deformities in children (Nuss procedure)*. *Adv Pediatr* 2008;55:395-410.
10. Haje SA. *Pectus carinatum successfully treated with bracing: a case report*. *Int Orthop* 1995;19:332-3.