

상부 견갑 현수 복합체의 3중 붕괴 - 5년 추시 증례 보고 -

경상대학교 정형외과학교실 및 건강과학연구원

성창민 · 박형빈

Triple Disruption of the Superior Shoulder Suspensory Complex - Case Report at 5-year-follow up -

Chang-Meen Sung, M.D., Hyung Bin Park, M.D., Ph.D.

*Department of Orthopaedic Surgery and Institute of Health Sciences,
Gyeongsang National University Hospital, Jinju, South Korea*

A triple disruption of the SSSC, an extremely rare injury, has been reported by only a few authors. We present a patient who had sustained a triple disruption of the SSSC: coracoid and scapular spine fractures, and an acromioclavicular joint separation. Treatment consisted of an anatomical restoration of the SSSC, with maintenance of the acromiohumeral and coracohumeral distances; this was achieved by open reduction and internal fixation of the fractures and of the separation. Six months after surgery, the injured shoulder was asymptomatic, with full range of motion. Five years after surgery, at the final follow-up, the function of the SSSC had been restored to the patient's complete satisfaction.

Key Word: Floating shoulder, Coracoid fracture, Scapular fracture, AC joint separation, SSSC

Introduction

The concept of a superior shoulder suspensory complex (SSSC), composed of the interacting structures which suspend the upper extremity from the trunk, was introduced by Goss.¹⁾ The anatomical integrity of the SSSC is essential to

the proper functioning of the upper extremity. Single disruptions of the SSSC, such as distal clavicle fractures, are common and do not violate its integrity. Double disruptions of the SSSC, however, create unstable situations that may heal only slowly and with poor functional outcomes.¹⁾ Several reports in the literature

※통신저자: 박형빈

경상남도 진주시 칠암동 90번지

경상대학교 정형외과학교실 및 건강과학연구원

Tel: 055) 750-8668, Fax: 055) 761-9447, E-mail: hbinpark@gnu.ac.kr

접수일: 2012년 5월 22일, 1차 심사완료일: 2012년 9월 12일, 2차 심사완료일: 2012년 12월 15일, 게재 확정일: 2012년 12월 15일

have described both operative and nonoperative managements of injuries regarding single and double disruption of SSSC.²⁾ However, there are only limited reports regarding triple disruption of the SSSC and no treatment guideline as to which elements should be stabilized.

We report the relatively long-term follow-up results (5 years) of an unusual case involving a triple disruption of the SSSC: a displaced coracoid process fracture, a displaced scapular spine fracture, and an acromioclavicular joint separation, which together completely compromised the linkage between the clavicle and the scapula.

Case Report

A man (age: 62 completed years) fell from a

height during a mountain hike, landing on the posterolateral aspect of his right shoulder. The patient was referred to the authors' institution 10 days after the injury, and was treated by immobilization of his right arm in a sling for this period under the diagnosis of acromioclavicular joint separation. Physical examination showed tenderness at the coracoid process, at the base of the scapular spine, and at the acromioclavicular joint, which also had superior instability. The radiographs of the shoulder showed fractures of the scapular spine and of the base of the coracoid process, as well as the acromioclavicular joint separation. These injuries were confirmed by 3D computed tomography (Fig. 1). Additionally, we noted that the fractured scapular spine had rotated laterally, threatening to induce subacromial impingement

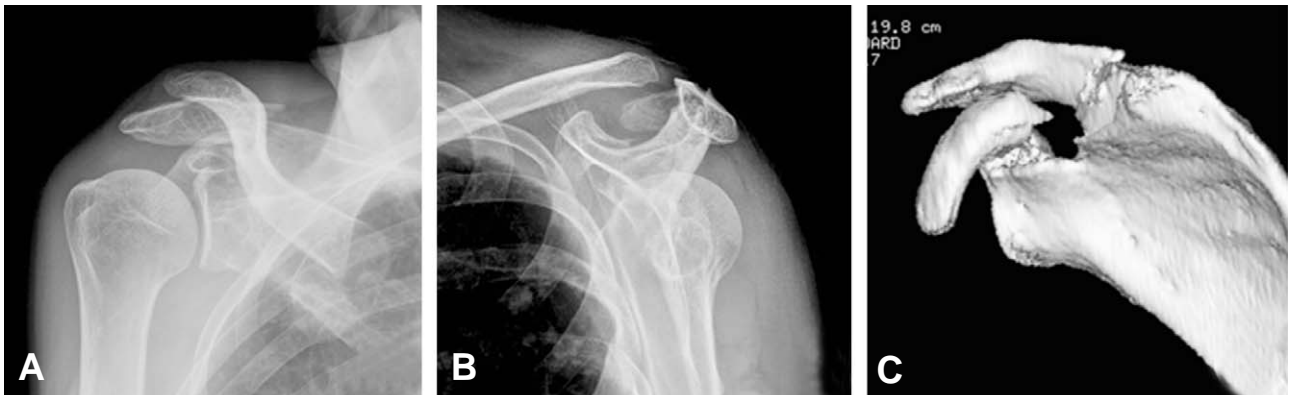

Fig. 1. Preoperative radiographs. (A) anteroposterior view, demonstrating the fractures of the scapular spine and of the base of the coracoid process, and the separation of the acromioclavicular joint. (B) Scapular Y view, demonstrating the fractures of the coracoid process and of the scapular spine, combined with the AC separation. (C) 3D CT images showing fractures of the scapular spine and of the coracoid process.

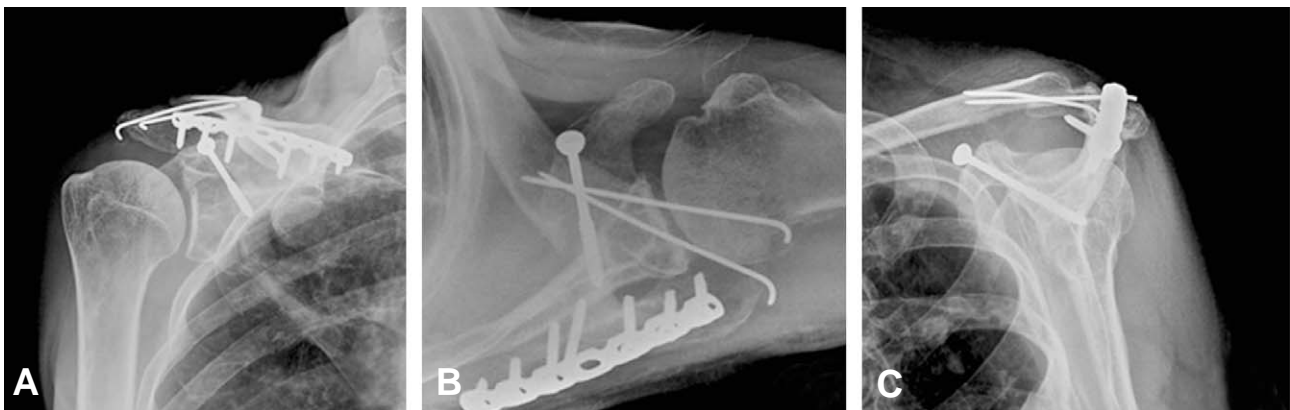


Fig. 2. Postoperative radiographs. (A) anteroposterior view, (B) axillary lateral view, and (C) scapular Y view, demonstrating that the fractures of the scapular spine and of the coracoid process, and the AC separation have been reduced and fixed operatively.

after fracture healing. To restore the SSSC and to perform early rehabilitation, we treated all three disrupted components surgically (Fig. 2). During the operation, the fracture of the scapular spine was reduced, and then fixed with a 3.5 mm reconstruction plate and screws. The displaced coracoid fracture was also reduced, and then fixed with a lag screw. The separation of the acromioclavicular joint was reduced, and then fixed with two K-wires. The acromioclavicular joint was further stabilized with plication of the deltoid and trapezius muscles and their overriding fascia.

After surgery, the shoulder was protected by a shoulder immobilizer for eight weeks. Considering the severity of injury and the interval between injury and operation, shoulder stiffness was the authors' first concern. Therefore, postoperative rehabilitation was performed immediately. On the first day after surgery, the patient performed the pendulum exercise and the passive range-of-motion exercises to 90 degrees flexion. Beginning on the fifth days

after surgery, the patient performed active-assisted range-of-motion exercises, as permitted by pain. After confirming the maintenance reduction of acromioclavicular joint and callus formation on base of coracoid process and scapular spine, we removed the two K-wires from the acromioclavicular joint in the eighth weeks of postoperation, by which time the patient had recovered nearly the full range of shoulder motion with minimal discomfort. Six months after surgery, the patient was asymptomatic with painless full range of motion. Plate was removed in 2 years after surgery.

Five years after surgery, at the final follow-up, the AC joint showed mild superior subluxation, but the patient reported great satisfaction and no discomfort (Fig. 3). The patient's Constant and Simple shoulder test scores were then 99.1 and 12 points, respectively.

Discussion

The SSSC is a ring composed of bone and soft

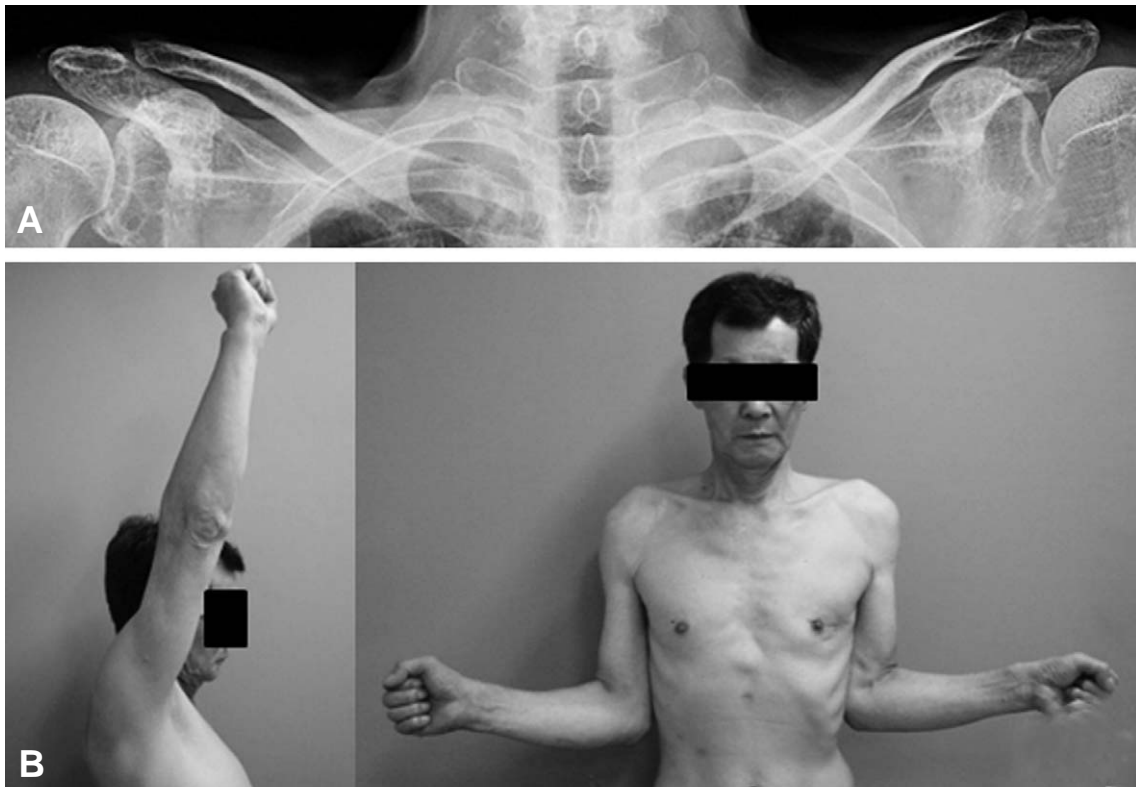


Fig. 3. Postoperative 5 years at final follow-up. (A) A radiograph shows complete fracture union and mild superior subluxation of the acromioclavicular joint. (B) Clinical photographs, demonstrating good functional range of motion.

tissue, comprising the glenoid process, the coracoid process, the coracoclavicular ligament, the distal end of the clavicle, the acromioclavicular joint, the coracoacromial ligament, and the acromial process.¹⁾ The integrity of the SSSC is essential to a normal relationship between the upper extremity and the trunk. Single traumatic disruptions of the SSSC is relatively common and anatomically stable in terms of the suspensory complex; they are managed nonoperatively and generally with satisfactory results.¹⁾ However, a double disruption of the SSSC create an unstable anatomic situation. These double injuries generally require surgical stabilization of one or both components in order to facilitate early rehabilitation, obtain a good functional result, and avoid a failure of fixation.¹⁻⁴⁾ A triple disruption of the SSSC, an extremely rare injury, have been reported by only a few authors.

According to the patient, his point of contact with the ground was the posterolateral aspect of his right shoulder. The authors agree that that were three forces that involved in the mechanism of the injury. First, the bending force likely contributed to the fracture of the scapular spine. Second, the axial force on clavicular-acromioclavicular joint-acromial strut led to the patient's acromioclavicular joint separation. Finally, traction force on the coracoid process led to its fracture. More powerful force seems to be involved in the same mechanism of acromion fracture combined with type III AC joint separation, which is one kind of double disruption of SSSC injury.

Ogawa et al.⁵⁾ in an excellent study of cases involving fractures of the acromion and of the lateral scapular spine, included several cases of triple disruption of the SSSC. That study reported that acromion fractures and extremely lateral part of scapular spine fractures were frequently associated with several related injuries, including coracoid fractures and/or acromioclavicular joint separation. However, that study did not specify, for each repaired element of the SSSC, either the treatment methods used or the clinical results obtained.

Lecoq et al.⁶⁾ reported a case similar to the current one. That patient had a displaced fracture of the coracoid process and of the acromion, and an undisplaced fracture of the clavicle. Of those injuries, only the coracoid process was treated, using open reduction and stabilization. At their final follow-up, the coracohumeral distance had been restored, but the acromiohumeral distance in the sagittal plane had decreased. Based on this outcome, Lecoq et al.⁶⁾ recommended open reduction of displaced fractures around the rotator cuff to prevent impingement between the rotator cuff and the coracoid process or the acromion. Kuhn et al.⁷⁾ likewise recommended that an acromial fracture that was reducing the subacromial space should be treated with early surgical intervention. That study, which was relevant to the current case, stressed that nonsurgical treatment would result in significantly limited and painful shoulder motion. Additionally, several authors, in studies limited to double disruptions of the SSSC, have reported cases of coracoid process fracture or acromion fracture associated with AC joint separation,^{8,9)} or of concomitant coracoid process fracture without AC joint separation.¹⁰⁾ Those authors emphasized the importance of stabilizing all the disrupted elements of the SSSC, an approach which was relevant to the current case.

The authors encountered a patient with a very rare triple disruption of the SSSC, which involved a coracoid process fracture, an acromion process fracture, and an AC joint separation. The authors treated that patient successfully. We recommend that, in similar cases, all three disrupted components of the SSSC be treated surgically, in order to achieve stabilization of the shoulder girdle and in order to restore the suspensory function and the normal subacromial and coracohumeral distances.

REFERENCES

- 1) **Goss TP.** *Double disruptions of the superior shoulder suspensory complex. J Orthop Trauma. 1993;7:99-106.*
- 2) **Leung KS and Lam TP.** *Open reduction and internal*

- fixation of ipsilateral fractures of the scapular neck and clavicle. J Bone Joint Surg Am. 1993;75:1015-8.*
- 3) **Oh W, et al.** *The treatment of double disruption of the superior shoulder suspensory complex. Int Orthop. 2002;26:145-9.*
 - 4) **Herscovici D, Jr., Fiennes AG, Allgower M and Ruedi TP.** *The floating shoulder: ipsilateral clavicle and scapular neck fractures. J Bone Joint Surg Br. 1992;74:362-4.*
 - 5) **Ogawa K, Yoshida A, Takahashi M and Ui M.** *Fractures of the coracoid process. J Bone Joint Surg Br. 1997;79:17-9.*
 - 6) **Lecoq C, Marck G, Curvale G and Groulier P.** *Triple fracture of the superior shoulder suspensory complex. Acta Orthop Belg. 2001;67:68-72.*
 - 7) **Kuhn JE, Blasier RB and Carpenter JE.** *Fractures of the acromion process: a proposed classification system. J Orthop Trauma. 1994;8:6-13.*
 - 8) **Barentsz JH and Driessen AP.** *Fracture of the coracoid process of the scapula with acromioclavicular separation. Case report and review of the literature. Acta Orthop Belg. 1989;55:499-503.*
 - 9) **Kurdy NM and Shah SV.** *Fracture of the acromion associated with acromioclavicular dislocation. Injury. 1995;26:636-7.*
 - 10) **Lim KE, et al.** *Concomitant fracture of the coracoid and acromion after direct shoulder trauma. J Orthop Trauma. 1996;10:437-9.*

초 록

상부 견갑 현수 복합체(Superior shoulder suspensory complex)의 3중 붕괴는 몇몇 저자들에게 의해서만 보고된 극히 드문 손상이다. 저자들은 오구돌기, 견갑골 골절 및 견봉-쇄골 관절의 탈구가 동반된 상부 견갑 현수 복합체의 3중 붕괴 환자를 경험하였기에 보고하고자 한다. 본 환자의 경우 견봉-상완 및 오구-상완 간격을 유지하기 위하여 관혈적 정복 및 내고정을 시행하여 상부 견갑 현수 복합체의 3중 붕괴 모두를 해부학적으로 복원하여 치료하였다. 술 후 6개월에 증상 없이 관절운동범위를 모두 회복하였다. 최종 추시인 5년에는 상부 견갑 현수 복합체의 기능이 완전히 회복된 것을 확인할 수 있었으며, 환자는 수술 결과에 대하여 크게 만족하였다.

색인 단어: 부유견, 오구 골절, 견갑골 골절, 견봉쇄골관절 탈구, 상부 견갑 현수 복합체