

RESEARCH ARTICLE

Expression of Survivin and Caspase 3 in Oral Squamous Cell Carcinoma and Peritumoral Tissue

SX Li^{1,2}, L Chai^{2,4}, ZG Cai³, LJ Jin², Y Chen³, HR Wu¹, Z Sun^{1*}

Abstract

This study was conducted to investigate the expression of survivin and caspase 3 in oral squamous cell carcinoma and peritumoral tissue, and possible pathogenesis mechanisms. We used ELISA and western blotting to detect the protein expression levels of survivin and caspase 3 in tissue. In situ hybridization and real-time PCR were applied to assess mRNA expression levels. In this study, 13 tumor samples and 13 peritumoral tissue samples were collected from oral squamous cell carcinoma patients and 10 normal tissue samples obtained from patients without tumor. The result showed that the protein and mRNA expression of survivin in carcinoma was the highest among three types of tissue; following was that in peritumoral tissue. No difference in caspase 3 zymogen between peritumoral tissue and normal tissue could be found, while it was evidently decreased in carcinoma tissue. Activated caspase 3 was detected in normal tissue but could not be identified in peritumoral or carcinoma tissue. Our results indicate that the expression of survivin is apparently elevated in tumoral and peritumoral tissue. Expression of activated caspase 3 was not detected in tumoral tissue and the expression of caspase 3 zymogen was decreased in tumoral tissue. Our findings suggest that survivin may inhibit both synthesis and activation of caspase 3, hence inhibiting cell apoptosis and facilitating eventual development of oral squamous cell carcinoma.

Keywords: Survivin - caspase 3 - oral squamous cell carcinoma - apoptosis

Asian Pacific J Cancer Prev, **13** (10), 5027-5031

Introduction

Oral squamous cell carcinoma (OSCC) is one of the commonest malignant tumors in human, the development of which includes a number of malfunctions in gene regulation such as activation of oncogenes and inhibition of cancer suppressor genes. In recent years, it has been known that a serial changes in the process of apoptosis is also an essential feature of cancer cells (Gibson and Shillitoe, 2006). Apoptotic process involves an intricate cascade of events which is highly regulated (Malaguarnera et al., 2012; Ko et al., 2012). Currently it is believed there are two major pathways in apoptosis both in which caspase 3 are involved (Yu et al., 2012). One is extrinsic that relies on a cell surface stimulus and the other is intrinsic that occurs as a consequence of cellular stress and is mediated by cytochrome c in mitochondrion. Usually caspase 3 exists as an inactive 32kD zymogen in cytoplasm, also known as pro-caspase 3. After activated in early apoptotic process, it leads to limited proteolysis events and then the destruction of the cell (Grutter 2000; Bursch 2008). It has been found that caspase 3 can be regulated by several inhibitor of apoptosis proteins (IAPs), in which survivin is the smallest yet strongest anti-apoptotic member (Kanwar et al., 2012; McKenzie and Grossman, 2012; Zhang et al., 2012). Survivin is a 16.5kD intracellular

protein containing a single Cys/His baculovirus IAP repeat (BIR) and lacking a carboxyl-terminal RING finger. It has the effect of protecting cells and keeping the integrity of microtubule framework. The feather of this protein is expressed considerably in the tissue of embryo and not expressed in the normal tissue well differentiated, but this protein is reexpressed largely in many kinds of tumor tissue. It can inhibit caspase 3 directly and indirectly so that preventing apoptosis. Then the tumor cell should escape from apoptosis and encourage formation of the multiploid.

The tumor has the feather of infiltration and transfusion. The infiltrating tumor cells have the spurious that can invade the adjacent tissue so that the tissue in the distance under 2cm to the tumor is different with the normal tissue and this kind tissue named peritumoral tissue (Mangiola et al., 2007; Sica et al., 2011; Loncarević et al., 2012). Now many studies have found that the expression of surviving evidently upgrade and the caspase 3 downgrade in the tumor, but how about that in the peritumoral tissue? What is the potential mechanism of the expression of caspase 3? This should be investigated penetrately. To investigate the function of survivin and caspase 3 in the development of OSCC, 13 tumor and 13 peritumoral tissue samples from patients with OSCC and 10 normal tissue samples from patients without cancer were collected in this

¹School of Stomatology, Capital Medical University, ²Faculty of Dentistry, The University of Hong Kong, HKSAR, ³School of Stomatology, Peking University, China, ⁴School of Dentistry, University of Queensland, Australia *For correspondence: sxlicn@163.com

study. Protein and mRNA expression levels of survivin and caspase 3 in different tissue were identified through ELISA, western blot, in situ hybridization (ISH) and quantitative real-time PCR (qRT-PCR).

Materials and Methods

Sample selection

Subjects were recruited from inpatients diagnosed with or without OSCC (no history of receiving chemo- or radio therapy) in the Oral Maxillofacial Surgery Unit, School of Stomatology, Peking University, between May to October 2008. Content forms were obtained from all patients before taking specimens. Thirteen tumor and 13 peritumoral tissue were obtained from patients with OSCC and another 10 normal tissue samples were obtained from patients without tumor. All samples were diagnosed and categorized by two experienced pathologists according to 1996 WHO diagnostic criteria for oral mucosa carcinoma and premalignant lesions. Table 1 showed the profile of the patients and their diagnosis.

Three pieces of tumor tissue and peritumoral tissue within 3×3×3 mm³ were obtained from each patient during the surgical process. One piece was frozen in liquid nitrogen immediately then stored in -70°C before ELISA and Western blot; one piece was put into buffer RNeasy[®] (Applied Biosystems, Foster City, CA, USA) at room temperature for 24 hours then stored in -70°C before qRT-PCR; the other piece was fixed in formalin, and then embedded in paraffin before ISH.

Assays

tissue, peritumoral tissue and normal tissue specimen. CellLytic[™] MT Mammalian Tissue lysis/extraction Reagent (Sigma-Aldrich, St.Louis, MO, USA) was used to extract total protein from each sample. Then Human survivin ELISA kit (R&D Systemes, Minneapolis, MN, USA) was used to detect survivin levels.

Western blot was used to identify both pro-caspase 3 and caspase 3 protein levels in different tissue specimens. Total protein was extracted from each sample by CellLytic[™] MT Mammalian Tissue lysis/extraction Reagent (Sigma-Aldrich, St.Louis, MO, USA). Protein concentration was measured with Protein Assay Dye Reagent Concentrate (Bio-Rad, Hercules, CA, USA) and Bovine Serum Albumin, BSA (Sigma-Aldrich, St.Louis, MO, USA). Aliquoted protein samples were subjected to SDS-PAGE, and then transferred to PVDF membrane (Qiagen, Hilden, Germany). After incubated with anti-β Actin (Abcam, Cambridge, MA, USA), pro-caspase 3 antibody (Neomarkers, Fremont, CA, USA) and caspase 3 activated fragment antibody (Cell signaling Technology, Danvers, MA, USA), WesternBreeze Chromogenic Western Blot Immunodetection Kit (Qiagen, Hilden, Germany) was used for immunodetection.

qRT-PCR was used to detect mRNA expression levels of survivin and caspase 3 in different tissue. RNeasy Mini - RNA Purification Kit (Qiagen, Hilden, Germany) was used to extract total RNA from each sample. cDNA was then reverse transcribed from total RNA following SuperScript[™] First-Strand Synthesis System for RT-PCR

(Invitrogen, Carlsbad, CA, USA). StepOne Real Time PCR System (Applied Biosystems, Foster City, CA, USA) was used for qRT-PCR. Survivin PCR primer sequences: Forward- 5'GTC AGC CCA ACC TTC ACAT; Reverse- 5'GGC GAA TCA AAT CCA TCAT. Caspase 3 primers: Forward- 5'CAG AAC TGG ACT GTG GCA TTG; Reverse- 5'GCTTGT CGG CATACT GTTTCA. β-Actin primers: Forward-5' AGTTGCGTTACACCCTTTCTTG; Reverse-5' TGCTGTCACCTTCA CCGTTC. Normal tissue sample was used as normal control. β-Actin was used as internal control. Each well was duplicated. Each experiment was repeated twice. Therefore for each sample, there were 4 reads of survivin, caspase 3 and β Actin as well. After minus mean Ct of β Actin, the mean Ct of survivin and caspase 3 were compared.

ISH was used to detect and localize survivin mRNA expression levels in different tissue specimens. After dewaxing and rehydration, tissue slides were immersed in proteinase K solution (Sigma-Aldrich, St.Louis, MO, USA) at 37°C for 30mins. Then tissue slides were incubated with hybridization buffer (Denhardt's solution (Sigma-Aldrich, St.Louis, MO, USA), 50% methanamide (Sigma-Aldrich, St.Louis, MO, USA), 0.3M NaCl, 0.02M Tris, 0.005M EDTA, 10% dextran sulfate, 0.1M DTT, 500 ug/ml yeast tRNA (Roche, Basel, Switzerland) and 500 ug/ml denatured salmon sperm DNA (Sigma-Aldrich, St.Louis, MO, USA) at 46°C for 2 hrs. Then samples were incubated with probes and hybridization buffer at 46°C overnight. After post-hybridization wash, they were incubated with blocking solution (Roche, Basel, Switzerland) for 30mins. And then were incubated with AP-conjugated anti-digoxigenin Fab fragment (Roche, Basel, Switzerland) at 37°C for 3hrs. Finally were incubated with NBT/BCIP solution (Roche, Basel, Switzerland) overnight. Probe was designed by the authors and synthesized by Sigma. Probe sequence was CATGGGTGCC CCGACGTTGC CCCCTGCCTG GCAGCCCTTT CTCAAGGACC ACCGCATCTC TACATTCAAG AACTGGCCCT TCTTGGAGGG CTGCGCCTGC ACCCCGGAGC GGATGGCCGA GGCTGGCTTC ATCCACTGCC CCACTGAGAA CGAGCCAGAC TTGGCCAGT GTTTCTTCTG CTTCAAGGAG CTGGAAGGCT GGGAGCCAGA TGACGACCCC AT. Positive signal was identified as blue-purple while negative was no stained under microscopy.

Statistical analysis

SPSS for Windows 11.5 software package was used for statistical analysis. Paired t test was used to compare expression levels of tumor and peritumoral tissue. One-way ANOVA was used to compare expression levels between three groups. Spearman's rank correlation coefficient was used to describe to correlation between pathological grade and stain intensity in ISH. $p < 0.05$ was considered as significant difference.

Results

Expression of survivin in OSCC tissue

Survivin protein expression levels detected by ELISA

in tumor tissue, peritumoral tissue and normal tissue were 3637.56 ± 784.65 pg/ml, 494.12 ± 72.38 pg/ml and 19.35 ± 4.89 pg/ml, respectively. Survivin in tumor tissue was significantly higher than in peritumoral tissue, while survivin in normal tissue from tumor-free patients was significantly lower than tumor and peritumoral tissue ($p < 0.01$) (Table 1).

In ISH, the standard positive stain of survivin mRNA in tissue was purple-blue in cytoplasm and nucleolus. According to the standard color, the intensity of cell stain was categorized into “-” as negative, “±” as uncertain, “+” as weak positive, “++” as moderate positive and “+++” as highly positive. In the 13 specimens from OSCC, the survivin mRNA expression in tumor cells were apparent, most of which were moderate to highly positive (Table 2, Figure 1A). In paraplasmic peritumoral tissue, the expression was weak to moderate positive (Figure 1B), while in normal tissue, only 3 samples appeared positive and one sample weak positive (Figure 1C). There was a significant correlation between histological feature and stain intensity ($p < 0.001$, $r^2 = 0.665$). In OSCC cells and paraplasmic cells, survivin was found in both cytoplasm and nuclei, however in normal tissue cells, it was only detected in nuclei.

When qRT-PCR was used to detect the mRNA

Table 1. Survivin Protein Levels in Different Tissues

Tissue	Survivin level (pg/ml)*
Carcinoma tissue	3637.56 ± 784.65
Peritumoral tissue	494.12 ± 72.38
Normal tissue	19.35 ± 4.89

* $p < 0.01$ between any two group comparisons

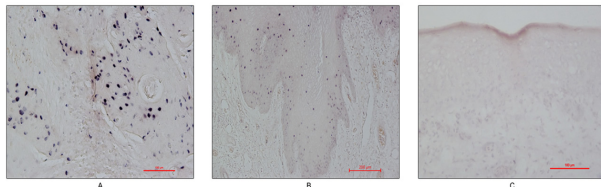


Figure 1. Survivin mRNA Expression by ISH. A. Survivin mRNA expression in carcinoma tissue were moderate to highly positive; B. Survivin mRNA expression in dysplastic peritumoral tissue was weak to moderate positive; C. Survivin mRNA expression in normal tissue

Table 2. Patients Profile and Survivin mRNA Expression Level Detected by ISH^a

No.	Age	Sex	Site	Pathological diagnosis	Normal tissue	Dysplasia	Carcinoma
1	60	F	Gingiva	OSCC ^b Grade I-II	-	NA	+
2	71	M	Lower lip	OSCC Grade I	-	++	++
3	82	M	Maxilla	OSCC Grade I-II	-	NA	++
4	75	M	Lower incisors	OSCC Grade I	-	+	++
5	73	F	Tongue	OSCC Grade I	-	-	+++
6	64	F	Bucca	OSCC Grade I-II with metastasis	+	++	+++
7	68	F	Gingiva	OSCC Grade I	-	NA	-
8	48	M	Tongue, dorsal	OSCC Grade II	+	NA	+
9	50	F	Tongue root	OSCC Grade I-II	+	++	++
10	60	F	Tongue	OSCC Grade I-II	-	-	+++
11	41	M	Gingival	OSCC Grade I	-	NA	-
12	47	M	Tongue root	OSCC Grade II	-	+	++
13	82	M	Maxilla	OSCC Grade I-II with metastasis	-	++	+++

^aIn situ hybridization; ^bOral squamous cell carcinoma; NA, no available tissue; -, negative; ±, uncertain; +, weak positive; ++, moderate positive; +++, highly positive

expression levels of survivin, in tumor tissue it was 5.55 ± 2.92 , in peritumoral tissue was 2.00 ± 1.29 , and the normal tissue expression was set as 1. The difference between three groups was statistically significant ($p < 0.001$, $df = 13$) (Figure 2A).

Expression of caspase 3 in OSCC tissue

Western blot was used to detect protein expression levels of both procaspase 3 and activated caspase 3. Figure 3A showed the bands of procaspase 3 with molecular mass about 32KD. After analysis of band intensity, the expression of procaspase 3 was found significantly lower in tumor tissue comparing to peritumoral tissue and normal tissue from patients without tumor ($p < 0.05$), while there

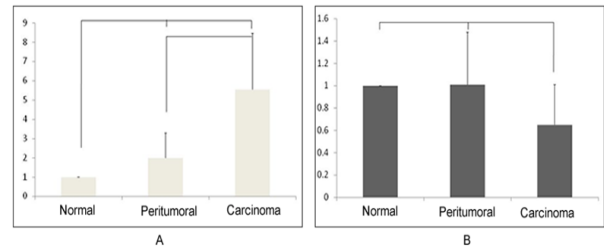


Figure 2. Survivin and Caspase 3 mRNA Expression Level by qRT-PCR. A. Survivin mRNA expression level. The difference between three groups was statistically significant ($p < 0.001$, $df = 13$). B. Caspase 3 mRNA expression level. Caspase 3 mRNA expression level in tumor tissue was significantly lower than in peritumoral and normal tissue ($p = 0.004$, $df = 13$). There was no difference of caspase 3 mRNA expression between peritumoral tissue and in normal tissue

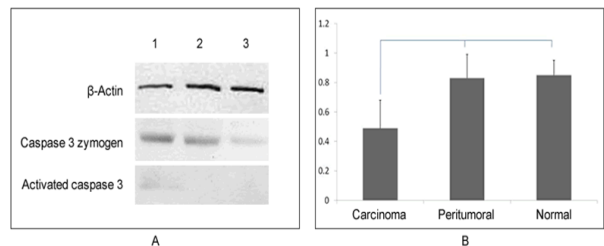


Figure 3. Caspase 3 Zymogen and Activated Caspase 3 Detected by Western Blot. A. Expression of caspase 3 zymogen and activated caspase 3 in different tissue. Band 1 was normal tissue, 2 was peritumoral tissue and 3 was carcinoma tissue. B. showed band intensity of caspase 3 zymogen compared with β -Actin. The intensity of carcinoma was significantly lower than of peritumoral and normal tissue ($p < 0.05$)

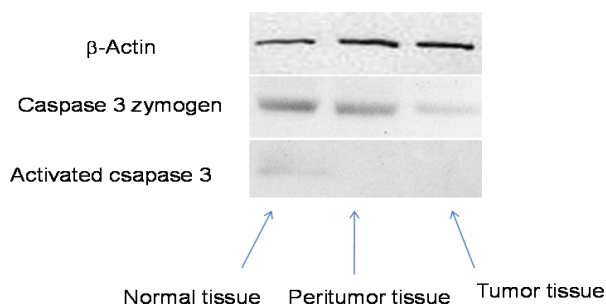


Figure 4. The Expression of Caspase 3 Zymogen and Activated Caspase 3

was no difference between peritumoral tissue and normal tissue (Figure 3B). The activated caspase 3 fragments were shown as bands with 19KD in Western blot. No activated caspase 3 fragment was found in tumor or peritumoral tissue. It could be only detected in normal tissue from patients without tumor (Figure 3A).

There was no difference of caspase 3 mRNA expression between peritumoral tissue and in normal tissue. Caspase 3 mRNA expression level in tumor tissue was 0.65 ± 0.36 , which was significantly lower than in peritumoral and normal tissue ($p = 0.004$, $df = 13$). Expression level in normal tissue was considered as 1 (Figure 2B).

In a whole, survivin expression was higher in tumor and peritumoral tissue than in normal group while in tumor tissue, its expression level was higher than in peritumoral tissue; caspase 3 expression in normal and peritumoral tissue was higher than in tumor tissue group, and there was no difference between it in normal and peritumoral tissue.

Discussion

Survivin is a mammal inhibitor of apoptosis protein (IAP) found recently. It is mainly expressed during embryogenesis and in tumor cells but not or low expressed in normal adult tissue, indicating apoptosis inhibition plays a role in tumor development. Tamm et al. investigated 60 human tumor cell lines and found survivin expression in all the 60 cell lines including such as breast, lung, colon, ovarian, prostate, renal, melanoma, leukemia and lymphoma as well (Tamm et al., 2000). Even some reports showed the elevated survivin in the bronchial aspirates could be the marker of lung cancer (Li et al., 2012). It has been reported that survivin can bind to caspase 3 and caspase 7 specifically, hence inhibits apoptosis mediated by caspase 3 and caspase 7. Moreover survivin can inhibit apoptosis mediated by Fas, Bax and chemotherapeutics (Suzuki et al., 2000). Another apoptosis inhibition mechanism of survivin is it interacts with cell cycle suppressors Cdk4 and p21, stops the signaling pathway of apoptosis, and hence inhibits apoptosis (Suzuki et al., 2000).

In our study, we found survivin expression in different levels was significantly increased in OSCC tissue, which was consistent to previous studies (Preuss et al., 2008; De Maria et al., 2009; Khan et al., 2009; Halasova et al., 2012). In peritumoral tissue that appeared normal with naked eye, we found both survivin mRNA and protein expression level increased comparing to normal controls

when detected by qRT-PCR and ELISA respectively. But when detected by ISH, survivin mRNA expression decreased in peritumoral normal tissue that determined histologically. This inconsistency may be because that epithelial paraplasmia could not be detected by naked eye sometimes hence survivin expression could still be detected by qRT-PCR or ELISA. Therefore it should be noticed to surgeons that to excise enough tissue to avoid possible paraplasmia epithelium remnant during the surgical removal.

Pathologically, the two specimens that showed the highest survivin protein expression in tumor and peritumoral tissue were ulcerative carcinoma. Two of the four specimens from patients with metastasis showed higher survivin expression in tumor and peritumoral tissue, yet another two showed lower survivin expression in tumor and peritumoral tissue than average. Recently many had showed survivin could be a biomarker of tumor (Waligórska-Stachura et al., 2012; Fraunholz et al., 2012). Ryan et al. have found that increased survivin in breast cancer tissue indicating worse treatment response and prognosis (Ryan et al., 2006). Another report showed the elevated survivin in the bronchial aspirates could be the marker of lung cancer (Li et al., 2012). Another study has reported that high levels of survivin are mainly related with a poor response to endocrine therapy in breast cancer patients, but a good response to chemotherapy. Therefore survivin expression level can be one of indications for clinical treatment selection (Span et al., 2006; Zheng et al., 2012). In our study, we found that survivin expression level was correlated with pathological characteristic of OSCC but not associated with tumor TMN grade.

Caspase 3 is member of a family of cysteine proteases and is a key enzyme for execution of apoptosis in many instances (Blanc et al., 2000; Kim et al., 2000; Seol et al., 2001). Previous study has shown that both activated caspase 3 and zymogen can be detected in normal tissue from gastric cancer patients but only zymogen can be identified in tumor tissue from the same patient group (Gomes et al., 2011). In our study, caspase 3 expression was significantly lower in tumor tissue than in peritumoral tissue and normal tissue; there was no activated caspase 3 found in tumor tissue, and only weak expression in 5 of 13 samples of peritumoral tissue in western blot. All of which was consistent to the findings in gastric cancer.

In our study, we have investigated survivin and caspase 3 in normal oral mucosa, dysplastic epithelium and OSCC tissue and measured the apoptosis status of those samples. We have found that with the transition from normal mucosa to paraplasmia to carcinoma, both the number of cells express survivin and survivin intensity are increasing. The opposite tendency has been found in caspase 3 in the same study. Previous animal model of lingual carcinoma also have found the increasing survivin expression is correlated to the development of oral carcinoma. Our current study showed consistent results. All these findings indicate that the increasing of survivin expression is the early event of oral mucosa oncogenesis, and the intensity of survivin expression is continuous increasing with the development of the disease. Therefore survivin can be regarded as a biomarker for monitoring

oral premalignant lesions. Caspase 3 has been shown to decrease in tumor tissue, indicating there is a negative correlation between survivin and caspase 3. Caspase 3 mRNA expression decreasing in tumor tissue indicates low activated caspase 3 in tissue. Therefore survivin can possibly inhibit the synthesis of caspase 3, hence blocks the apoptosis mediated by caspase 3, and finally leads to the development of OSCC.

Acknowledgements

This study was supported by The National Natural Science Foundation of China (30500559), Beijing Municipal Science & Technology Commission B (2005B51) and The postdoctoral Science Foundation of China (20060400486).

References

- Blanc C, Deveraux QL, Krajewski S, et al (2000). Caspase-3 is essential for procaspase-9 processing and cisplatin-induced apoptosis of MCF-7 breast cancer cells. *Cancer Res*, **60**, 4386-90.
- Bursch W, Karwan A, Mayer M, et al (2008). Cell death and autophagy: cytokines, drugs, and nutritional factors. *Toxicology*, **254**, 147-57.
- De Maria S, Pannone G, Bufo P, et al (2009). Survivin gene-expression and splicing isoforms in oral squamous cell carcinoma. *J Cancer Res Clin Oncol*, **135**, 107-16.
- Fraunholz I, Rödel C, Distel L, et al (2012). High survivin expression as a risk factor in patients with anal carcinoma treated with concurrent chemoradiotherapy. *Radiat Oncol*, **7**, 88.
- Gibson S, Shillitoe EJ (2006). Analysis of apoptosis-associated genes and pathways in oral cancer cells. *J Oral Pathol Med*, **35**, 146-54.
- Gomes TS, Oshima CT, Segreto HR, et al (2011). The extrinsic apoptotic signaling pathway in gastric adenocarcinomas assessed by tissue microarray. *Pathol Res Pract*, **207**, 613-7.
- Grutter MG (2000). Caspases: key players in programmed cell death. *Curr Opin Struct Biol*, **10**, 649-55.
- Halasova E, Adamkov M, Matakova T, et al (2012). Expression of Ki-67, Bcl-2, Survivin and p53 Proteins in Patients with Pulmonary Carcinoma. *Adv Exp Med Biol*, **756**, 15-21.
- Kanwar JR, Kamalapuram SK, Kanwar RK (2012). Survivin Signaling in Clinical Oncology: A Multifaceted Dragon. *Med Res Rev*. doi: 10.1002/med.21264.
- Khan Z, Tiwari RP, Mulherkar R, et al (2009). Detection of survivin and p53 in human oral cancer: correlation with clinicopathologic findings. *Head Neck*, **31**, 1039-48.
- Kim WH, Yeo M, Kim MS, et al (2000). Role of caspase-3 in apoptosis of colon cancer cells induced by nonsteroidal anti-inflammatory drugs. *Int J Colorectal Dis*, **15**, 105-11.
- Ko SY, Dass CR, Nurgali K (2012). Netrin-1 in the developing enteric nervous system and colorectal cancer. *Trends Mol Med*, **18**, 544-54.
- Li J, Chen P, Li XQ, et al (2012). Elevated levels of survivin and livin mRNA in bronchial aspirates as markers to support the diagnosis of lung cancer. *Int J Cancer*. doi: 10.1002/ijc.27757.
- Loncarević S, Vignjević S, Jović N, et al (2012). Significance of pathohistological findings and the expression of Bcl-2 in diagnosis and treatment of oral planocellular carcinoma. *Vojnosanit Pregl*, **69**, 314-9.
- Malaguarnera R, Morcavallo A, Belfiore A (2012). The insulin and igf-I pathway in endocrine glands carcinogenesis. *J Oncol*, **2012**, 635614.
- Mangiola A, Lama G, Giannitelli C, et al (2008). Stem cell marker nestin and c-Jun NH2-terminal kinases in tumor and peritumor areas of glioblastoma multiforme: possible prognostic implications. *Clin Cancer Res*, **13**, 6970-7.
- McKenzie JA, Grossman D (2012). Role of the apoptotic and mitotic regulator survivin in melanoma. *Anticancer Res*, **32**, 397-404.
- Preuss SF, Weinell A, Molitor M, et al (2008). Survivin and epidermal growth factor receptor expression in surgically treated oropharyngeal squamous cell carcinoma. *Head Neck*, **30**, 1318-24.
- Ryan BM, Konecny GE, Kahlert S, et al (2006). Survivin expression in breast cancer predicts clinical outcome and is associated with HER2, VEGF, urokinase plasminogen activator and PAI-1. *Ann Oncol*, **17**, 597-604.
- Seol JG, Park WH, Kim ES, et al (2001). Potential role of caspase-3 and -9 in arsenic trioxide-mediated apoptosis in PCI-1 head and neck cancer cells. *Int J Oncol*, **18**, 249-55.
- Sica G, Lama G, Anile C, et al (2011). Assessment of angiogenesis by CD105 and nestin expression in peritumor tissue of glioblastoma. *Int J Oncol*, **38**, 41-9.
- Span PN, Tjan-Heijnen VC, Manders P, et al (2006). High survivin predicts a poor response to endocrine therapy, but a good response to chemotherapy in advanced breast cancer. *Breast Cancer Res Treat*, **98**, 223-30.
- Suzuki A, Hayashida M, Ito T, et al (2000). Survivin initiates cell cycle entry by the competitive interaction with Cdk4/p16(INK4a) and Cdk2/cyclin E complex activation. *Oncogene*, **19**, 3225-34.
- Suzuki A, Ito T, Kawano H, et al (2000). Survivin initiates procaspase 3/p21 complex formation as a result of interaction with Cdk4 to resist Fas-mediated cell death. *Oncogene*, **19**, 1346-53.
- Tamm I, Kornblau SM, Segall H, et al (2000). Expression and prognostic significance of IAP-family genes in human cancers and myeloid leukemias. *Clin Cancer Res*, **6**, 1796-803.
- Waligórska-Stachura J, Jankowska A, Waško R, et al (2012). Survivin-- prognostic tumor biomarker in human neoplasms--review. *Ginekol Pol*, **83**, 537-40.
- Yu JQ, Bao W, Lei JC (2012). Emodin regulates apoptotic pathway in human liver cancer cells. *Phytother Res*. doi: 10.1002/ptr.4703.
- Zhang LQ, Wang J, Jiang F, et al (2012). Prognostic value of survivin in patients with non-small cell lung carcinoma: a systematic review with meta-analysis. *PLoS One*, **7**, e34100.
- Zheng WE, Chen H, Yuan SF, et al (2012). Overexpression of β III-tubulin and survivin associated with drug resistance to docetaxel-based chemotherapy in advanced gastric cancer. *J BUON*, **17**, 284-90.