

RESEARCH ARTICLE

Follow up of Atypical Squamous Cell Pap Smears in Iraqi Women

Intisar S Pity*, Maida Y Shamdeen, Shawnim A Wais

Abstract

Objectives: To report the prevalence of atypical squamous cells of undetermined significance and atypical squamous cells-cannot exclude high squamous intraepithelial lesions and to determine the possible association of Pap test results with high-risk human papillomavirus and high squamous intraepithelial lesions in women from Duhok, Iraq. **Design:** A prospective, observational study was conducted between January 2005 and December 2011. Overall, 596 women with a cervicovaginal Pap test showing atypical squamous cells of undetermined significance and 93 atypical squamous cells-cannot exclude high squamous intraepithelial lesion for whom pathologic follow-up was available were studied. Follow-up consisted of repeat cytology, colposcopy and histology. High risk human papillomavirus DNA testing was performed on exfoliated cervical cells from 106 women, using conventional PCR after at least 36 months from the initial Pap smear. **Results:** Significantly high proportions of both atypical squamous cells of undetermined significance (87.9%) and atypical squamous cells-cannot exclude high squamous intraepithelial lesion (62.4%) demonstrated no significant lesion on subsequent follow up. Low squamous intraepithelial lesions were observed in 1.7% of cases of atypical squamous cells of undetermined significance and in 5.4% of atypical squamous cells-cannot exclude high squamous intraepithelial lesion. High squamous intraepithelial lesion was demonstrated in 0.8% and 16.1% respectively. In the latter there was also one case of invasive carcinoma. High-risk HPV DNA was demonstrated in 40% of atypical squamous cells of undetermined significance and 57.1% of atypical squamous cells-cannot exclude high squamous intraepithelial lesions. **Conclusions:** Since both atypical squamous cells of undetermined significance and atypical squamous cells-cannot exclude high squamous intraepithelial lesion identify patients who are at an increased risk for the development of high squamous intraepithelial lesions and a considerable percentage harbor high risk-HPV, both should be retained as diagnostic categories and patients warrant a diligent follow up and testing for high risk-HPV DNA. Colposcopic evaluation and biopsy, when indicated, are a must.

Keywords: Pap smear - ASCUS - ASC-H - high-risk HPV-DNA

Asian Pacific J Cancer Prev, 13, 3455-3460

Introduction

Atypical squamous cell (ASC) is a name given, in a Pap smear or cervicovaginal cytology, to squamous cells that do not have a normal appearance but are not clearly precancerous. Being equivocal, the term ASC is categorized by The Bethesda System (TBS) 2001 into atypical squamous cells of undetermined significance (ASC-US) where the cytologic changes are suggestive of but, quantitatively or qualitatively, are insufficient for a definitive interpretation of squamous intraepithelial lesion (SIL) and into atypical squamous cells-cannot exclude high squamous intraepithelial lesion (ASC-H) where the atypical squamous cells exhibit some equivocal features suggestive of but not sufficient to call high squamous intraepithelial lesions (HSIL) (NCI Bethesda System, 2001; Selvaggi, 2003). In addition to the possible progression of ASC-US and ASC-H into HSIL or invasive malignancy, the link between these lesions and high risk-human papillomavirus (HR-HPV) creates

a great incentive to investigate the clinically significant association with these two cytologic entities (Solomon et al., 2001; Chivukula and Shidham, 2006; Bandyopadhyay et al., 2008). To clarify this paradox we propose initiated this study to monitor the cytological and histological results of women with ASC-US and ASC-H Pap smears for a 7 year period to determine the possible association of these abnormal Pap smears with HR-HPV and HSIL in women from Duhok Governorate, Iraq. The prevalence of ASC-US and ASC-H was also evaluated. To the best of our knowledge, this is the first prospective clinical study in Iraq.

Materials and Methods

This is a seven year prospective, observational and descriptive study conducted at Azadi Teaching Hospital-gynecologic clinic and Central laboratory, Duhok, Iraq, during a period extending from January 2005 to December 2011. Ethical approval to conduct the study was obtained

Department of Pathology, Faculty of Medicine, University of Duhok, Duhok, Iraq *For correspondence: dani2000fadi@yahoo.com

from the Faculty of Medicine Research Ethics Committee, and patient consent was obtained before enrolling participants in the study. Cervical smears were taken from 10,338 women with wooden Ayre's spatula and directly wet fixed by 95% ethanol. Pap smear results were reported according to the 2001 Bethesda System (NCI Bethesda System., 2001; Solomon et al., 2001). A slide showing ASC-US or ASC-H was initially reevaluated and further scrutinized by a cytopathologist for final report. When the diagnosis of atypical squamous cells was confirmed upon review, an attempt was made to keep patients under follow up for at least 36 months. Follow up included a repeat Pap smear twice at 4 month interval. Cohorts with persistent abnormal Pap smears were referred for colposcopic examination using aqueous solution of 5% glacial acetic acid and lugols' solution. When changes were observed, patients subsequently underwent a direct punch biopsy using Gaylor-Medina forceps. Other histological samplings included cone biopsy, endocervical curettage and total hysterectomy. No loop electrosurgical excision procedure (LEEP) was available at that time of the study. The biopsy specimens were formalin fixed, paraffin embedded and stained with Hematoxylin and Eosin stains (H&E). Those, in whom histological material was not obtained, were followed up by Pap smear with or without colposcopy.

Cytologic and histologic results were classified and reported as follows: NILM (negative for intraepithelial lesion or malignancy) for negative, reactive or inflammatory lesions; ASC-US for equivocal cases where the cytologic changes are suggestive of but inadequate for a definitive interpretation of SIL; ASC-H where the atypical squamous cells exhibit some equivocal features suggestive of but not sufficient to call HSIL; low squamous intraepithelial lesion (LSIL) for koilocytotic atypia and cervical intraepithelial neoplasia type-1 (CIN I); HSIL for cervical intraepithelial neoplasia type-2 (CIN II) and type-3 (CIN III); and malignancy when definite invasion was confirmed.

Continuous follow up Pap smear at 6 month interval was then recommended for all participants with abnormal cervical cytology even those who underwent total hysterectomy. The mean number of subsequent cervical smearing was 6.1 (range, 4-21) and the average follow-up duration was 41.2 months (Range: 36 to 84). The least favorable histologic or cytologic result on follow up, after being confirmed, was considered as the final outcome.

High-risk human papillomavirus DNA testing was performed on exfoliated cervical cells from 106 women after at least 36 months from the initial Pap test. Crude extracts of the cervical scrapes were used, as described previously (de Roda Husman et al, 1995). High-risk HPV DNA analysis protocol was performed by the conventional PCR-based assays using the HPV high-risk screen PCR-mix kit provided by Sacace Biotechnology (Sacace Company, Italy, and Catalog No. V-26-50R). The kit contained primers directed against 13 HR-HPV (16, 18, 31, 33, 35, 39, 45, 51, 52, 56, 58, 59, and 68). PCR technique and interpretation were carried out according to recommendations supplied by the manufacturer's (Sacace Company, Italy, and Catalog No. V-26-50R) and as

described previously (de Roda Husman et al., 1995; Jacobs et al., 1997; van den Brule, 2002). Negative control (DNA buffer) and positive HPV (type 31, 39 and 56) controls were run with the technique. Participants were scheduled for a return visit to obtain test results 2 weeks after testing. Because there was no current standard protocol in the clinic for positive HR-HPV DNA results, women were encouraged to continue cervical cytology screening or follow-up visits as recommended (Solomon et al., 2001). Interpretation of cytology, histology and HR-HPV testing was performed blinded to the other test results. The results were then analyzed by comparing cytological and histological criteria and HPV profile.

Statistical analysis: Significant associations between categorical variables were performed using chi-squared test and $p < 0.05$ was considered to be significant. Descriptive statistics were used to summarize demographic variables.

Results

Out of 10,338 conventional Pap smears, a total of 903 (8.7%) cases were reported to have atypical squamous cells (ASC) during the study period. These cases included 805 ASC-US (7.8%) and 98 (0.9%) ASC-H (Figure 1).

Two hundred and fourteen women were excluded from the study as there was no follow up (n=117), ASC-US/ASC-H diagnosis was not confirmed on further review (n=81) or when patients had clinically significant diagnoses defined as HSIL, LSIL, cervical adenocarcinoma in situ or invasive cervical carcinoma prior to the ASC Pap smear (n=16). The remaining 689 cases (596 ASC-US and 93 ASC-H) for whom follow up was possible, were recruited in the study. Patients' ages ranged from 18 to 79 years (median 48.5 years).

Table 1 demonstrates consensus cytology and histology

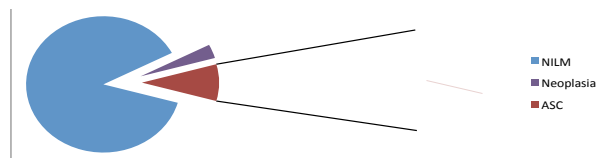


Figure 1. Percentage of Women with Atypical Squamous Cells (ASC) Out of Total Pap Tests. NILM: Negative for intraepithelial lesion or malignancy, Neoplasia included premalignant and malignant lesions, ASC: Atypical squamous cells

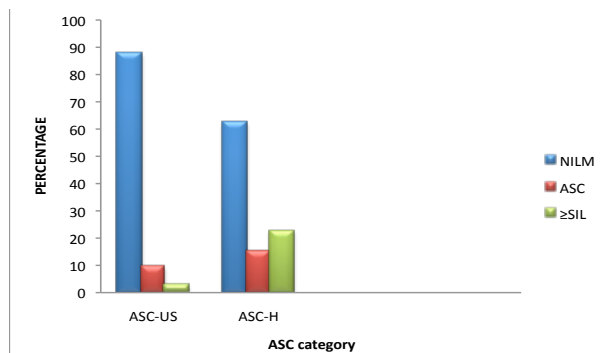


Figure 2. Result Percentages of ASC-US and ASC-H Pap Tests After Follow Up. NILM: Negative for intraepithelial lesion or malignancy, ASC: Atypical squamous cells, SIL: Squamous intraepithelial lesion

Table 1. Follow up Tests Used for the Studied Women (n=689)

ASC	Cytology only: n (%)	Histopathology n (%) ¶			
Total	136 (19.7)	553 (80.3)			
		Punch biopsy	Cone biopsy	ECC	Hysterectomy
		432 (62.7%)	76 (11.1%)	34 (4.9%)	11 (1.6%)
	124 (18.0%)	ASC-US (n=472; 79.2%)			
		367 (53.3%)	68 (9.9%)	32 (4.6%)	5 (0.7%)
		ASC-H (n=81; 87.1%)			
	12 (1.7%)	65 (9.4%)	8 (1.2%)	2 (0.3%)	6 (0.9%)

ASC, Atypical squamous cells; ASC-US, Atypical squamous cells of undetermined significance; ASC-H, Atypical squamous cells cannot exclude HSIL; ECC, Endocervical curettage; ¶, Histopathology with or without cytology

Table 2. Detailed Final Diagnoses after Follow up of ASC-US and ASC-H Cases

Diagnosis: Number (%)	ASC-US: Number (%)	ASC-H: Number (%)	P-value*
NILM: 582 (84.5)	524 (87.9)	58 (62.4)	<0.001
ASC: 71 (10.3)**	57 (9.6)	14 (15.1)	0.105
SIL: 35 (5.1)	15 (2.5)	20 (21.5)	
LSIL (15)	10 (1.7)	5 (5.4)	<0.001
HSIL (20)	5 (0.8)	15 (16.1)	<0.001
HSIL: LSIL	1:2	3:1	<0.001
SCC (1)	0.0	1 (1) SCC	0.02
Total (n=689)	596 (86.5)	93 (13.5)	<0.001

ASC-US, Atypical squamous cells of undetermined significance; ASC-H, Atypical squamous cells cannot exclude HSIL; NILM, Negative for intraepithelial lesion or malignancy; LSIL, Low-grade squamous intraepithelial lesion; HSIL, High-grade squamous intraepithelial lesion; *Chi-square used; **Persistent equivocal

results (n= 689). Histologic material (with or without cytology) was obtained from 553 (80.3%) women (79.2% of ASC-US and 87.1% of ASC-H). The mean number of histological specimens obtained was 2.1 (range, 1-4). Whereas cytologic follow-up without histology was done for 136 (19.7%) women, 124 (18.0%) ASC-US and 12 (1.7%) ASC-H.

The follow-up diagnoses of the study group are outlined in Figure 2 and Table 2. Significant percentages of both ASC-US (87.9%) and ASC-H (62.4%) groups showed no significant lesion on subsequent follow up, reported as NILM (p<0.001). On the other hand, 5.2% revealed LSIL and above. Significantly higher HSIL rate and higher HSIL: LSIL ratio were observed among ASC-H than ASC-US group (P<0.001). The single squamous cell carcinoma case was observed among ASC-H women. The remaining 9.6% of ASC-US cases showed persistent equivocal changes (ASC) versus 15.1% of ASC-H group. The difference was statistically not significance (p= 0.105).

High-risk human papillomavirus DNA testing was performed on 106 women, 65 (10.9%) ASC-US and 41 (44.1%) ASC-H. These cases comprised all patients showing SIL and more severe epithelial abnormalities (n=36) and randomly selected cases from NILM results (n=27) and from those showing persistent equivocal cytologic changes (n=43). Table 3 compares the HR-HPV DNA status with the follow up findings. Overall, 20 (18.9%) patients were positive for HR-HPV DNA. These

Table 3. High risk HPV (HR-HPV) DNA status in ASC-US and ASC-H

Lesion (n)	Positive HR-HPV: Number (%)			P-value
	Total	ASC-US	ASC-H	
Total SIL	18/36 (50%)	6/15 (40%)	12/21 (57.1%)*	NS
≥ HSIL	13/21 (61.9%)*	3/5 (60%)	10/16 (62.5%)*	NS
LSIL	5/15 (33.3%)	3/10 (30%)	2/5 (40%)	NS
ASC**	2/43 (4.7%)	1/34 (2.9%)	1/9 (11.1%)	<0.05
NILM	0/27 (0)	0/16 (0.0%)	0/11 (0.0%)	-
Total	20/106 (18.9%)	7/65 (10.8%)	13/41 (31.7%)	<0.05

HR-HPV, High risk human papilloma virus; ASC-US, Atypical squamous cells of undetermined significance; ASC-H, Atypical squamous cells cannot exclude HSIL; SIL, Squamous intraepithelial lesion; HSIL, High-grade squamous intraepithelial lesion; LSIL, Low-grade squamous intraepithelial lesion; ASC, Atypical squamous cells; NILM, Negative for intraepithelial lesion or malignancy; *including one carcinoma case; **Persistent equivocal

included 10.8% of ASC-US and 31.7% of ASC-H subjects. No significant viral DNA difference was noted between the two groups (P>0.05). Patients with follow-up proven HSIL of both ASC-US and ASC-H had positive HR-HPV in 60% while LSIL cases showed positive HR-HPV in 33.3% cases (P > 0.05). The single carcinoma case was positive for HR-HPV. On the other hand, persistent ASC revealed positive HR-HPV in 4.7% of cases. None of NILM cases showed evidence of HR-HPV.

Discussion

During the seven year study-period, ASC-US represented 7.8% of total Pap tests done while ASC-H accounted 0.9% of cases. These findings fall within the rate ranges reported in different studies (Table 4). The wide ranges of ASC-US (1.2-39%) and, to a lesser extent, ASC-H (0.06-2%) may be contributed to the Bethesda system applied for categorization of ASC into ASC-US and ASC-H and further subcategorization of ASC-US into reactive and neoplastic counterparts (NCI Bethesda System, 2001; Solomon et al., 2001; Selvaggi, 2003; Barcelos et al., 2011). In addition, the heterogeneous morphology and lack of well-defined criteria for both ASC-US and ASC-H reflected in their poor interobserver agreement between laboratories or even the variable experience of the microscopists may account for these differences (Saad et al., 2006; Chivukula and Shidham; CytrynI et al., 2009; Tewari and Chaudhary., 2010; Barcelos et al., 2011). The rate of Pap smears could be also influenced by the type of Pap test applied, the age

Table 4. ASC-US and ASC-H Frequencies in Different Series

Series	Sample No.	ASC-US %	Series	Sample No.	ASC-H%
Lee et al, 2006 (Korea)	49,882	2	Selvaggi, 2003 (USA)	9,214	0.27
Tewari et al, 2010 (India)	604	4	Alli et al, 2003 (USA)	241,841	0.6
Barcelos et al, 2011 (Brazil)	46,362	4.93	Bandyopadhyay et al, 2008(USA)	277,400	0.6
Mood, Haratian, 2004 (Iran)	8551	2.76	Srodon et al, 2006 (USA)	30,658	0.31
Michelow et al, 2010 (South Africa)	2,111	19.9	Michelow et al, 2010 (South Africa)	2,111	1.94
Kaygusuz et al, 2011 (Turkey)	37,884	1.2	Kaygusuz et al, 2011 (Turkey)	37,884	0.06
Louro et al, 2003 (USA)	43,840	10.8	Louro et al, 2003 (USA)	43,840	0.84
Saad et al, 2006 (USA)	152,495	7.3	Saad et al, 2006 (USA)	152,495	0.52
Gerber et al, 2001 (Switzerland)	29,827	5	Barreth et al, 2006 (USA)	241,841	0.3
Bansal et al, 2012 (USA)	2,892	38.9	Bansal et al, 2012 (USA)	2,892	1.2
Zhao et al, 2010 (USA)	17489	25.5	Zhao et al, 2010 (USA)	17489	0.9
Manos et al, 1999 (USA)	46,009	3.5	Duncan et al, 2005 (USA)	60,390	0.7
Current (Iraq), 2012	10338	7.8	Current (Iraq), 2012	10338	0.9

Table 5. Frequency Rates of LSIL and HSIL among ASC-US and ASC-H Subjects in Different Series

Series	ASC-US			ASC-H			
	Sample No.	LSIL (%)	HSIL (%)	Series	Sample No.	LSIL(%)	HSIL(%)
Barcelos et al, 2011 (Brazil)	70	11.4	8.6	Barcelos et al, 2011 (Brazil)	8	0	62.6
Solomon, 2001 (USA)	3488	11	5-10	Selvaggi, 2003 (USA)	22	9	68.2
Mood and Haratian, 2004 (Iran)	8551	33.6	3.1	Barreth et al, 2006 (USA)	552	-	65.6
Gerber et al, 2001 (Switzerland)	186	21	9	Chivukula, Shidham, 2006 (USA)	161	27	27
161	27	27					
Manos et al, 1999 (USA)	995	39.5	6.7	Alli et al, 2003 (USA)	257	7	7.4
Bansal et al, 2012 (USA)	1,125	47.1	5.5	Bansal et al, 2012 (USA)	36	48.3	2
Sherman et al, 2001 (USA)	764	-	11.6	Sherman et al, 2001 (USA)	116	-	40.5
CytrynI et al, 2009 (Brazil)	108	-	1.9	CytrynI et al, 2009 (Brazil)	57	-	19.3
ALTS Group, 2003 (USA)	3488	-	8- 9	Michelow et al, 2010 (South Africa)	41	19.2	43.9
Murta et al, 2007 (Brazil)	1,244	60.3	17.5	Louro et al, 2003 (USA)	368	41.6	37.2
Roche, Spicer, 2001 (New Zealand)	278	18	15	Saad et al, 2006 (USA)*	127	36.2	22
				Saad et al, 2006 (USA)**	90	34	6
Zhao et al, 2010 (USA)	4453	-	3.2	Zhao et al, 2010 (USA)	157	-	15
Ghaemmaghami et al, 2005 (Iran)	30	14	16	Duncan et al, 2005 (USA)	414	30.8	46.2
Sherman et al, 2006 (USA)	755	-	17	Sherman et al, 2006 (USA)	113	-	50
Current (Iraq), 2012	596	1.7	0.8	Current (Iraq), 2012	93	5.4	16.1

*Perimenopausal; ** Postmenopausal

Table 6. High- risk HPV positivity among ASC-US and ASC-H in different series

Series	ASC-US		ASC-H		
	Sample No.	HR-HPV %	Series	Sample No.	HR-HPV %
Barcelos et al, 2011 (Brazil)	70	22.5%	Barcelos et al, 2011 (Brazil)	8	62.5%
Solomon, 2001 (USA)	3488	32.7	Chivukula, Shidham, 2006 (USA)	161	64
Saad et al, 2006 (USA)	25	36	Saad et al, 2006 (USA)	39	38
Manos et al, 1999 (USA)	995	39.5	Bandyopadhyay et al, 2008 (USA)	1187	49.6
Bansal et al, 2012 (USA)	1,125	21.7	Bansal et al, 2012 (USA)	36	58
Zhao et al, 2010 (USA)	4453	14.2	Zhao et al, 2010 (USA)	157	38.9
Srodon et al, 2006 (USA)	1079	44.9	Srodon et al, 2006 (USA)	96	66.7
Sherman et al, 2001 (USA)	764	63	Sherman et al, 2001 (USA)	116	86
Youens et al, 2011 (USA)	9151	48.5	Duncan et al, 2005 (USA)	414	73.9
Current (Iraq), 2012	65	10.8	Current (Iraq), 2012	41	31.7

group of the studied patients as well as the population sampled (Chivukula and Shidham, 2006; Saad et al., 2006; Sherman et al., 2006; Bandyopadhyay et al., 2008; Tewari and Chaudhary, 2010; Zhao et al., 2010).

On subsequent follow up, our clinic experienced low overall rates of HSIL among both ASC-US (0.8%) and ASC-H (16.1%) women when compared with other Pap reports (Table 5). It may be argued that our test comparisons were based, not on a single criterion but on many subjective criteria. As well, we did not instruct the physicians to use liquid based cervical brush in addition to

the Ayres spatula every time they obtained the repeat Pap smear, liquid based cytology was not available within the Iraqi public health sector at time of the study. Furthermore, it is of some concern that 136 patients (18% of ASC-US women and 1.7% of ASC-H) had only cytologic sampling without histologic examination, a fact which may reflect a lack of knowledge about the appropriate follow-up of these equivocal Pap tests. However, modest decreases in rates of HSIL biopsy findings among ASC-H are also reported by other investigators (Alli and Ali, 2003; Bansal et al., 2012) suggesting that the diagnostic thresholds and disease

prevalence can be variable, or at least some portions of the rare atypical cells are not really premalignant cells. Saad et al who tracked patients with ASC-H for 18 months, reported higher HSIL rate among perimenopausal women (22%) but much lower rate among postmenopausal women (6%) (Saad et al., 2006) a finding that has been further documented by others (Chivukula and Shidham, 2006; Sherman et al., 2006; Bandyopadhyay et al., 2008; Zhao et al., 2010). Nevertheless, in the present study we experienced a significantly higher LSIL and HSIL rates with higher HSIL: LSIL ratio among ASC-H group than ASC-US. This finding is comparable to other reports (Chivukula and Shidham, 2006; Duncan and Jacob, 2005; Bandyopadhyay et al., 2008; Barcelos et al., 2011).

There is no consensus on the optimal management of women with an ASC-US and ASC-H. It has been anticipated that although the vast majority of these lesions often regress spontaneously and do not require immediate colposcopic examination or aggressive management, considerable percentages might harbor an underlying HSIL, a finding also observed in the current study. These HSIL cases require immediate management (Solomon et al., 2001; Chivukula and Shidham, 2006; Bandyopadhyay et al., 2008; Tewari and Chaudhary, 2010; Barcelos et al., 2011). It is also of clinical interest that in our series, one patients of ASC-H group had a histologic diagnosis of cervical cancer. This emphasizes the potential significance of ASC-H Pap smear owing to its association with an appreciable risk of clinically significant disease, and patients should undergo timely colposcopic and histologic assessment to rule out HSIL, and cervical cancer (Srodone et al., 2005; Barcelos et al., 2011). The ALTS study (ASCUS/LSIL Triage Study), a large randomized trial designed to evaluate different methods for managing patients with cytological findings of low grade squamous lesions, concluded that two repeat cytologic examinations performed at six-month intervals, testing for human papillomavirus (HPV) and a single colposcopic examination are all safe and effective approaches to managing women with ASC-US (ASCUS-LSIL Triage Study (ALTS) Group, 2003; Solomon et al., 2001). The ASCCP (American Society for Colposcopy and Cervical Pathology) recommends that any of the three steps could be taken (Solomon et al., 2001; Sherman et al., 2001). The interim guidelines published by a study done in Iran by Ghaemmaghami et al. and by the National Cancer Institute suggest that patients should be referred for colposcopy after persistent ASC-US diagnosis within 2 years (Ghaemmaghami et al., 2005; NCI Bethesda System, 2001). However, referring all women with minor cytologic lesions for colposcopic exploration and further evaluation means an increase in overdiagnosis and overtreatment, and this may result in substantial costs for the health care system (Solomon et al., 2001; Chivukula and Shidham, 2006; Bandyopadhyay et al., 2008; Tewari and Chaudhary, 2010; Barcelos et al., 2011). Saad et al. (2006), Srodone et al. (2005) and Sherman et al. (2006) suggested that HPV testing may be helpful for selecting patients with ASC-H who should undergo colposcopic examination. The presence of higher rates of CIN II/III among HPV-positive ASC-US in a study done by Barcelos

et al. (2011) in Brazil and among HPV-positive ASC-H group in another study done in US by Srodone et al.' (2005) study suggest that HPV positivity may be associated with an increased probability of CIN among both groups. These studies along with the ASCCP recommend that HR-HPV DNA triage is pertinent to cervical Pap tests for atypical squamous cells (Solomon et al., 2001; NCI Bethesda System; Sherman et al., 2001; Srodone et al., 2005; Sherman et al., 2006; Barcelos et al., 2011). In the present study, we demonstrated positive HR-HPV DNA in 10.8% of ASC-US and 31.7% of ASC-H cases. Variations in HR-HPV DNA association with both ASC-US and ASC-H women have been reported (Table 6). These variations may reflect the significant differences in cytologic interpretation thresholds for ASC-US and ASC-H interpretations (Chivukula and Shidham, 2006; Saad et al., 2006; Bandyopadhyay et al., 2008). HR-HPV rate variation is further contributed to the impact of employing different techniques for HPV DNA identification (de Roda Husman et al., 1995; Jacobs et al., 1997; Sherman et al., 2001; van den Brule et al., 2002; Saad et al., 2006; Bandyopadhyay et al., 2008; Zhao et al., 2010). The use of different ranges of high and low risk HPV DNA tested (de Roda Husman et al., 1995; Jacobs et al., 1997; Srodone et al., 2005; Bandyopadhyay et al., 2008) as well as the Pap smearing applied (Louro et al., 2003; Bandyopadhyay et al., 2008). Another plausible explanation for reported variations might be that different HR-HPV DNA detection rates reflect different demographic population profiles with different HPV prevalence influenced in part by HR-HPV infection rates (Solomon et al., 2001; Sherman et al., 2006; Bandyopadhyay et al., 2008). The information obtained in this study provided an analysis of only 65 (10.9%) of ASC-US and 41 (44.1%) of ASC-H. When the cytologies of ASC-US and ASC-H were compared, the presence of high-risk HPV DNA seemed to be greater among ASC-H group (31.7%) versus 10.8% of ASC-US cases and ASC-H associated SIL lesions were observed to have higher prevalence HR-HPV DNA than their counterpart ASC-US-associated lesions. Although the differences didn't reach the level of significance ($p > 0.05$), subcategorization of ASC into ASC-US and ASC-H seems to be of a great value for detection of clinically significant diseases.

In conclusions, Since both ASC-US and ASC-H identify patients who are at an increased risk for the development of high squamous intraepithelial lesions and a considerable percentage harbor high-risk HPV, both should be retained as diagnostic categories and patients warrant a diligent follow up, and testing for High-risk HPV-DNA, colposcopic evaluation and biopsy when indicated are a must.

References

- Alli PM, Ali SZ (2003). Atypical squamous cells of undetermined significance—rule out high grade squamous intraepithelial lesion: cytopathologic characteristics and clinical correlates. *Diagn Cytopathol*, **28**, 308-12.
- ASCUS-LSIL Triage Study (ALTS) Group (2003). Results of a randomized trial on the management of cytology interpretations of atypical squamous cells of undetermined

- significance. *Am J Obstet Gynecol*, **188**, 1381-2.
- Bandyopadhyay S, Austin M, Dabbs D, Zhao C (2008). Adjunctive human papillomavirus DNA testing is a useful option in some clinical settings for disease risk assessment and triage of females with ASC-H Papanicolaou test results. *Arch Pathol Lab Med*, **132**, 1874-81.
- Bansal M, Li Z, Zhao C (2012). Correlation of histopathologic/cytologic follow-up findings with vaginal ASC-US and ASC-H Papanicolaou test and HPV test results. *American Journal of Clinical Pathology*, **137**, 437-43.
- Barcelos ACM, Michelin MA, Adad SJ, Murta EFC (2011). Atypical squamous cells of undetermined significance: Bethesda classification and association with human papillomavirus. *Infectious Diseases in Obstetrics and Gynecology*, 2011. doi:10.1155/2011/904674.
- Barreth D, Schepansky A, Capstick V, et al (2006). Atypical squamous cells-cannot exclude high-grade squamous intraepithelial lesion (ASC-H): a result not to be ignored. *J Obstet Gynaecol Can*, **28**, 1095-8.
- Chivukula M, Shidham VB (2006). ASC-H in Pap test-definitive categorization of cytomorphological spectrum. *CytoJournal*, **3**, 14.
- Cytryn I A, Russomano FB, de Camargo MJ, et al (2009). Prevalence of cervical intraepithelial neoplasia grades II/III and cervical cancer in patients with cytological diagnosis of atypical squamous cells when high-grade intraepithelial lesions (ASC-H) cannot be ruled out. *Sao Paulo Med J*, **127**, 283-7.
- De Roda Husman A, Walboomers JMM, van den Brule AJC, et al (1995). The use of general primers GP5 and GP6 elongated at their 3' ends with adjacent highly conserved sequences improves human papillomavirus detection by PCR. *Journal of General Virology*, **76**, 1057-62.
- Duncan LD, Jacob SV (2005). Atypical squamous cells, cannot exclude a high-grade squamous intraepithelial lesion: The practice experience of a hospital-based reference laboratory with this new Bethesda system diagnostic category. *Diagnostic Cytopathol*, **32**, 243-6.
- Gerber S, De Grandi P, Petignat P, Mihaescu A (2001). Colposcopic evaluation after a repeat atypical squamous cells of undetermined significance (ASCUS) smear. *Int J Gynaecol Obstet*, **75**, 251-5.
- Ghaemmaghami F, Ensani F, Behtash N, Hosseini-Nejad E (2005). Pap smear with atypical squamous cells of undetermined significance. *Arch Iranian Med*, **8**, 192-6.
- Jacobs MV, Snijders PJ, van den Brule AJ, et al (1997). A general primer GP5+/GP6(+)-mediated PCR-enzyme immunoassay method for rapid detection of 14 high-risk and 6 low-risk human papillomavirus genotypes in cervical scrapings. *J Clin Microbiol*, **35**, 791-5.
- Kaygusuz EI, Çetiner H, Şahin D (2011). LSIL/ASC-H (LSIL-H) in cervicovaginal smear: Histopathological outcomes and clinical significance. *TJPath*, **27**, 45-50.
- Lee SJ, Song SY, Kim BG, Lee Park JH, Bae CS (2006). Analyses of atypical squamous cells refined by the 2001 Bethesda System: the distribution and clinical significance of follow-up management. *Int J Gynecol Can*, **16**, 664-9.
- Louro AP, Roberson J, Eltoun I, Chhieng DC (2003). Atypical squamous cells, cannot exclude high-grade squamous intraepithelial lesion. A Follow-up study of conventional and liquid-based preparations in a high-risk population. *Am J Clin Pathol*, **120**, 392-7.
- Manos MM, Kinney WK, Hurley LB, et al (1999). Identifying women with cervical neoplasia: using human papillomavirus DNA testing for equivocal Papanicolaou results. *JAMA*, **281**, 1605-10.
- Michelow P, Hartman I, Schulze D, et al (2010). Atypical squamous cells, cannot exclude high grade squamous intraepithelial (ASC-H) in HIV-positive women. *Cytojournal*, **7**, 8.
- Mood NI, Haratian A (2004). Atypical squamous cells of undetermined significance: A cytohistologic study. *Acta Medica Iranica*, **42**, 295-9.
- Murta EFC, Silva CS, Vieira JB, Khabbaz KM, Adad SJ (2007). Cervical neoplasia after diagnosis and follow-up of women with atypical squamous cells of undetermined significance. *Clin Exp Obstet Gynecol*, **34**, 219-22.
- NCI Bethesda System 2001 (2001). Bethesda system for reporting results of cervicovaginal cytologic disease. Available at: <http://www.Bethesda2001.cancer.gov>.
- Roche D, Spicer N (2001). The clinical significance of atypical squamous cells of undetermined significance: a laboratory audit of cervical reporting. *N Z Med J*, **114**, 64-6.
- Saad RS, Dabbs DJ, Kordunsky L, et al (2006). Clinical significance of cytologic diagnosis of atypical squamous cells, cannot exclude high grade, in perimenopausal and postmenopausal women. *Am J Clin Pathol*, **126**, 381-8.
- Selvaggi SM (2003). Reporting of atypical squamous cells, cannot exclude a high-grade squamous intraepithelial lesion (ASC-H) on cervical samples: is it significant? *Diagn Cytopathol*, **29**, 38-41.
- Sherman ME, Solomon D, Schiffman M (2001). Qualification of ASCUS a comparison of equivocal LSIL and equivocal HSIL cervical cytology in the ASCUS LSIL Triage Study. *Am J Clin Pathol*, **116**, 386-94.
- Sherman ME, Castle PE, Solomon D (2006). Cervical cytology of atypical squamous cells-cannot exclude high-grade squamous intraepithelial lesion (ASC-H). *Cancer*, **108**, 298-305.
- Solomon D, Schiffman M, Tarone (2001). Comparison of three management strategies for patients with atypical squamous cells of undetermined significance: Baseline results from a randomized trial. *JNCI*, **93**, 293-9.
- Srodon M, Parry DH, Ronnett BM (2005). Atypical squamous cells, cannot exclude high grade squamous intraepithelial lesion: diagnostic performance, human papillomavirus testing and follow up results. *Cancer*, **108**, 32-8.
- Tewari LCR, Chaudhary CA (2010). Atypical Squamous Cells of Undetermined Significance: A Follow up Study. *MJAFI*, **66**, 225-7.
- Van den Brule AJ, Pol R, Franssen-Daalmeijer N, et al (2002). GP5+/6+ PCR followed by reverse line blot analysis enables rapid and high-throughput identification of human papillomavirus genotypes. *J Clin Microbiol*, **40**, 779-87.
- Youens KE, Hosler GA, Washington PJ, Jenevein EP, Murphy KM (2011). Clinical Experience with the Cervista HPV HR Assay. *J Mol Diagn*, **13**, 160-6.
- Zhao C, Zhao S, Heider A, Austin RM (2010). Significance of high-risk human papillomavirus DNA detection in women 50 years and older with squamous cell Papanicolaou test abnormalities. *Archives of Pathology & Laboratory Medicine*, **134**, 1130-5.