

Case report

J Korean Soc Pediatr Nephrol 2012;16:146-149
DOI: <http://dx.doi.org/10.3339/jkspn.2012.16.2.146>

ISSN 1226-5292 (print)
ISSN 2234-4209 (online)

양측성 수신증과 육안적 혈뇨를 보인 위축성 방광염 1례

건국대학교 의과대학 소아과학교실

이민정 · 광병욱 · 송민경 · 정소정 · 김교순

Min Jung Lee, M.D.,
Byung Ok Kwak, M.D.,
Min Kyung Song, M.D.,
Sochung Chung, M.D., Ph.D.,
and Kyo Sun Kim, M.D. Ph.D.

Department of Pediatrics, Konkuk University
School of Medicine, Seoul, Korea

Corresponding Author: Kyo Sun Kim
Department of Pediatrics, Konkuk University
School of Medicine, Seoul, Korea
Tel: 02-2030-7370, Fax: 02-2030-5009
E-mail: kimkyo@kuh.ac.kr

Received: 14 September 2012
Revised: 27 September 2012
Accepted: 10 October 2012

A Case of Cystitis with Bilateral Hydronephrosis Presenting with Gross Hematuria

Gross hematuria is uncommon, and rarely associated with hydronephrosis in healthy children. We describe a 3-year-old boy who complained of gross hematuria and dysuria. He was diagnosed as cystitis with bilateral hydronephrosis, and treated with antibiotics and conservative therapy. Our experience suggests that cystitis with hydronephrosis can occur in healthy children presenting with gross hematuria.

Key words: Cystitis, Hydronephrosis, Hematuria, Children

Introduction

Gross hematuria is uncommon, and mostly associated with benign diseases in healthy children and adolescents. The common etiologies of gross hematuria in children are urinary tract infections, irritation of the meatus or perineum, and traumas [1-4]. Other less common causes include nephrolithiasis, sickle cell disease/trait, coagulopathy, glomerular diseases such as postinfectious glomerulonephritis and IgA nephropathy, malignancies, and drug-induced hemorrhagic cystitis [1]. Cystitis is one of the most common causes of gross hematuria, but rarely combined with hydronephrosis in healthy children. Here we report a case of cystitis with bilateral hydronephrosis presenting with gross hematuria.

Case report

A previously healthy 3-year-old boy visited the outpatient clinic because of terminal gross hematuria and dysuria for 6 days. He had been taking oral antibiotics from a local clinic, but symptoms were not improved.

This is an open-access article distributed under the terms of the Creative Commons Attribution Non-Commercial License (<http://creativecommons.org/licenses/bync/3.0/>) which permits unrestricted non-commercial use, distribution, and reproduction in any medium, provided the original work is properly cited.

There was neither history of recent febrile illnesses nor family history of renal diseases. At the time of admission, body temperature was 36.9°C, pulse rate 100 beats per minute, respiratory rate 24 breaths per minute, and blood pressure 96/51 mmHg. Physical examination revealed no costovertebral angle tenderness and no palpable abdominal mass. Peripheral blood analysis showed Hgb 11.7 g/dL, WBC 4,260/ μ L with 46.3% neutrophils, 45.5% lymphocytes, 5.4% monocytes, 2.6% eosinophils, platelet counts of 80,000/ μ L, CRP 0.13 mg/dL, BUN/Cr 13.3/0.29 mg/dL. Urine analysis showed nitrite positive, protein 2+, blood 3+, WBC 20-29/HPF, RBC

50-99/HPF, pH 6.5 with a specific gravity of 1.005. No pathogen was isolated from blood and urine cultures. Renal ultrasonography showed severe bladder wall thickening and bilateral hydronephrosis associated with pelvocalyceal dilatation, probably due to bladder outlet obstruction or vesicoureteral reflux (VUR) (Fig. 1). Voiding cystourethrogram (VCUG) was performed and it showed severe bladder wall thickening with a shrunken bladder volume. VUR was not observed (Fig. 3). Dysuria and gross hematuria were improved after administration of intravenous antibiotics (ceftriaxone) and behavioral modification such as timed voiding.

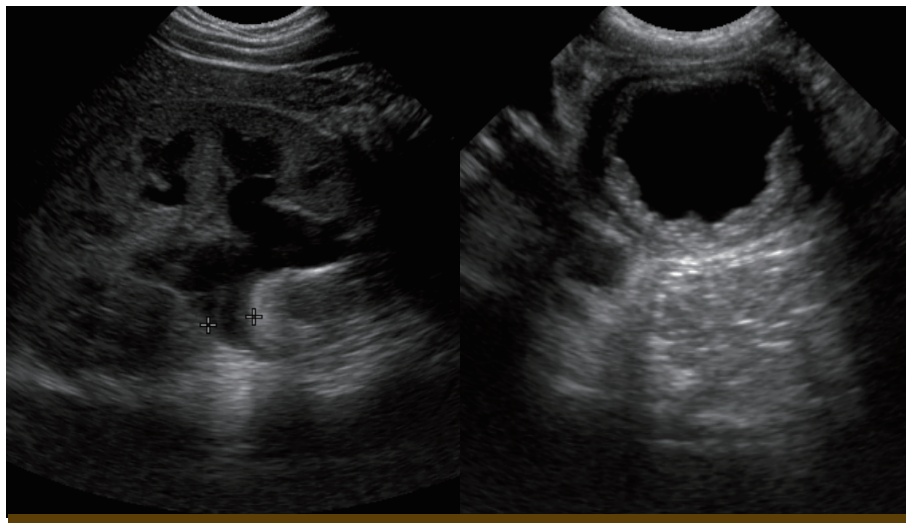


Fig. 1. Renal ultrasonography revealed a hydronephrosis and severe thickened bladder wall.

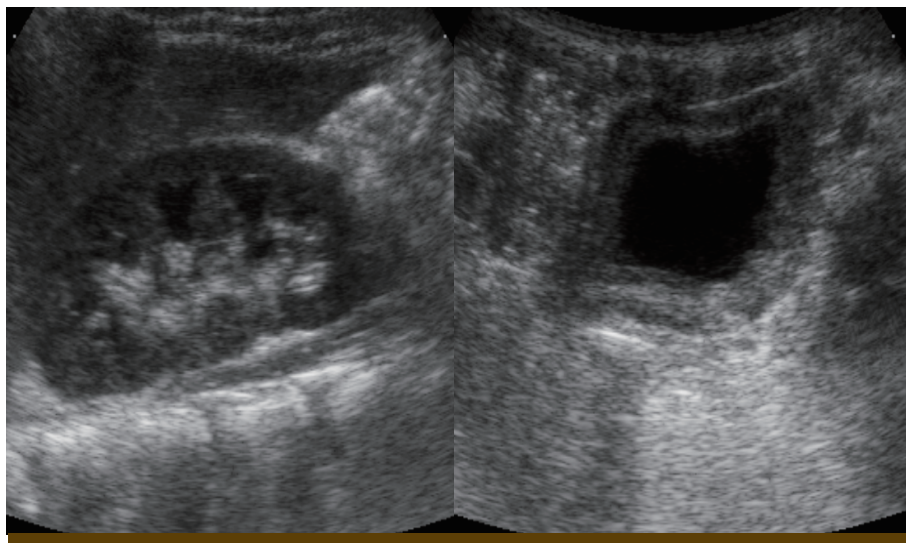


Fig. 2. Renal ultrasonography performed 1 week later showed that the thickened bladder wall was improved, but still remained and the improved hydronephrosis was also observed.

Follow up renal ultrasonography was performed a week after intravenous antibiotics treatment. It showed that bladder wall thickening and bilateral hydronephrosis were improved. And bladder shape and volume were improved. Pelvocalyceal dilatations were not observed (Fig. 2). Follow up urine analysis showed nitrite negative, protein negative, blood negative, WBC <1/HPF, RBC <1/HPF, pH 6.0 with a specific gravity of 1.015, and urine culture was negative. VCUG was performed 1 month later, and normal bladder shape without VUR was observed (Fig. 4). The patient was treated with antibiotics for two weeks and had no additional episodes of gross hematuria during the 1 year follow-up period.

Discussion

Gross hematuria is not common in children, accounting for 1 in 1000 outpatient visits. Urinary tract infections, irritation of the meatus or perineum, trauma, malignancies, and glomerular diseases can cause gross hematuria [1]. Most causes of gross hematuria in children are benign and malignancies account for approximately 1% of the total [4]. Diagnostic studies that

are helpful in children with gross hematuria include renal ultrasonography, which can detect hydronephrosis in severe cases, congenital urologic conditions and malignancies. VCUG is useful in patients with suspicious renal ultrasonography findings, urinary tract infections, or voiding symptoms [4]. Although invasive radiographic modalities or cystoscopy are not always indicated in children because of rarity of malignancies and the accuracy of renal ultrasonography, sometimes they are necessary [5-7]. In our case, we did not perform cystoscopy because cystitis with hydronephrosis was diagnosed on renal ultrasonography, and the symptoms and imaging study findings were improved after antimicrobial treatment. Cystoscopy can be useful for the few patients in whom hematuria persists or those with ambiguous imaging study findings [4].

Urinary tract is a common site for infection in the pediatric population. Cystitis or lower urinary tract infection is an infection confined to the lower urinary tract giving rise to inflammation of the bladder. Cystitis is caused mainly by colonic bacteria. But noninfectious causes of acute cystitis such as systemic disease, radiation therapy, chemicals and medications should be considered in patients who have urinary symptoms and sterile pyuria.

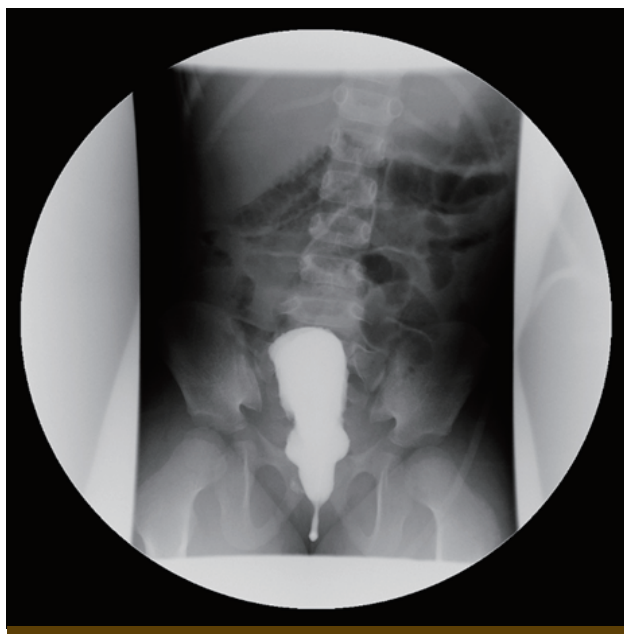


Fig. 3. Voiding cystourethrogram showed severe bladder wall thickening with a shrunken bladder volume.

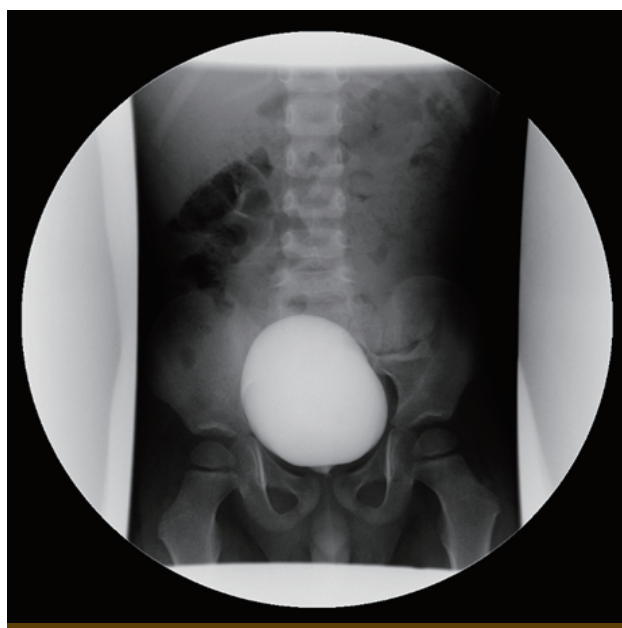


Fig. 4. Voiding cystourethrogram was performed 1 month later, and it showed normal bladder shape.

On microscopy the urothelial lining of the bladder wall is inflamed and shows signs of edema, the presence of inflammatory cells and bacteria adhering to or entering cells, some of which are shed into the urine. Classical symptoms of cystitis are frequency, urgency, dysuria, hematuria, suprapubic pain, residual urine sensation, and incontinence [8].

Bladder capacity is an important factor in the diagnosis and treatment of children with voiding dysfunction. It is defined as the maximum volume of urine voided spontaneously. The bladder volume can be measured via VCUG [9].

Most of cystitis in healthy children rarely accompany with decreased bladder capacity, Chronic bladder pain, dysuria, urgency, hematuria, or reduced bladder capacity can be found in interstitial cystitis/bladder pain syndrome [10]. However in our case, the patient suffered from acute irritable urologic symptoms such as gross hematuria, dysuria, frequency, residual urine sensation and straining to void. The symptoms and thickened bladder wall in renal ultrasonography were suggestive of cystitis. Although no pathogen was isolated in urine cultures, he was treated with antibiotics for two weeks because he had been taking oral antibiotics for 5 days prior to admission and had pyuria in the initial urine analysis. Decreased bladder capacity and gross hematuria were improved after antimicrobial treatment.

In conclusion, although most of cystitis have benign course in healthy children, severe cystitis accompanying with hydronephrosis can occur in patient's complaint of gross hematuria. Therefore it should be considered as a differential diagnosis of gross hematuria. Early diagnosis and appropriate treatment would be required to prevent poor outcome.

한글요약

평소 건강했던 아이들에서 육안적 혈뇨는 드물게 나타나며, 수신증과 동반된 경우 또한 드물다. 3세 남아가 육안적

혈뇨와 배뇨통을 주소로 내원하였다. 소변검사에서 농뇨, 혈뇨 보였으나 소변 배양 검사에서 균이 배양되지 않았으며, 혈액검사와 신체 검진상에서는 특이 소견 관찰되지 않았다. 초음파 검사상 양쪽 수신증과 함께 방광 벽이 두꺼워진 소견 보였다. 배뇨 요도 방광 조영술상 방광 요관 역류는 관찰되지 않았으나 방광 벽 비후가 심했으며, 방광 용적이 줄어들고 모양이 찌그러져있었다. 진단 후 ceftriaxone 을 2주간 치료하였다. 항생제 치료 일주일 후 혈뇨 소실되어 초음파 검사를 다시 시행하였고 양쪽 수신증의 호전과 방광 용적 및 모양이 정상으로 호전됨을 관찰하였다. 환자의 배뇨통 증상도 호전되어 퇴원하였다. 외래 추적 관찰 중에 역류 검사 재 시행하였으며 정상 소견 보였다. 육안적 혈뇨 및 현미경적 혈뇨는 더 이상 관찰되지 않았다. 본 저자들은 육안적 혈뇨를 보인 소아에서 양측성 수신증을 동반한 방광염 1례를 경험하여 보고하는 바이다.

References

- 1) Ingelfinger JR, Davis AE, Grupe WE. Frequency and etiology of gross hematuria in a general pediatric setting. *Pediatrics* 1977;59:557-61.
- 2) Gordon C, Stapleton FB. Hematuria in adolescents. *Adolesc Med Clin* 2005;16:229-3.
- 3) Patel HP, and Bissler JJ: Hematuria in children. *Pediatr Clin North Am* 2001;48:1519-37
- 4) Greenfield SP, Williot P, Kaplan D. Gross hematuria in children: A ten-year review. *Urology* 2007;69:166-9.
- 5) Bagley DH, Allen J. Flexible ureteropyeloscopy in the diagnosis of benign essential hematuria. *J Urol* 1990;143:549-53.
- 6) Wolfish NM, McLaine PN. Idiopathic unilateral gross hematuria in the pediatric patient. *Am J Nephrol* 1985;5:59-62.
- 7) Kumon H, Tsugawa M, Matsumura Y, Ohmori H. Endoscopic diagnosis and treatment of chronic unilateral hematuria of uncertain etiology. *J Urol* 1990;143:554-8.
- 8) Mori R, Lakhanpaul M, Verrier-Jones K. Diagnosis and management of urinary tract infection in children: Summary of NICE guidance. *BMJ* 2007;335:395-7.
- 9) Chung JM, Kim KS, Kim SO, Kim JM, Park S, Park JS, et al. Evaluation of bladder capacity in Korean children younger than 24 months: A nationwide multicenter study. *World J Urol* 2011 DOI 10.1007/S00345-011-0762-4.
- 10) Mattox TF. Interstitial cystitis in adolescents and children: A review. *J Pediatr Adolesc Gynecol* 2004;17:7-11.