

## 피부이식술 후 고식적 봉합붕대법과 실리콘판법의 임상적 고찰

서울마이크로병원 정형외과, 포천우리병원 정형외과\*

박현철 · 박현식 · 안상천 · 조상현 · 김상수 · 장진\*

— Abstract —

### Comparison of Wound Healing Between Conventional Tie-over Dressing and Silicone Sheeting after Skin Grafting

Hyun Chul Park, M.D., Hyun Sik Park, M.D., Sang Cheon Ahn, M.D.,  
Sang Hyun Cho, M.D., Sang Soo Kim, M.D., Jin Chang, M.D.\*

*Department of Orthopaedic Surgery, Microhospital, Seoul, Korea*  
*Department of Orthopaedic Surgery, Woori general hospital, Gyeonggi-do, Korea\**

**Purpose:** We compared wound healing between the conventional tie-over dressing and silicone sheeting after skin grafting in patients with skin defects.

**Materials and Methods:** Of a total of 30 cases of skin defects, 15 underwent conventional tie-over dressing and the remaining 15 underwent silicone sheeting skin grafting, we compared hematoma formation and infection status between the 2 techniques 1 and 2 weeks after operation

**Results:** Hematoma was not observed in all cases. The wound infection rate decreased in silicone group.

**Conclusions:** Silicone sheeting skin graft may be helpful in reducing wound infection.

**Key Words:** Tie-over dressing, Silicone sheeting, Skin grafting

### Introduction

The tie-over dressing is a commonly used operative method for achievement of adequate immobilization by preventing fluid accumulation, hematoma and shearing force after skin grafting<sup>1-3</sup>. This conventional method is very use-

ful for maintaining adequate pressure skin grafts. However, it has the disadvantage of being unable to provide dynamic quality for permitting stretch which is produced by body movement<sup>3</sup>. In other words, in cases of deep wounds, there is the possibility that the failure rate of operation increases due to dead space. In addi-

\*통신저자: 박 현 철

서울특별시 성동구 도선동 365-1

서울마이크로병원 정형외과

Tel: 02-2281-0010, Fax: 02-2281-0878, E-mail: haddal12345@naver.com

tion, since the tie-over dressing is usually removed 1 week after surgery, postoperative infection or hematoma is not detected frequently, subsequently affecting clinical outcomes. Silicone sheeting method is useful to check wound infection and hematoma formation because of the transparency of the silicone.

Therefore, we compared wound healing between the conventional tie-over dressing and silicone sheeting after skin grafting in patients with skin defects.

## Materials and Methods

We reviewed the result of 30 cases(29 patients) treated with skin graft in skin defect between December 2006 and September 2008. 15 underwent conventional tie-over dressing (the conventional group) after skin grafting, defect site was 13 in hand, 1 in forearm, and 1 in shin. The remaining 15 underwent silicone sheeting (the silicone group) after skin grafting, defect site was 12 in hand, 1 in forearm, 1 in upper arm and 1 in shin. The age of the patients ranged between 24 and 82 years. There were 24 male

**Table 1.** The distribution of wounds and clinical results.

Patient	Sex	Age	Diagnosis	Operation method	Site	Size (cm <sup>2</sup> )	Hematoma at 1st week	Infection at 1st week	Hematoma at 2nd week	Infection at 2nd week
1	M	56	Crushing injury	Tie-over	hand	1.21	N	Y	N	Y
2	M	31	Crushing injury	Tie-over	hand	2.20	N	Y	N	N
3	M	37	Crushing injury	Tie-over	hand	0.81	N	Y	N	Y
4	M	35	Crushing injury	Tie-over	hand	1.00	N	Y	N	N
5	M	50	Crushing injury	Tie-over	hand	2.10	N	N	N	N
6	M	24	Crushing injury	Tie-over	hand	0.81	N	Y	N	N
7	M	31	Crushing injury	Tie-over	hand	1.00	N	Y	N	Y
8	M	54	Dog bite	Tie-over	forearm	5.50	N	N	N	N
9	M	58	Crushing injury	Tie-over	hand	3.30	N	Y	N	Y
10	M	34	Crushing injury	Tie-over	hand	1.20	N	Y	N	Y
11	M	53	Crushing injury	Tie-over	hand	1.40	N	Y	N	Y
12	F	50	Crushing injury	Tie-over	hand	1.20	N	Y	N	Y
13	M	46	Crushing injury	Tie-over	hand	1.40	N	Y	N	N
14	F	82	Dog bite	Tie-over	shin	9.00	N	Y	N	N
15	M	47	Crushing injury	Tie-over	hand	1.21	N	N	N	N
16	M	63	Burn	Silicone	forearm	25.00	N	N	N	N
17	M	42	Crushing injury	Silicone	hand	1.40	N	Y	N	N
18	M	30	Crushing injury	Silicone	hand	1.20	N	Y	N	N
19	M	33	Crushing injury	Silicone	hand	1.20	N	Y	N	N
20	M	53	Crushing injury	Silicone	hand	1.00	N	Y	N	Y
21	M	52	Crushing injury	Silicone	hand	4.00	N	Y	N	Y
22	M	40	Crushing injury	Silicone	hand	2.40	N	Y	N	Y
23	M	56	Crushing injury	Silicone	Upper arm	25.00	N	N	N	N
24	F	33	Crushing injury	Silicone	hand	1.00	N	N	N	N
25	M	40	Crushing injury	Silicone	hand	2.40	N	N	N	N
26	M	52	Crushing injury	Silicone	hand	2.20	N	N	N	N
27	M	30	Crushing injury	Silicone	shin	4.40	N	N	N	N
28	F	38	Crushing injury	Silicone	hand	1.20	N	N	N	N
29	F	40	Lack of soft tissue	Silicone	hand	1.10	N	N	N	N
30	F	82	Dog bite	Silicone	hand	6.00	N	N	N	N

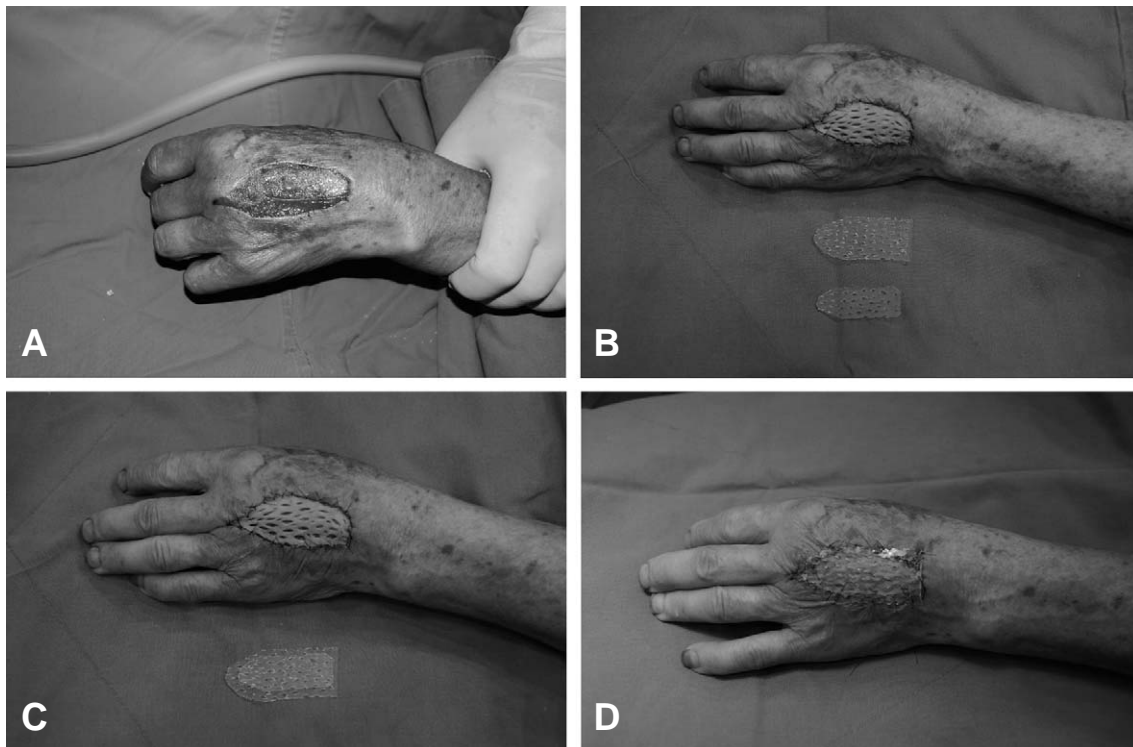
cases(23 male patients) and 6 female cases(6 female patients). Skin defects occurred on the upper arm in 1 case, on the forearm in 2 cases, on the hand in 25 cases and on the lower extremities in 2 cases. The causes of skin defects were crushing injury in 25 cases, dog bite in 3 cases, burn in 1 case and the lack of soft tissue during operation in 1 case (Table 1).

### Surgical procedure

A full-thickness skin graft was harvested from the inguinal area and applied to skin defects on the upper arm (1 case), on the forearm (2 cases) and on the lower extremities (2 cases). In most cases of skin defects adjacent to the distal phalanx, bony fragments and foreign bodies were removed, and the distal part was covered with a finger pulp. Then, a full-thickness skin graft which was harvested from the antecubital fossa was applied to the skin defect. In all cases, only

the dermis was harvested after the elevation of the subcutaneous tissue, and drainage holes were created in it in order to adequately drain blood and serous fluid.

For the conventional tie-over dressing, vaseline gauze was applied on a skin graft, and thick chip gauze without antibiotics made with wide dressing gauze was tied over the skin graft with black silk sutures. The surgical wound was opened by removing tied threads 1 week later. Then, daily wet dressing was done. For silicone sheeting, a skin graft was covered with a silicone sheet after skin grafting was performed in the same manner. But in silicone sheet group, we dressed wound daily using wet dressing. At operation, a silicone sheet was cut to the wound size and fixed on the graft by primary closure(Fig. 1). In cases where dead space occurred due to an excessively deep wound, a multiple-layered silicone sheet was used to prevent dead space, to absorb serous fluid and to



**Fig. 1.** A patient with dog bite who underwent silicone sheeting. To reduce immobilization and hematoma formation, 2 layers of silicone sheet were applied. (A) Before surgery. (B) After skin grafting and before dressing. (C) Application of 2 layers of silicone sheet. (D) Fixation of silicone sheet to the skin graft.

promote wound drainage(Fig. 3). Silicone sheets (BioPlexus, Los Angeles, CA) were used in all cases of silicone sheeting. This silicone sheets was transparent and 1mm thickness. To reduce the surgical time, 2- to 3-mm diameter holes were created in the silicone sheet at 2- to 3-mm intervals and the sheet was sterilized with ethylene oxide gas before a scheduled operation. We compared hematoma formation and infection status between the 2 techniques 1 and 2 weeks after operation.

## Results

All skin graft was survived on defect site. Hematoma was not observed in the conventional group or in the silicone group 1 week after operation. Wound infection occurred in 12 cases(80%) in the conventional group and in 6 cases(40%) in the silicone group 1 week after operation. Hematoma was not observed in the conventional group 2 weeks after operation. Two weeks after operation, a new wound infection occurred in cases where wound infection did not occur 1 week after operation. Of the 12 cases where wound infection occurred 1 week in the conventional group, 5 improved and 7(47%) showed serous discharge and wound infection. These 7 cases were successfully treated at the outpatient clinic without further operations. In the silicone group, 3 of the 6 cases where wound infection occurred 1 week after surgery were successfully treated, 3(20%) showed serous discharge and wound infection 2 weeks after surgery.

Of the 3 showed serous discharge and wound infection, one underwent secondary operation because the bony fragment extruded out of the skin despite an effort to reduce shortening of the middle phalanx of the hand in order to minimize the extent of amputation at the crushed wound. This secondary operation was performed using the aforementioned technique with sufficient removal of bone, and thus hematoma and wound infection did not occur 1 and 2 weeks

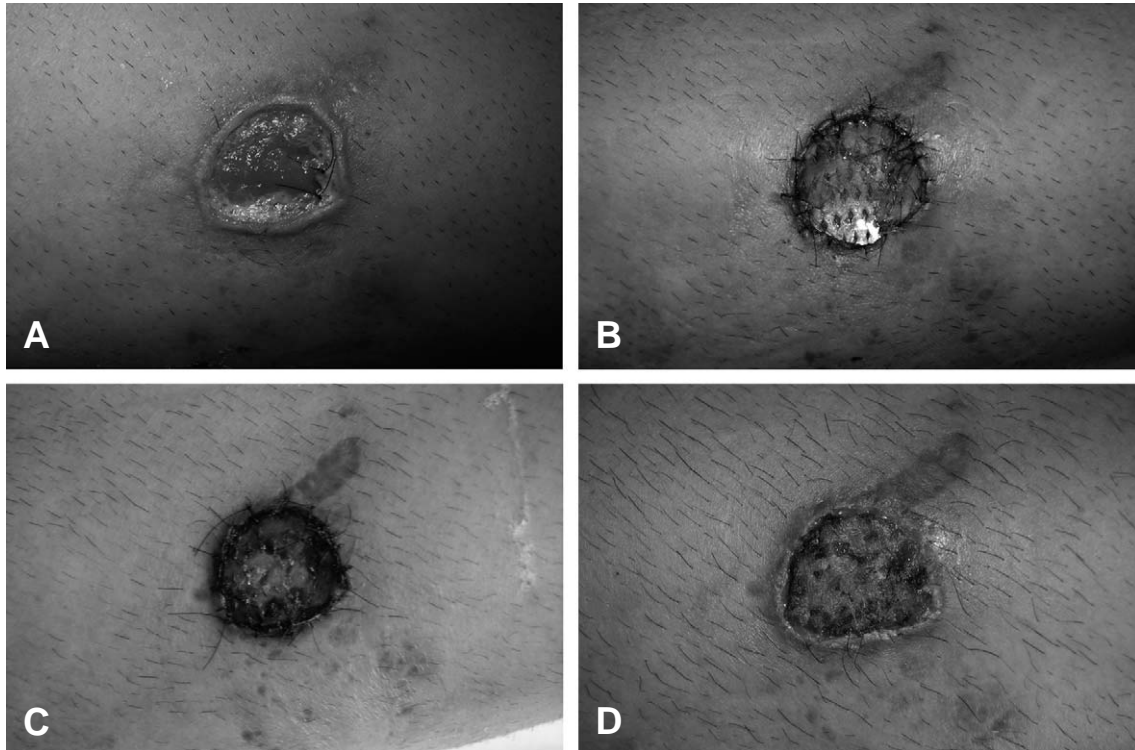
after surgery. Another case had a severe soft tissue defect and a serious injury to the anatomical structures of the palm accompanying flexor tendon ruptures due to crushing injury. This case was also successfully treated at the outpatient clinic without further operations. The third case was successfully treated only using conservative measures. The wound infection rate significantly decreased at the 1-week follow-up ( $p < 0.05$ , independent paired t test). The recovery rate of wound infection was 42% in the conventional group and 50% in the silicone group, but this difference was not statistically significant.

## Discussion


Conventional tie-over dressing has been widely used in clinical practice because it has increased skin graft take, has reduced dead space and has prevented the formation of seroma or hematoma after surgery<sup>1,2,4-6</sup>. Various modifications of this conventional dressing have been reported to have excellent postoperative outcomes<sup>7-10</sup>. Sponge technique is widely used in skin graft fixation, but this technique also is impossible to check the wounds due to its non-transparency<sup>11</sup>.

Rieger et al<sup>12</sup> have shown excellent graft take results by using silicone sheeting at skin defects at the auricle.

In this study, we compared wound healing between the conventional and silicone groups. In the conventional group, we sequentially placed vaseline gauze and wet gauze on the skin graft in order to prevent adhesion between the graft and dressings and then, tie-over suture was performed with nylon or black silk in round, normal saline-soaked chip gauze which was placed on the wet gauze in order to sufficiently absorb serous fluid. In the silicone group, a prepared silicone sheet was cut to the defect size and was then fixed on the skin graft by simple closure to the adjacent skin(Figs. 1 and 3). A silicone sheet is somewhat difficult to apply in a deep wound due to its plate-like shape. However, it can be



**Fig. 2.** A patient with skin defect due to crushing injury. Hematoma or seroma was not observed 1 and 2 weeks after silicone sheeting. (A) Before surgery. (B) 1 week after surgery. (C) 2 weeks after surgery and before removal of stitches. (D) After removal of stitches.



**Fig. 3.** A case of a deep wound. A silicone sheet cut into an inverted-pyramid shape was applied in the concave wound. (A) Application of the multiple-layered sheet with the smallest sheet being directed toward the deepest site. (B) A silicone sheet of inverted-pyramid shape.

efficiently used to stretch a skin graft or to prevent hematoma formation when it is designed in an inverted-pyramid shape and used with a multiple-layered silicone sheet(Fig. 1).

Cheng et al<sup>3</sup> have reported relatively favorable postoperative outcomes by using elastic rubber bands which provides sufficient tension for the skin graft. Pressure on the graft exerted by sili-

cone sheet is weaker than that exerted by elastic rubber bands.

However, we could control the pressure on the graft by creating large drainage holes in the uppermost layer of the silicone sheet.

In the conventional group, the operative wound could be observed 1 week after surgery when tie-over threads were removed, whereas in

the silicone group, the status of the operative wound could be observed whenever a wet dressing was changed, which helped predict patient prognosis. In the conventional group, since the operative wound was observed 1 week after surgery, the status of the wound was indirectly assessed based on pain symptom of the patients or the smell of the wound. However, in the silicone group, the status of the wound could be assessed by the naked eye, and microorganism growth was inhibited by changing wet dressings everyday. This may be the advantage of the rate of wound infection at the 1-week follow-up decreased more in the silicone group. We observed the allergic reactions due to a direct contact with the skin. However, the allergic reactions were not observed in all cases.

This study is subject to several limitations. First, we did not consider the possibility that the severity of a crushing injury influences the rate of wound infection. Second, the status of wound infection was not objectively assessed. Third, although all 30 cases were operated by a single surgeon, patients were not randomly assigned into the 2 groups. Further randomized studies by objective assessment are needed to confirm our results.

### Conclusion

In summary, the silicone sheeting technique used in this study showed postoperative outcomes similar to those of the conventional tie-over dressing in the hematoma formation, whereas the rates of wound infection at the 1- and 2-week follow-ups were lower with the silicone sheeting technique where we changed wet

dressings and observed the status of the wound everyday than in the conventional tie-over dressing. The results of this study suggest that silicone sheeting may be helpful in reducing wound infection in patients with skin defects who undergo skin grafting.

### REFERENCES

1. Pulvermacker B, Chaouat M, Seroussi D, Mimoun M: Tie-over dressings in full-thickness skin grafts. *Dermatol Surg.* 2008; 34: 40-43; discussion 44.
2. Randall P: Extending the use of the tied-on dressing. *Plast Reconstr Surg Transplant Bull.* 1962; 29: 708-9.
3. Cheng LF, Lee JT, Chou TD, et al.: Experience with elastic rubber bands for the tie-over dressing in skin graft. *Burns.* 2006; 32: 212-5.
4. Yoshitatsu S, Takagi T: A new tie-over method improves cosmetic results. *Dermatol Surg.* 2002; 28: 542-3.
5. Qureshi SS, Chaukar D, Dcruz AK: Simple technique of securing intraoral skin grafts. *J Surg Oncol.* 2005; 89: 102-3.
6. Erel E, Sinha M, Nancarrow JD: The 'ull out' tie-over dressing. *J Plast Reconstr Aesthet Surg.* 2008; 61: 460-1.
7. Dogan F, Ozyazgan I, Eskitascoglu T: A new useful and renewable tie-over dressing method using package bands and bra hooks. *Ann Plast Surg.* 2006; 57: 348-9.
8. Ergen D, Tan O, Bayindir O: Tension suture technique for skin graft fixation. A novel alternative to tie-over dressing. *Burns.* 2006; 32: 778-9.
9. Coban YK: A novel tie-over technique for skin graft fixation of circular defects: Star tie-over. *Burns.* 2007; 33: 801-2.
10. Ogawa R, Hyakusoku H, Ono S: Useful tips for successful skin grafting. *J Nippon Med Sch.* 2007; 74: 386-92.
11. De Gado F, Chiummariello S, Monarca C, et al.: Skin grafting: Comparative evaluation of two dressing techniques in selected body areas. *In Vivo.* 2008; 22: 503-8.
12. Rieger UM, Haug M, Pierer G: An alternative to bolus tie-over dressing for full-thickness skin grafts for conchal cavity defects. *Ann Plast Surg.* 2007; 59: 353-4.