

# Primary Laryngeal Aspergillosis in Immunocompetent Patient

## — A Case Report and Review —

Sung Mi Kang, MD<sup>1</sup>, Hyun Jun Hong, MD<sup>1</sup>, Yoon Sung Bae, MD<sup>2</sup> and Sun Och Yoon, MD, PhD<sup>2</sup>

<sup>1</sup>Department of Otorhinolaryngology-Yonsei University College of Medicine; and

<sup>2</sup>Department of Pathology-Yonsei University College of Medicine, Seoul, Korea

Primary laryngeal aspergillosis is rare. It is most often found in immunocompromised patient, such as leukemia, malignant disease, diabetes or immunosuppressive drugs. These days the occurrences of laryngeal aspergillosis in immunocompetent patients are increasing. The cause of laryngeal aspergillosis in immunocompetent patients is not clear, but a few factors are considered such as iatrogenic factors, vocal abuse, vocal fold cyst and occupational factors. The histopathologic characteristics are somewhat different between that of immunocompromised patients and immunocompetent patients. We report a case of primary vocal cord aspergillosis in immunocompetent patient who had treated with only surgery and brief review of the pertinent literature.

**KEY WORDS** : Aspergillosis · Laryngeal aspergillosis · Vocal cord · Hoarseness.

### Introduction

*Aspergillus* is an inherently, non-pathogenic or very weakly pathogenic fungus that produces opportunistic infections.<sup>1)</sup> Laryngeal infection with *Aspergillus* are infrequently encountered. Especially infections in non-immunocompromised hosts are extremely rare. In immunocompetent patients laryngeal aspergillosis may represent colonization rather than invasion requiring no systemic anti-fungal therapy. Recently known etiological causes of the laryngeal aspergillosis in immunocompetent patient are iatrogenic factors, vocal abuse, vocal-fold cyst and occupational factors.<sup>2)</sup>

We present one case of primary vocal cord aspergillosis in immunocompetent patient who had history of vocal abuse.

### Report of a Case

A 28 year-old female patient attended our institution with the chief complaint of hoarseness for several months. She was a singer who had a history of vocal abuse recently because of performance. She had no history of any generalized

immune deficiency such as leukemia, diabetes mellitus or steroid use. She denied alcohol, tobacco abuse or any perivocal laryngeal trauma.

Videostroboscopy revealed a smooth submucosal mass of the mid portion of right true vocal cord. We thought the lesion was consistent with intracordal cyst. Vocal cord mobility was normal bilaterally and a nodular lesion was seen in the counterpart of left true vocal cord (Fig. 1). The remainder head and neck examination was normal. The complete blood count was normal, chest x-ray and HIV test were both negative.

Under the general anesthesia, the patient underwent surgical removal of the lesions. On the surgery, the right vocal cord mucosa was ruptured and yellowish material was excreted. The left vocal cord nodular lesion was removed and sent to pathology department with yellowish material.

Histopathologic examination revealed the necrosis of squamous epithelium containing septate hyphae at a 45° angle, with the hyphae appearing nearly parallel to one another (Fig. 2). This appearance was consistent with *Aspergillus*

One week after surgery, both vocal cords were well healing status and no abnormal lesions (Fig. 3). The patient received no further antifungal therapy.

### Discussion

*Aspergillus* infections occur primarily in immunocompromised patients. Exposure to *Aspergillus* spp. is universal but disease is uncommon. Host factor must be very important. In immunocompromised patients the suppressed host defenses

Received : May 31, 2011

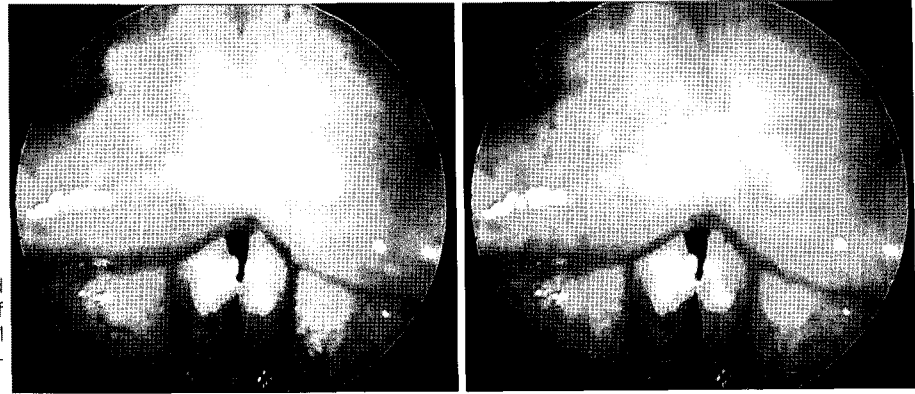
Accepted : June 26, 2011

#### Address for correspondence

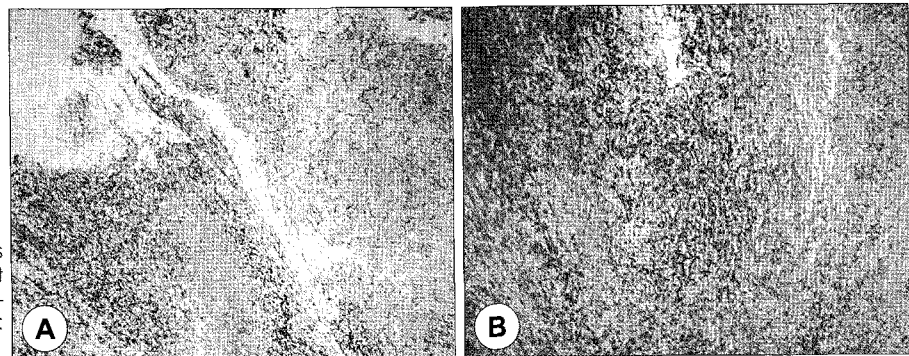
Hyun Jun Hong, MD, Department of Otorhinolaryngology, Yonsei University College of Medicine, Gangnam Severance Hospital, Yonsei University Health System, 211 Eonju-ro, Gangnam-gu, Seoul 135-720, Korea

Tel : +82-2-2019-3460 · Fax : +82-2-3463-4750

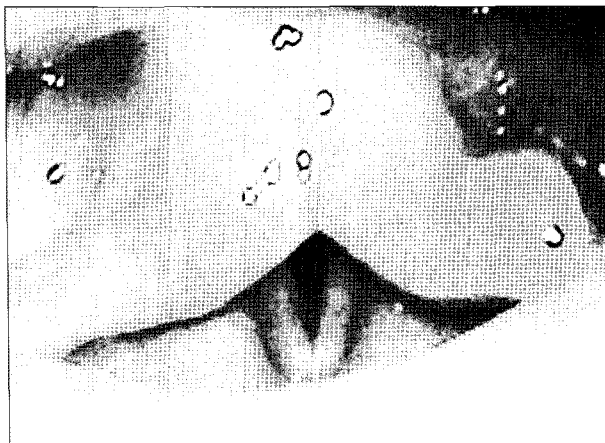
E-mail : hjhong@yuhs.ac



**Fig. 1.** Videostroboscopy revealed that a smooth submucosal mass of the mid portion of right true vocal cord and nodular lesion on the counterpart of left true vocal cord.



**Fig. 2.** Histopathologic features showing septate fungal hyphae at 45° angle which suggests *Aspergillus* infection. A : H&E, ×100. B : H&E, ×400.



**Fig. 3.** Postoperative laryngoscope indicated the mass had disappeared completely and well healing status.

lead to dampening of phagocytosis which is essential in combating fungal infections.<sup>3)</sup>

Infections in immunocompetent patients are rare, but the occurrences of primary laryngeal aspergillosis in immunocompetent patients are increasing.

Most diagnoses of laryngeal aspergillosis were based on the histopathology characteristics.<sup>4)</sup> the pathology of aspergillosis depends on the immune status of the host. In non-immunocompromised patients vascular invasion is not seen and hyphae are sparse. In contrast, in immunocompromised patients vascular invasion is widespread, so infarction, necrosis,

edema, hemorrhage is common and hyphae are abundant.<sup>3)</sup>

The causes of laryngeal aspergillosis in immunocompetent patient are unclear because few cases have been reported. By this time, several predisposing factors -are considered.

Iatrogenic factors such as radiotherapy, steroid inhaler use and laser treatment are more likely to be associated with the onset of localized aspergillosis than decrease immunity.<sup>5)</sup>

Vocal abuse may impair the local mucosal protective barrier and allow colonization of aspergillosis. The patient of our case had a history of vocal abuse.

Laryngeal aspergillosis can occur in a true vocal fold cyst. The relationship between the cyst and *Aspergillus* is not clear.

Occupation like farmer may be an etiological factor because of *Aspergillus* lives in soil.<sup>2)</sup>

Management of primary laryngeal aspergillosis had included systemic administration of Amphotericin B and /or itraconazol, fluconazole, cauterization of the lesion with CO2 laser, or resection of the infected lesion. Noninvasive aspergillosis needs no systemic treatment.<sup>6-8)</sup> So our patient was treated with local removal of laryngeal lesion. It was sufficient treatment in our case.<sup>3)</sup>

Primary laryngeal aspergillosis is extremely rare. But in absence of generalized immune suppression, laryngeal aspergillosis can be occur associated with the predisposing factor such as vocal abuse, iatrogenic factors, vocal fold cyst and

occupational factors. So aspergillosis should be considered in the differential diagnosis of hoarseness.

#### REFERENCES

- 1) MaAlester G, O’Gara, F&Morrissy JP. *Signal-mediated interactions between Pseudomonas aeruginosa and Candida albicans. J Med Microbiol* 2008;57:563-9.
- 2) Young-Cai Liu, Shui-Hong Zhou, Ling Ling. *Aetiological factors contributing to the developemnt of primary laryngeal aspergillosis in immunocompetent patients. J Med Microbiol* 2010;59:1250-3.
- 3) Benson-Mitchell R, Tolley N, Croft C, B&Gallimore A. *Aspergillosis of the larynx. J Laryngol and Otol* 1994;108:883-5.
- 4) Yuping Ran, Baiyan Yang, Suling Liu, Yaling Dai, Zongguo Pang, Jiayu Fan, et al. *Primary vocal cord aspergillosis fumigates and molecular identification of the isolate. Med Mycol* 2008;46:475-9.
- 5) Fairfax A, David V, Douce G. *Laryngeal aspergillosis following high dose inhaled fluticasone therapy for asthma. Thorax* 1999; 54:860-1.
- 6) Richardson BE, Morrison VA, Gapany M. *Invasive aspergillosis of the larynx: case report and review of the literature. Otolaryngol Head Neck Surg* 1996;114:471-3.
- 7) Kuo PH, Lee LN, Yanh PC, Chen YC, Luh KT, Nakatani H. *Aspergillus laryngotracheobronchitis presenting as stridor in a patient with peripheral T cell lymphoma. Thorax* 1996;51:869-970.
- 8) Dean CM, Hawkshaw M, Sataloff RT. *Laryngeal aspergillosis. Ear Nose Throat J* 2001;80:300.