

Case Report

Intraosseous Hemangioblastoma Mimicking Spinal Metastasis in the Patient with Renal Cell Carcinoma

Heecheol Cho, M.D., Sun-Ho Lee, M.D., Eun-Sang Kim, M.D., Ph.D., Whan Eoh, M.D., Ph.D.

Department of Neurosurgery Samsung Medical Center, Sungkyunkwan University, School of Medicine, Seoul, Korea

Sporadic osseous hemangioblastomas in the vertebra are extremely rare and they can be misdiagnosed as a vertebral hemangioma or metastasis in imaging studies. We report an intraosseous hemangioblastoma that arose from the T11 thoracic vertebra and was diagnosed initially as a metastasis in a patient with renal cell carcinoma. Diagnosis, surgical treatment and adjuvant radiosurgery of such case in reference to the literature are discussed.

Key Words : Hemangioblastoma · Bone neoplasm · Vertebra · Radiosurgery.

INTRODUCTION

Hemangioblastomas are benign hypervascular neoplasms, which are primarily tumors of the central nervous system. These tumors can occur sporadically or may constitute the most common and characteristic manifestation of von Hippel-Lindau (VHL) disease⁶. Although hemangioblastomas are normally located in the cerebellar hemispheres, they can also occur as isolated and intramedullary tumors in the spinal cord⁴. They rarely occur extradurally in a paraspinal location³. However, sporadic intraosseous hemangioblastomas in the vertebra are extremely rare. We report a case of sporadic osseous hemangioblastoma that grossly originated from the thoracic vertebra and was diagnosed initially as a metastasis in a patient with renal cell carcinoma.

CASE REPORT

A 55-year-old man was admitted to our department with a one year history of low back pain. He complained of recently aggravated severe back pain. His prior history revealed a left radical nephrectomy performed one year earlier in another hospital due to renal cell carcinoma. The physical examination demonstrated paraparesis grading 4/5 and impaired sensation below T12 dermatome to pin-prick sensory testing. The anteroposte-

rior and lateral X-rays revealed an infiltrative lesion at T11. A loss of height and bony destruction as well as focal lucency in the vertebral body was observed. Computed tomography (CT) showed a pathologic fracture with the trabecular and cortical destruction of the T11 vertebral body with involvement of both pedicles (Fig. 1A, B). Magnetic resonance imaging (MRI) revealed a heterogeneously enhancing mass in the T11 vertebra with extension to both pedicles and posterior arch. In addition, compression of spinal cord by vertebral collapse and contour bulging were also observed (Fig. 1C, D). Surgery was planned as it was considered to be a metastasis of renal cell carcinoma. Preoperative embolization of the feeders was performed with 2cc of Onyx-18 (Onyx Liquid Embolic System, ev3, Irvine, CA) and a Guglielmi detachable coil (Boston Scientific Neurovascular, Fremont, CA). The T11 segmental arteries of both sides were obliterated completely but the right T10 segmental artery was saved because an anterior spinal artery was shown to be originated from it (Fig. 2). After embolization, transpedicular decompression of T11 and pedicle screws fixation were performed from T9 to L1 except T11. Despite the preoperative embolization, a tumor observed in the vertebral canal and T11 body had a purple color with high vascularity but no attachment to the dura. A subtotal resection of the neoplasm around the cord was achieved, even though the tumor of the body had been excised partially because of massive bleeding. The patient had an uneventful recovery after surgery. There were no intraoperative or perioperative complications. His back pain and weakness were resolved and there were no neurological deficit postoperatively.

The histopathology examination revealed a rich plexus composed of mildly pleomorphic endothelial cells separated by

• Received : July 14, 2010 • Revised : December 13, 2010
• Accepted : May 30, 2011
• Address for reprints : Sun-Ho Lee, M.D.
Department of Neurosurgery, Samsung Medical Center, Sungkyunkwan University, School of Medicine, 50 Irwon-dong, Gangnam-gu, Seoul 135-710, Korea
Tel : +82-2-3410-3496, Fax : +82-2-3410-0048
E-mail : sobotta72@hotmail.com

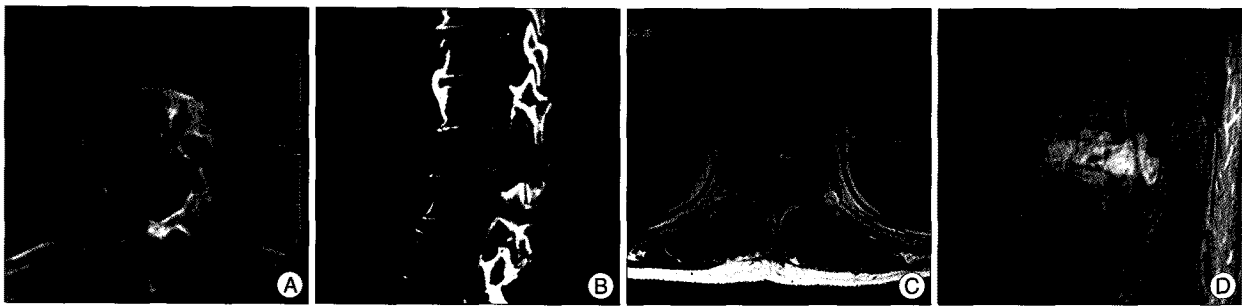


Fig. 1. A : Axial and B : Sagittal reconstruction computed tomography (CT) scan demonstrate osteolytic lesion. The T11 vertebral body is collapsed and shows a pathologic fracture with trabecular and cortical destruction with involvement of both pedicles. C : The axial contrast-enhanced T1-weighted Magnetic resonance (MR) imaging showing multiple serpentine intralesional flow-voids. D : sagittal contrast-enhanced T1-weighted MR imaging demonstrating anterior and posterior bony involvement compresses the spinal cord at T11.

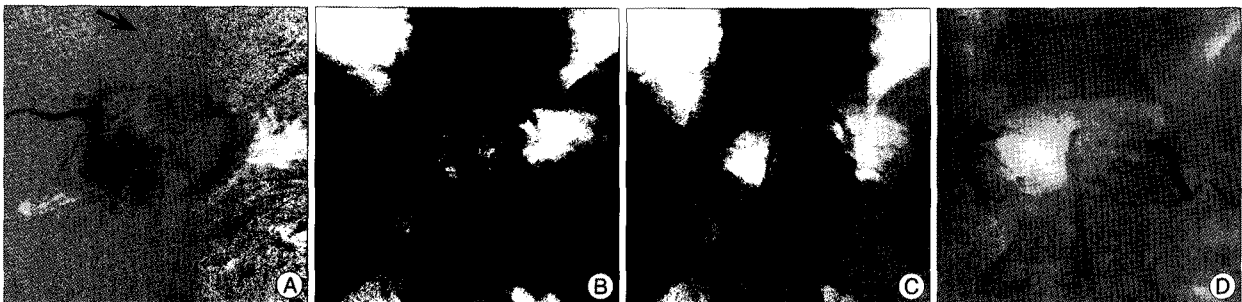


Fig. 2. A, B and C : A pre-embolization angiogram showing the hypervascularity of the tumor and the feeding vessels from the right T10, both T11 intercostal arteries, respectively. Anterior spinal artery arises from the right T10 segmental artery (arrow). D : A postembolization angiogram showing successful tumor devascularization from both T11 intercostal arteries.

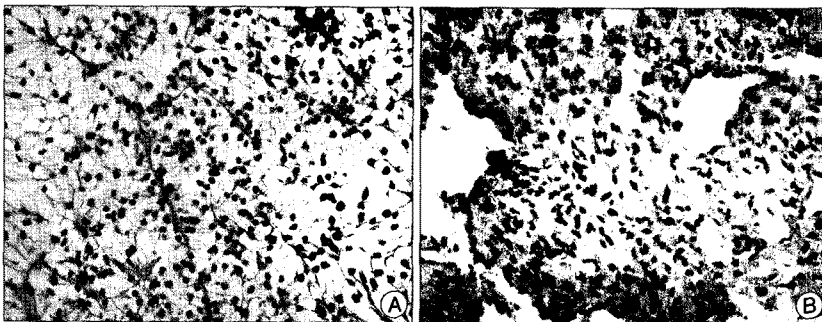


Fig. 3. Histological photographs of the tumor. A : Pleomorphic endothelial cells and neoplastic stromal cells with vacuolated or foamy cytoplasm, which is the typical appearance of hemangioblastomas. (H&E $\times 200$). B : No immunoreactivity is seen in CD10, which is positive staining in renal cell carcinoma.

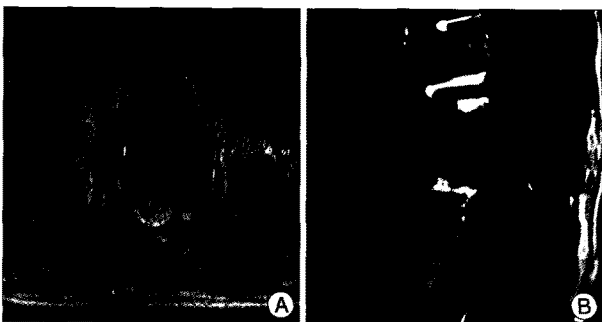


Fig. 4. Follow up magnetic resonance (MR) imaging 2 years after surgery. A : The axial T2-weighted and B : sagittal contrast-enhanced T1-weighted MR imaging demonstrates significant diminution of the epidural and vertebral mass.

neoplastic stromal cells with foamy cytoplasm (Fig. 3). These findings were most consistent with a diagnosis of a hemangioblastoma. A complete workup of VHL disease including brain MRI, chest and abdominal CT, fundoscopy and polymerase chain reaction (PCR)-sequencing to test for VHL gene mutations did not reveal any evidence related to VHL disease. Consequently, stereotactic radiosurgery using a Novalis shaped beam radiosurgery system (Brain LAB, Heimstetten, Germany) was performed for the residual vertebral masses. There

were no complications resulting from radiosurgery. Two year after surgery, there were no signs of recurrence at the last follow-up (Fig. 4).

DISCUSSION

A hemangioblastoma is the most common primary adult intraaxial posterior fossa tumor¹⁾. The second most common location is the spinal cord, where the frequency ranges from 2-3% of primary spinal cord neoplasms to 7-11% of spinal cord tumors⁷⁾. However, purely intraosseous hemangioblastomas of the spine are extremely rare. The present case differed from the extradural spinal hemangioblastomas previously reported, which

were all independent of the bone and dura³). Many extradural spinal hemangioblastomas extended along the spinal roots into an intervertebral foramen and a few cases presented as a unilateral extraspinal mass. The bone changes due to the tumors consisted of pressure erosions of the lamina, pedicle or body

The imaging characteristics are quite similar to those of vertebral hemangiomas and many lesions of this type are simply followed up without treatment. Even though some haemangiomas may lead to cord compression, the radiological features in our case were different from these of hemangioma. Extensive involvement of the pedicle without involvement of the entire vertebral body and involvement of an adjacent vertebra would be unusual in compressive vertebral hemangiomas^{2,10}). The features that would have been unusual in a vertebral hemangioma were the involvement of two adjacent vertebrae and the presence of a blood supply derived in part from the anterior spinal artery.

The natural history and treatment of an osseous hemangioblastoma have not been clarified. The true prevalence of osseous hemangioblastomas remains unknown. Some authors reported that continued observation may be possible for long intervals in asymptomatic localization because hemangioblastomas exhibit a stuttering growth pattern and are frequently asymptomatic^{5,11}). However, a microsurgical resection remains the treatment of choice for the majority of symptomatic and sporadic hemangioblastomas of the spinal cord. Two previously reported cases were treated by decompression rather than by a total excision. In the other case, Steinmetz et al.⁹) suggested a complete spondylectomy suggesting that a gross total resection for hemangioblastomas should be attempted, when possible, because osseous hemangioblastomas appear to be benign lesions. However, when a complete resection is impossible, as in other areas of the central nervous system, radiotherapy should be reserved for subtotal removal or after tumor recurrence, even though it is unknown if adjunctive radiotherapy is suitable after a subtotal resection of an osseous hemangioblastoma.

Smalley et al.⁸) treated 27 hemangioblastoma of the central nervous system with fractionated radiotherapy after incomplete surgical removal. Kano et al.⁵) reported the progression-free survival after stereotactic radiosurgery for all hemangioblastomas. They concluded that radiotherapy is an important tool in the management of hemangioblastomas and is associated with a high tumor control rate and low risk of adverse radiation effects. Considering these reports, radiotherapy might be a alter-

native treatment in cases with an incomplete resection of an intraosseous hemangioblastoma.

In conclusion, osseous hemangioblastomas in the vertebra are extremely rare. They can be misdiagnosed as a vertebral hemangioma or metastasis in imaging studies. Additionally, radiotherapy followed subtotal removal might be a proper treatment modality when complete resection of symptomatic osseous hemangioblastomas is impossible.

• Acknowledgements

The authors thank Moon-Jun Sohn M.D., Ph.D. and Novalis Radiosurgery Center of Ilsan Paik Hospital for their care in this patient.

References

1. Constans JP, Meder F, Maiuri F, Donzelli R, Spaziante R, de Divitiis E : Posterior fossa hemangioblastomas. *Surg Neurol* 25 : 269-275, 1986
2. Higgins JN, Lammie GA, Savy LE, Taylor WJ, Stevens JM : Intraosseous vertebral haemangioblastoma : MRI. *Neuroradiology* 38 Suppl 1 : S107-S110, 1996
3. Hurth M : [Intraspinal hemangioblastomas.] *Neurochirurgie* 21 Suppl 1 : 1-136, 1975
4. Kaffenberger DA, Shah CP, Murtagh FR, Wilson C, Silbiger ML : MR imaging of spinal cord hemangioblastoma associated with syringomyelia. *J Comput Assist Tomogr* 12 : 495-498, 1988
5. Kano H, Niranjana A, Mongia S, Kondziolka D, Flickinger JC, Lunsford LD : The role of stereotactic radiosurgery for intracranial hemangioblastomas. *Neurosurgery* 63 : 443-450; discussion 450-451, 2008
6. Lonser RR, Glenn GM, Walther M, Chew EY, Libutti SK, Linehan WM, et al. : von Hippel-Lindau disease. *Lancet* 361 : 2059-2067, 2003
7. Roonprapunt C, Silvera VM, Setton A, Freed D, Epstein FJ, Jallo GI : Surgical management of isolated hemangioblastomas of the spinal cord. *Neurosurgery* 49 : 321-327; discussion 327-328, 2001
8. Smalley SR, Schomberg PJ, Earle JD, Laws ER Jr, Scheithauer BW, O'Fallon JR : Radiotherapeutic considerations in the treatment of hemangioblastomas of the central nervous system. *Int J Radiat Oncol Biol Phys* 18 : 1165-1171, 1990
9. Steinmetz MP, Claybrooks R, Krishnaney A, Prayson RA, Benzel EC : Surgical management of osseous hemangioblastoma of the thoracic spine : technical case report. *Neurosurgery* 57 : E405; discussion E405, 2005
10. Stevens J, Love S, Davis C, Kendall BE : Capillary haemangioblastoma of bone resembling a vertebral haemangioma. *Br J Radiol* 56 : 571-575, 1983
11. Wanebo JE, Lonser RR, Glenn GM, Oldfield EH : The natural history of hemangioblastomas of the central nervous system in patients with von Hippel-Lindau disease. *J Neurosurg* 98 : 82-94, 2003