

## Case Report

# Angiographically Occult Vascular Malformation of the Cauda Equina Presenting Massive Spinal Subdural and Subarachnoid Hematoma

Ji-Hyun Kim, M.D., Sun-Ho Lee, M.D., Eun-Sang Kim, M.D., Ph.D., Whan Eoh, M.D., Ph.D.

Department of Neurosurgery Samsung Medical Center, Sungkyunkwan University, School of Medicine, Seoul, Korea

We report a case of a non traumatic spinal subdural hematoma or subarachnoid hematoma manifesting as lumbago, leg pain and bladder dysfunction that showed angiographically occult vascular malformation (AOVM). Although the spinal angiogram did not reveal any vascular abnormality, the follow-up magnetic resonance image showed AOVM. Complete surgical removal was performed due to the aggravated bladder dysfunction. This case highlights the need to consider bleeding due to spinal AOVM, even when angiography is negative.

**Key Words :** Spinal · Subarachnoid hemorrhage · Subdural hematoma · Vascular malformations.

## INTRODUCTION

Spinal subdural hematoma (SSDH) or subarachnoid hematoma (SSAH) is a rare entity that causes spinal cord or nerve root compression and is usually managed as a surgical emergency. The condition may present after major or minor trauma, or following lumbar puncture. It can also occur spontaneously in patients with coagulation abnormalities, underlying neoplasm or arteriovenous malformation (AVM)<sup>7</sup>. In particular, vascular malformations not visible on an angiogram are called angiographically occult vascular malformations (AOVM). Cavernous malformations are the most common type of AOVM, whereas non-cavernous AOVM of the spinal cord are quite rare<sup>2,12</sup>.

We report a case of non-traumatic SSDH and SSAH with a lower thoracic intradural extramedullary AOVM presenting as sudden onset painful leg weakness with a bladder dysfunction<sup>1,7,8</sup>. The discussion focuses on the clinical presentation, image findings and therapeutic features.

## CASE REPORT

A 59-year-old woman suffered from a sudden onset of low

back pain, left leg pain and headache with left leg weakness. She had no history of trauma, physical exertion, or anticoagulant therapy. The routine blood investigations were normal. A neurological examination revealed grade III/V and IV/V motor weakness in the proximal and distal left leg, respectively. There were no sensory abnormalities including touch, pain and vibration. Deep tendon reflexes were decreased at the left leg and no Babinski signs were noted. She had bladder retention, but the anal sphincter tone was intact. Magnetic resonance (MR) imaging revealed an area of slightly high signal intensity on the T1-weighted image and a low signal area on the T2-weighted image from T7 to S1, suggesting an acute SSDH and/or SSAH (Fig. 1A, B, C). MR imaging did not show any evidence of vascular abnormalities within the lesion levels.

Surgical removal of the hematoma was delayed because the motor weakness, leg pain and bladder retention had improved spontaneously one day after admission. However, the bladder retention relapsed 6 days after admission. She could not initiate the voiding and residual urine was 500-850 mL. The follow up MR imaging obtained on the same day showed no evidence of rebleeding but a 1 cm diameter-sized intradural extramedullary round mass between the T12 and L1 levels (Fig. 1D, E, F). Subsequent spinal angiography was performed but no vascular abnormality was revealed. A laminectomy from T12 to L1 was performed to surgically remove the hematoma and mass lesion. After the SSDH and SSAH had been removed completely, a 1.0×0.8 cm, dark-bluish mass was found. The mass had a feeding artery and a draining vein but no adhesions to the nerve roots, dura, or spinal cord (Fig. 2). The mass was excised com-

• Received : September 29, 2010 • Revised : December 1, 2010  
• Accepted : May 30, 2011  
• Address for reprints : Sun-Ho Lee, M.D.  
Department of Neurosurgery, Samsung Medical center, Sungkyunkwan University, School of medicine, 50 Irwon-dong, Gangnam-gu, Seoul 135-710, Korea  
Tel : +82-2-3410-3491, Fax : +82-2-3410-0048  
E-mail : sobotta72@hotmail.com

pletely (Video). The postoperative bladder retention and left leg pain had resolved completely. The histopathological examination revealed hemorrhagic necrosis of the vascular wall and mainly fibrinoid material with hemorrhage, but there were no features of cavernous malformations (Fig. 3).

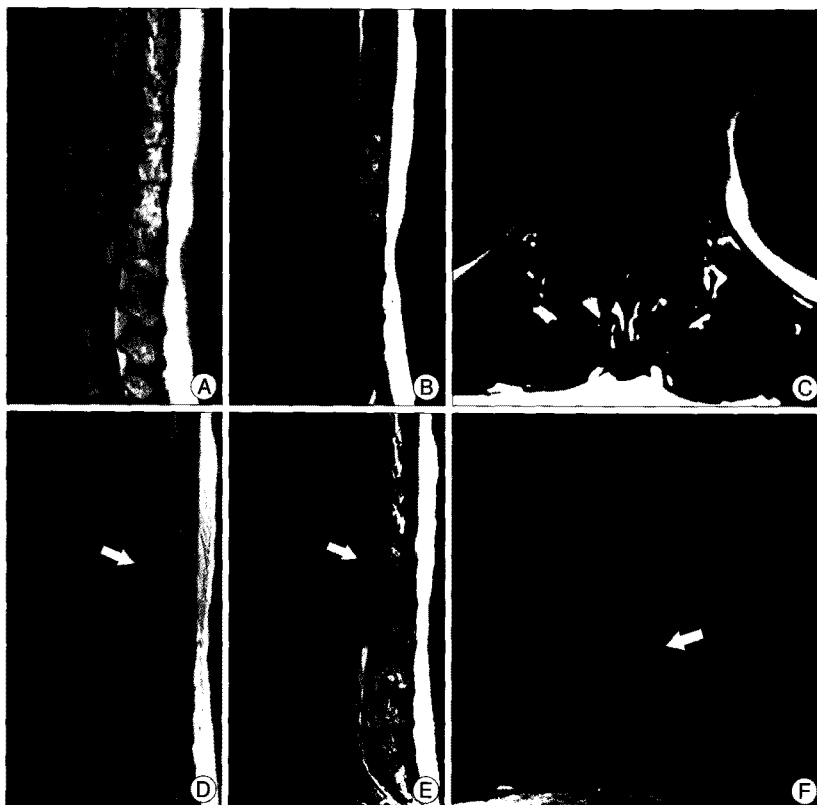Ten days after surgery, the bladder retention had relapsed again. She had no sensation of bladder fullness. The MR imaging suggested a remaining chronic subdural hematoma. Because the symptoms had not improved despite steroid treatment and successful draining of the hematoma by lumbar tapping, she un-

derwent an exploration. The surgical finding revealed only a small hematoma but severe adhesion between the arachnoid membrane and cauda equina. After removing the adhesion, the patient recovered without pain, weakness and any sphincter dysfunction. At the 6 month follow-up, the patient was asymptomatic. MR imaging revealed no vascular abnormality and resolution of the hematoma (Fig. 4).


### DISCUSSION

Acute SSDH and SSAH are rare disorders causing compression of the spinal cord, cauda equina and nerve root. Unlike the intracranial subdural space, the spinal subdural space is an avascular space, and the subdural hemorrhage may originate in the more vascular subarachnoid space and pass through the rents of the thin and delicate arachnoid membrane<sup>5,9,11</sup>. Some authors reported cases of simultaneous SSAH and SSDH, which support the theory that spontaneous SSDH might originate in the subarachnoid space, dissect the arachnoid membrane and spread into the subdural space<sup>10</sup>.

MR imaging best shows the extent of the hemorrhage and delineation from the epidural space. Differentiating between a subdural and subarachnoid hematoma is difficult, and in some cases, only surgical exploration will demonstrate the precise location of the hematoma. However, pure SSAH as in this case can be easily differentiated from the subdural hematoma. SSAHs are located within the thecal sac without an inverted "Mercedes star sign", which is a typical finding in subdural hematoma<sup>4</sup>. MR imaging also can demonstrate a



**Fig. 1.** The initial magnetic resonance (MR) image shows (A) a heterogeneous, slightly hyper-intense abnormal signal in the spinal canal on the sagittal T1-weighted image and (B) a low signal on the sagittal T2-weighted image. The axial T2-weighted images (C) demonstrate the subdural location of the hematoma in the dural sac. Follow up MR image (D, E, and F) shows a nodular mass (arrow) between the T12 and L1 level. The lesion is iso-intense to the spinal cord on the T1-weighted imaging and slightly hypointense to the spinal cord on the T2-weighted image but had no vascular flow voiding.



**Fig. 2.** Intraoperative photographs : (A) Once the subdural hematoma had been evacuated, the arachnoid membrane is found to be bluish in color with a tendency to bulge. (B) Dark-bluish mass measuring 1.0×0.8 cm is found, with a feeding and draining vessel (arrow), but no adhesions to the nerve roots, dura and spinal cord. (C) The excised mass is brownish red soft tissue with vessel stumps.

better underlying cause of the hematoma and can identify any alternate causes of the clinical features, such as tumors and vascular malformations<sup>5,9,11</sup>. AVMs are best demonstrated on the gradient echo sequences. In the absence of any features suggestive of a spinal vascular lesion on MR imaging, spinal angiography is the best modality for identifying vascular malformations. In addition, spinal angiography can define the feeding vessels, collateral supply, normal spinal vascular anatomy and venous drainage of lesions discovered by MR imaging<sup>6</sup>.

In the present case, an intradural extramedullary mass was found between the T12 and L1 levels but extensive spinal angiography did not reveal any vascular abnormalities. Several explanations have been proposed for the failure of angiography to depict vascular malformations in the brain : 1) small size, 2) separation from the main vascular supply, 3) compression by an adjacent clot, or 4) destruction caused by hemorrhage and thrombus<sup>3,12</sup>. The slow blood flow or hypercoagulable state can cause thrombosis in vascular malformations<sup>2,3</sup>. It is believed that its small size and compression by an adjacent massive hematoma are the most likely reasons for why it was not recognized by spinal angiography.


There are several reports of the spontaneous resolution of neurological deficits in those who had mild neurological symptoms or rapid improvement in disable symptoms during the clinical course<sup>7,13</sup>. Most of those patients showed clinical improvement at least 2 days after the onset of symptoms. The precise mechanism for the spontaneous resolution of symptoms is unclear<sup>13</sup>. The prognosis is variable and the precipitating factors are still speculative. The patients usually demonstrate slow but good neurological recovery. Although there are several case reports of SSAH with spontaneous resolution, the urgent decompressive surgery has been primary treatment for SSAH in case of which the neurological state deteriorates progressively<sup>8,11</sup>. In the present case, surgical removal of the hematoma was delayed because of rapid resolution of neurological deficit. But, urgent surgical hematoma removal was performed when the neurological symptoms relapsed and deteriorated progressively, follow up MR imaging revealed the intradural extramedullary mass.

## CONCLUSION

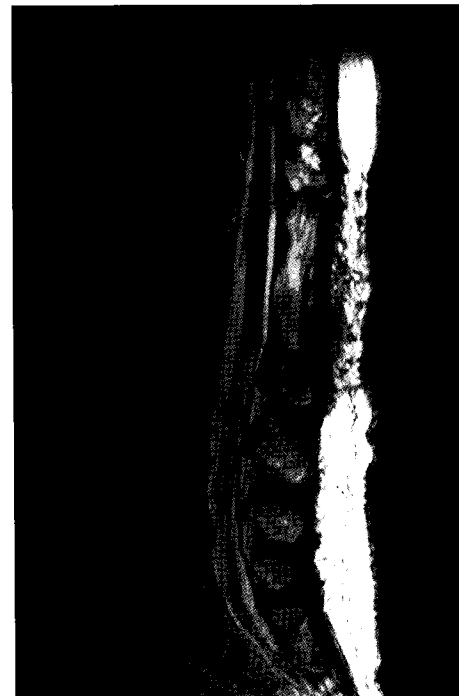We report that spinal intradural extramedullary AOVMs show spontaneous SSDH and SSAH. This case suggests that bleeding due to spinal AOVM should be considered, even when angiography result is negative. Complete surgical removal, if possible, should be considered for symptomatic patients with AOVMs.

## References

1. Cincu R, de Asis Lorente E, Rivero D, Eiras J, Ara JR : Spontaneous subdural hematoma of the thoracolumbar region with massive recurrent bleed. *Indian J Orthop* 43 : 412-415, 2009
2. Furuya K, Sasaki T, Suzuki I, Kim P, Saito N, Kirino T : Intramedullary angiographically occult vascular malformations of the spinal cord. *Neurosurgery* 39 : 1123-1130; discussion 1131-1132, 1996



**Fig. 3.** Histopathology examination shows hemorrhagic necrosis of the vascular wall (H and E,  $\times 100$ ).



**Fig. 4.** Follow up MR images after 6 months showing resolution of hematoma and no vascular abnormality on the sagittal T2-weighted image.

3. Isayama Y, Nakagawara J, Takeda R, Wada K, Hyogo T, Sasaki T, et al. : [A case of cerebral arteriovenous malformation revealed at repeated subcortical hematoma with initially normal angiogram.] *No Shinkei Geka* 19 : 1175-1180, 1991
4. Johnson PJ, Hahn F, McConnell J, Graham EG, Leibrock LG : The importance of MRI findings for the diagnosis of nontraumatic lumbar subacute subdural haematomas. *Acta Neurochir (Wien)* 113 : 186-188, 1991
5. Kakitsubata Y, Theodorou SJ, Theodorou DJ, Miyata Y, Ito Y, Yuki Y, et al. : Spontaneous spinal subarachnoid hemorrhage associated with subdural hematoma at different spinal levels. *Emerg Radiol* 17 : 69-72, 2010
6. Krings T, Lasjaunias PL, Hans FJ, Mull M, Nijenhuis RJ, Alvarez H, et al. : Imaging in spinal vascular disease. *Neuroimaging Clin N Am* 17 : 57-72, 2007
7. Kyriakides AE, Lalam RK, El Masry WS : Acute spontaneous spinal subdural hematoma presenting as paraplegia : a rare case. *Spine (Phila Pa*

- 1976) 32 : E619-E622, 2007
8. Morandi X, Riffaud L, Chabert E, Brassier G : Acute nontraumatic spinal subdural hematomas in three patients. *Spine (Phila Pa 1976)* 26 : E547-E551, 2001
  9. Ruelle A, Zerbi D, Andrioli G : Spinal subarachnoid bleeding of unknown etiology. Case reports. *J Neurosurg Sci* 45 : 53-57, 2001
  10. Swann KW, Ropper AH, New PE, Poletti CE : Spontaneous spinal subarachnoid hemorrhage and subdural hematoma. Report of two cases. *J Neurosurg* 61 : 975-980, 1984
  11. Vishteh AG, Theodore N, Spetzler RF : Nontraumatic acute spinal subdural hematoma. *J Neurosurg* 93 : 180-181, 2000
  12. Wada M, Takahashi H, Matsubara S, Hirai S : Occult vascular malformations of the spinal cord : report of four cases not detected by angiography. *Acta Neurol Scand* 101 : 140-143, 2000
  13. Yoo HS, Park SW, Han JH, Chung JY, Yi JW, Kang JM, et al. : Paraplegia caused by an epidural hematoma in a patient with unrecognized chronic idiopathic thrombocytopenic purpura following an epidural steroid injection. *Spine (Phila Pa 1976)* 34 : E376-E379, 2009