

## Case Report

# Cerebellar Pilocytic Astrocytomas with Spontaneous Intratumoral Hemorrhage in Adult

Min-Su Kim, M.D., Sang Woo Kim, M.D., Chul-Hoon Chang, M.D., Oh-Lyong Kim, M.D.

Department of Neurosurgery, Yeungnam University College of Medicine, Daegu, Korea

Cerebellar pilocytic astrocytomas (PAs) are benign gliomas predominantly found in the pediatric population. Intracranial hemorrhages are extremely rare in initial presentations of cerebellar PAs. There are no reports in the medical literature of adult cerebellar PA cases presenting with intratumoral hemorrhage. We report 2 cases of adult cerebellar pilocytic astrocytomas with intratumoral hemorrhage. The first case is a 37-year-old woman presenting with severe headache, nausea, and vomiting. Computed tomography demonstrated an acute hemorrhage adjacent to the right cerebellar hemisphere and hydrocephalus. Magnetic resonance imaging (MRI) revealed a cerebellar vermian tumor with the hemorrhage as a mixed isointense area in the T2-weighted image, and as a mixed hyperintense area in the contrast-enhanced T1-weighted image. The second case is a 53-year-old man presenting with headache for 3 weeks. MRI revealed a cerebellar hemispheric tumor with the hemorrhage as a mixed hyperintense area. It had a cystic mass with a heterogeneous enhanced mural nodule in the gadolinium-enhanced T1-weighted image and a fluid-fluid level within the cyst in the T2-weighted image. Both of them underwent radical resections of their respective lesions. Histological examination of the specimens revealed typical astrocytoma, including a hemorrhagic portion. Both patients recovered postoperatively and continue to do well at present. The medical literature on hemorrhagic cerebellar PAs is also reviewed.

**Key Words :** Pilocytic astrocytoma · Hemorrhage · Cerebellum · Adult.

## INTRODUCTION

A pilocytic astrocytoma (PA), previously known as spongioblastomas, is a slow-growing benign tumor that occurs most commonly in children and young adults<sup>5,7</sup>. The annual incidence for all ages has been reported to be 2.9-4.8 cases per million people, and no gender predilection has been shown<sup>2,5,8</sup>. Among child patients, up to 67% of them present with cerebellar lesions, whereas among adult patients, about 55% present with supratentorial lesions<sup>4</sup>. The rate of intracranial hemorrhages from gliomas is reported to be 3.7-7.2%<sup>3,12,20</sup>. Most glial tumors that have a propensity to present with hemorrhages include high-grade astrocytomas, oligodendrogliomas, and mixed oligoastrocytomas<sup>9,20</sup>. However, in low-grade glial tumors such as PAs, intratumoral hemorrhages are very rare. Seven patients with cerebellar PAs associated with hemorrhage were reported and all these cases were under 15 years of ages (Table 1)<sup>6,10,15-17,19</sup>. We could not find any reports in the medical literature on cerebellar PAs with intratumoral hemorrhages in adults. We report

two adult cases of cerebellar pilocytic astrocytomas with spontaneous intratumoral hemorrhage.

## CASE REPORT

### Case 1

A 37-year-old woman presented with sudden onset of severe headache, nausea, and vomiting. Upon neurological examination, there were no signs of cerebellar dysfunction, including ataxia, dysmetria, and dysdiadochokinesis. Brain non-enhanced computed tomography (CT) at admission revealed a hyperdense mass adjacent to the right cerebellar hemisphere, which was considered to be a hemorrhage (Fig. 1A). CT also revealed an obstructive hydrocephalus. Preoperative brain magnetic resonance imaging (MRI) revealed a cerebellar mass with central mixed-signal intensity and peripheral low-signal intensity in the axial T2-weighted image (Fig. 1B). The mass revealed mixed iso- and high-signal intensity in the axial T1-weighted image (Fig. 1C) and peripheral enhancement in the axial gadolinium-enhanced T1-weighted image (Fig. 1D). There was no evidence of vascular lesions such as arteriovenous malformation or aneurysms in the magnetic resonance angiography.

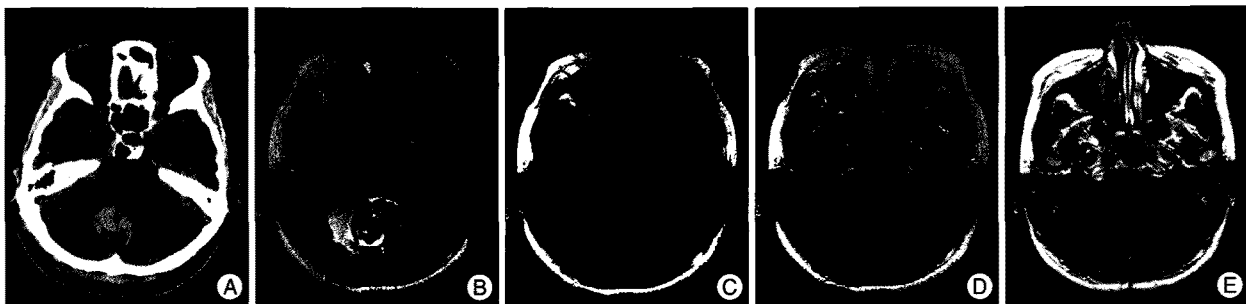
We performed the operation using a midline suboccipital craniotomy under general anesthesia. The cisterna magna was opened, exposing the cerebellar tonsils and the tonsillar loop.

• Received : October 25, 2010 • Revised : December 22, 2010  
• Accepted : May 30, 2011  
• Address for reprints : Oh-Lyong Kim, M.D., Ph.D.  
Department of Neurosurgery, Yeungnam University College of Medicine,  
317-1 Daemyeong-dong, Nam-gu, Daegu 705-717, Korea  
Tel : +82-53-620-3790, Fax : +82-53-620-3770  
E-mail : olkim@med.yu.ac.kr

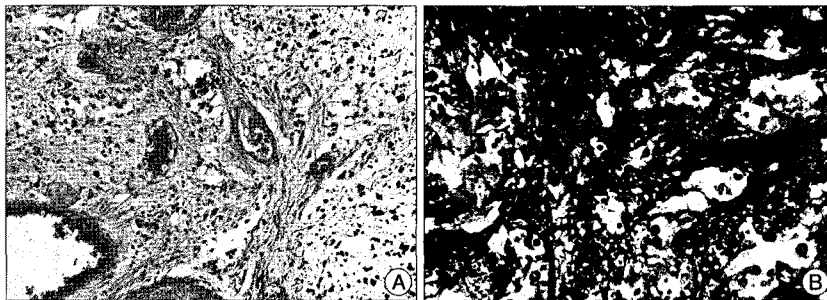
**Table 1.** Summary of reported cases of cerebellar pilocytic astrocytomas with symptomatic hemorrhage

Author (year)	Age (years)/Sex	Location	Type of hemorrhage	Histology	Outcome
Mauersberger et al. (1977) <sup>15</sup>	10/M	Cerebellum	ITB	Spongioblastoma	Alive
	10/F	Cerebellum	ITB	Spongioblastoma	Dead
Vincent et al. (1980) <sup>19</sup>	14/F	Cerebellum	ITB	Pilocytic	Alive
Fogelson et al. (1980) <sup>6</sup>	9/M	Cerebellum	ITB	Pilocytic	Alive
Specht et al. (1986) <sup>17</sup>	8/M	Cerebellum	ITB	Mixed pilocytic/ Oligodendroglioma	Dead
Mesiwala et al. (2001) <sup>16</sup>	13/M	Cerebellum	ITB	Pilocytic	Alive
Lee et al. (2009) <sup>10</sup>	15 months/M	Cerebellum	ITB, SAH, SDH	Pilocytic	Alive
Present cases	37/F	Cerebellum	ITB	Pilocytic	Alive
	53/M	Cerebellum	ITB	Pilocytic	Alive

ITB : intratumoral hemorrhage, SAH : subarachnoid hemorrhage, SDH : subdural hemorrhage



**Fig. 1.** A : Brain non-enhanced computed tomography scan at admission showing a hyperdense mass adjacent to the right cerebellar hemisphere. B : Preoperative axial T2-weighted brain magnetic resonance imaging (MRI) scan showing a cerebellar mass with central mixed-signal intensity and peripheral low-signal intensity. C and D : The mass shows mixed, iso- and high-signal intensity in the T1-weighted axial image and peripheral enhancement in the axial gadolinium-enhanced T1-weighted image. E : Axial gadolinium-enhanced T1-weighted MRI obtained three months after operation showing no residual or recurred lesions.



**Fig. 2.** A : Histopathological examination shows astrocytic tumor cells with numerous Rosenthal fibers and hyalinized blood vessels (H&E staining,  $\times 100$ ). B : Immunohistochemical staining for glial fibrillary acidic protein shows very positive ( $\times 200$ ).

We could see the tumor beneath the right cerebellar tonsil. The tumor was grayish-colored, relatively firm and well-demarcated from the surrounding normal tissue with intratumoral hematoma. We were able to perform the en-bloc removal easily and completely.

The surgery was successful without neurological deficits. Histopathological examination of the specimen revealed a typical PA featuring astrocytic tumor cells with numerous Rosenthal fibers and hyalinized blood vessels (Fig. 2A). Bipolar cells with long hair-like glial fibrillary acidic protein-positive processes were observed after using an immunochemical staining technique (Fig. 2B). Occult coexisting vascular malformations were not observed. Three months after the operation, MRI demon-

strated no residual or recurrent lesions (Fig. 1E). The patient recovered postoperatively and continues to do well.

**Case 2**

A 53-year-old man presented with a three-week headache. Upon neurological examination, there were no signs of cerebellar dysfunction. Brain CT demonstrated a barely high-density mass within the cystic portion of the left cerebellar hemisphere. Brain MRI revealed a left

cerebellar hemispheric cystic mass with fluid-blood level in the axial T2-weighted image (Fig. 3A) and a heterogeneously enhanced mural nodule in the axial gadolinium-enhanced T1-weighted image (Fig. 3B). There was no evidence of vascular lesions from MRI. We performed the operation using a retrosigmoid suboccipital craniotomy under general anesthesia. We could see the tumor on the petrosal surface of the cerebellum. The lateral portion of the tumor was grayish, firm, and easily distinguishable from the normal tissue. The cyst contained xanthochromic fluid, suggesting previous hemorrhage. We were able to perform radical resection of the enhanced tumor with a hematoma. Histopathological examination of the specimens revealed hemorrhages and compact portions consisting of astro-

cytic tumor cells (Fig. 4A). Neoplastic astrocytes with eosinophilic granular bodies and Rosenthal fibers in the glial fibrillary background were visible (Fig. 4B). Three months after the operation, MRI demonstrated no residual or recurrent lesions (Fig. 3C). The patient recovered postoperatively and continues to do well.

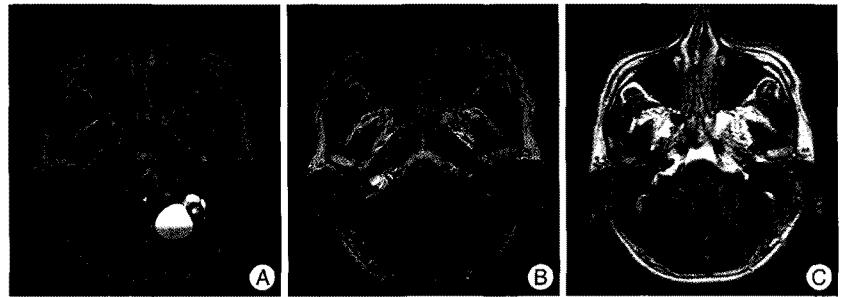## DISCUSSION

A cerebellar PA is well demarcated, often having a cyst with a mural nodule, and is usually located in the cerebellar hemisphere. The presenting symptoms of these tumors are commonly headache, vomiting, mental change, gait ataxia, tremors, and dysmetria. Usually, these symptoms develop insidiously. White et al.<sup>21)</sup> recently reported that the rate of spontaneous hemorrhages in histologically proven cases of PAs was 8%, but no hemorrhages occurred within the cerebellum.

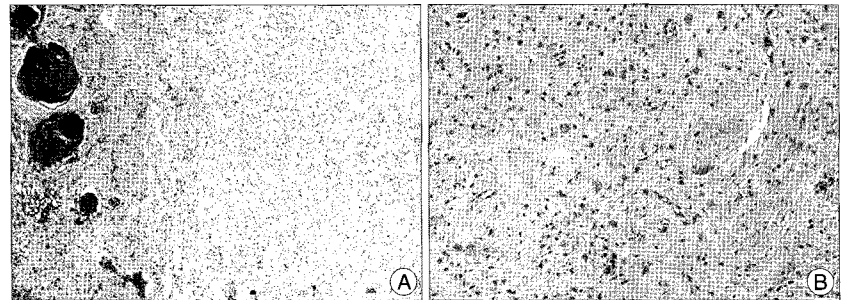
The association between age and tumor location is strong. Most cerebral hemorrhagic PAs occur in adults, whereas cerebellar hemorrhagic PAs occur mostly in children<sup>11)</sup>. The symptomatic hemorrhages associated with cerebellar PAs are extremely rare (Table 1)<sup>6,10,15-17,19)</sup>. The mechanism of high-grade gliomas is likely related to necrosis of blood vessels, as well as to abundant neovascular proliferation. However, the mechanism of hemorrhage in low-grade gliomas is not well known and has been a subject of debate. Lyons<sup>14)</sup> reported that in an elderly adults, the potential microscopic infiltration of PAs into the adjacent parenchyme might influence the likelihood of spontaneous hemorrhage in the setting of adjacent focal congophilic angiopathy and anticoagulation. Van Quwerkerk and Dirven<sup>18)</sup> reported that in a child, a medullary PA including oligodendrogliotic parts manifested as acute onset of symptoms caused by the intratumoral hemorrhage. They suggested that the hemorrhage might have originated from abnormal fragile vasculatures in oligodendrogliotic parts of the tumor or in occult coexisting vascular malformations.

Endothelial proliferation, rupture of an encased aneurysm, and dysplastic capillary beds have been factors hypothesized as potential causes for bleeding<sup>1,13)</sup>. In our cases, the patients had normal platelet-cell counts, prothrombin time, partial thromboplastin time, and no history of hypertension or coagulation defects related to systemic disease, chemotherapy, or radiation.

The cause of hemorrhage in our cases is unclear, but we assume that hemorrhage may be related to the abnormal vasculature within the tumor.



**Fig. 3.** A : Preoperative axial T2-weighted brain magnetic resonance imaging (MRI) scan showing a left cerebellar hemispheric cystic mass with fluid-fluid level. B : Preoperative axial gadolinium-enhanced T1-weighted MRI showing heterogeneous enhanced mural nodule and peripheral enhanced cystic mass. C : Axial gadolinium-enhanced T1-weighted MRI obtained three months after operation showing no residual or recurrent lesions.



**Fig. 4.** A : Histopathological examination shows hemorrhage and compact portions consisting of astrocytic tumor cells (H&E staining,  $\times 40$ ). B : Neoplastic astrocytes with eosinophilic granular bodies and Rosenthal fibers in the glial fibrillary background are shown (H&E staining,  $\times 100$ ).

In general, PAs shows little or no peritumoral edema in MRI findings. However, in our cases, there were evident peritumoral edemas, which may have been due to a hemorrhagic effect. The enhancing patterns of PAs have been described as 1) a mass with an enhancing cyst wall and an intensely enhancing mural nodule, 2) a mass with a non-enhancing cyst and an intensely enhancing mural nodule, 3) a predominantly solid mass with minimal to no cystic component, and 4) a necrotic mass with a central non-enhancing zone<sup>8)</sup>.

Our two cases showed a cystic mass with an enhancing mural nodule. In these cases, we performed radical resections of the enhanced lesions with hemorrhage. The surgical cures were successful without neurological deficits.

## CONCLUSION

We report the first adult cases of cerebellar pilocytic astrocytomas presenting with intratumoral hemorrhages. It is extremely unusual for cerebellar pilocytic astrocytomas to be associated with hemorrhages, but this should be considered during differential diagnoses of intracerebellar hemorrhages with acute presentations. Such exceptional cerebellar tumors should be resected completely and should undergo histological examination to decide on further appropriate treatment.

## References

1. Aichholzer M, Gruber A, Haberler C, Bertalanffy A, Slavic I, Czech T :

- Intracranial hemorrhage from an aneurysm encased in a pilocytic astrocytoma--case report and review of the literature. *Childs Nerv Syst* 17 : 173-178, 2001
2. Bell D, Chitnavis BP, Al-Sarraj S, Connor S, Sharr MM, Gullan RW : Pilocytic astrocytoma of the adult--clinical features, radiological features and management. *Br J Neurosurg* 18 : 613-616, 2004
  3. Bitoh S, Hasegawa H, Ohtsuki H, Obashi J, Fujiwara M, Sakurai M : Cerebral neoplasms initially presenting with massive intracerebral hemorrhage. *Surg Neurol* 22 : 57-62, 1984
  4. Brown PD, Buckner JC, O'Fallon JR, Iturria NL, Brown CA, O'Neill BP, et al : Adult patients with supratentorial pilocytic astrocytomas : a prospective multicenter clinical trial. *Int J Radiat Oncol Biol Phys* 58 : 1153-1160, 2004
  5. Burkhard C, Di Patre PL, Schuler D, Schuler G, Yasargil MG, Yonekawa Y, et al : A population-based study of the incidence and survival rates in patients with pilocytic astrocytoma. *J Neurosurg* 98 : 1170-1174, 2003
  6. Fogelson MH, Oppenheim RE, McLaurin RL : Childhood cerebellar astrocytoma presenting with hemorrhage. *Neurology* 30 : 669-670, 1980
  7. Forsyth PA, Shaw EG, Scheithauer BW, O'Fallon JR, Layton DD Jr, Katzmann JA : Supratentorial pilocytic astrocytomas. A clinicopathologic, prognostic, and flow cytometric study of 51 patients. *Cancer* 72 : 1335-1342, 1993
  8. Koeller KK, Rushing EJ : From the archives of the AFIP : pilocytic astrocytoma : radiologic-pathologic correlation. *Radiographics* 24 : 1693-1708, 2004
  9. Kondziolka D, Bernstein M, Resch L, Tator CH, Fleming JF, Vanderlinden RG, et al : Significance of hemorrhage into brain tumors : clinicopathological study. *J Neurosurg* 67 : 852-857, 1987
  10. Lee CS, Huh JS, Sim KB, Kim YW : Cerebellar pilocytic astrocytoma presenting with intratumor bleeding, subarachnoid hemorrhage, and subdural hematoma. *Childs Nerv Syst* 25 : 125-128, 2009
  11. Li HM, Hsu SS, Wang JS, Weng MJ, Fu JH, Chen CK, et al : Cerebral pilocytic astrocytoma with spontaneous intracranial hemorrhage in adults. *J Chin Med Assoc* 71 : 587-593, 2008
  12. Lieu AS, Hwang SL, Howng SL, Chai CY : Brain tumors with hemorrhage. *J Formos Med Assoc* 98 : 365-367, 1999
  13. Liwnicz BH, Wu SZ, Tew JM Jr : The relationship between the capillary structure and hemorrhage in gliomas. *J Neurosurg* 66 : 536-541, 1987
  14. Lyons MK : Pilocytic astrocytoma with spontaneous intracranial hemorrhages in an elderly adult. *Clin Neurol Neurosurg* 109 : 76-80, 2007
  15. Mauersberger W, Cuevas-Solórzano JA : Spontaneous intracerebellar hematoma during childhood caused by spongioblastoma of the IVth ventricle. *Neuropadiatrie* 8 : 443-450, 1977
  16. Mesiwala AH, Avellino AM, Roberts TS, Ellenbogen RG : Spontaneous cerebellar hemorrhage due to a juvenile pilocytic astrocytoma : case report and review of the literature. *Pediatr Neurosurg* 34 : 235-238, 2001
  17. Specht CS, Pinto-Lord C, Smith TW, DeGirolami U, Suran E, Marshall PC, et al : Spontaneous hemorrhage in a mixed glioma of the cerebellum : case report. *Neurosurgery* 19 : 278-281, 1986
  18. van Ouwkerk WJ, Dirven CM : Hematoma in a low-grade medullary astrocytoma : report of an unusual case and literature review. *Childs Nerv Syst* 14 : 742-746, 1998
  19. Vincent FM, Bartone JR, Jones MZ : Cerebellar astrocytoma presenting as a cerebellar hemorrhage in a child. *Neurology* 30 : 91-93, 1980
  20. Wakai S, Yamakawa K, Manaka S, Takakura K : Spontaneous intracranial hemorrhage caused by brain tumor : its incidence and clinical significance. *Neurosurgery* 10 : 437-444, 1982
  21. White JB, Piepgras DG, Scheithauer BW, Parisi JE : Rate of spontaneous hemorrhage in histologically proven cases of pilocytic astrocytoma. *J Neurosurg* 108 : 223-226, 2008