

Clinical Article

Surgical Results of Unruptured Intracranial Aneurysms in the Elderly : Single Center Experience in the Past Ten Years

Young Jin Jung, M.D., Jae Sung Ahn, M.D., Eun Suk Park, M.D., Do Hoon Kwon, M.D., Byung Duk Kwun, M.D., Chang Jin Kim, M.D.

Department of Neurological Surgery, University of Ulsan College of Medicine, Asan Medical Center, Seoul, Korea

Objective : As medical advances have increased life expectancy, it has become imperative to develop specific treatment strategies for intracranial aneurysms in the elderly. We therefore analyzed the clinical characteristics and outcomes of the treatment of unruptured intracranial aneurysms in patients older than 70 years.

Methods : We retrospectively reviewed the medical records and results of neuroimaging modalities on 54 aneurysms of 48 consecutive patients with unruptured intracranial aneurysms. (mean±SD age, 72.11±1.96 years; range, 70-78 years) who underwent surgical clipping over 10 years (May 1999 to June 2010).

Results : Of the 54 aneurysms, 22 were located in the internal carotid artery, 19 in the middle cerebral artery, 12 in the anterior cerebral artery, and 1 in the superior cerebellar artery. Six patients had multiple aneurysms. Aneurysm size ranged from 3 mm to 17 mm (mean±SD, 6.82±3.07 mm). Fifty of the 54 aneurysms (92.6%) were completely clipped. Three-month outcomes were excellent in 50 (92.6%) aneurysms and good and poor in 2 each (3.7%), with 1 death (2.0%). Procedure-related complications occurred in 7 aneurysms (13.0%), with 2 (3.7%) resulting in permanent neurological deficits, including death. No postoperative subarachnoid hemorrhage occurred during follow-up. The cumulative rates of stroke- or death-free survival at 5 and 10 years were 100% and 78%, respectively.

Conclusion : Surgical clipping of unruptured intracranial aneurysms in elderly group could get it as a favorable outcome in well selected cases.

Key Words : Unruptured intracranial aneurysm · Surgical clipping · Elderly · Outcome.

INTRODUCTION

The number of elderly patients (aged at least 70 years) has been increasing in Korea owing to increased life expectancy caused by advances in medicine. The development of new and non-invasive diagnostic technology has increased the detection of unruptured intracranial aneurysms (UIA). Surgical treatment has been recommended in patients under 70 years of age with UIAs larger than 10 mm¹²⁾, but there are no meaningful data on the results of surgical treatment of UIAs in elderly patients⁹⁾. We therefore analyzed the clinical characteristics and outcomes of surgical treatment of UIAs in patients older than 70 years.

MATERIALS AND METHODS

We performed a retrospective review of elderly patients who underwent surgical clipping of UIAs between May 1999 and June 2010 in our institute. We exclude the aneurysm in the cavernous portion and the aneurysm was treated by endovascular coiling. We identified a total of 48 patients (54 aneurysms) aged 70 years or older (mean age, 72.11±1.96 years; range, 70-78 years). Forty-five patients were clinically followed-up in September 2010 by telephone interview or at visits to the outpatient department.

Preoperative general inspection, such as cardio-pulmonary function test was fully evaluated. So, patients who have medical problems were excluded for the treatment. The neurologic state of the patients was assessed by neurologists and radiologic findings, including those of computed tomography (CT), transfemoral cerebral angiography (TFCA) and magnetic resonance image (MRI), were interpreted by neuroradiologists and a neurosurgeon. All patients underwent pre- and postoperative CT angiography. TFCA was performed preoperatively in 34 patients and postoperatively in 32. Surgical results were evaluated by

• Received : January 27, 2011 • Revised : March 29, 2011

• Accepted : May 9, 2011

• Address for reprints : Jae Sung Ahn, M.D.

Department of Neurological Surgery, University of Ulsan College of Medicine, Asan Medical Center, 86 Asanbyeongwon-gil, Songpa-gu, Seoul 138-736, Korea

Tel : +82-2-3010-3564, Fax : +82-2-476-6738

E-mail : jsahn@amc.seoul.kr

Table 1. Patient characteristics

Characteristic	
Patients/Aneurysms	48/54
Age (yr±SD)	72.11±1.96
Women : Men	33 : 15
Smokers	7 (14.6%)
Previous hypertension	32 (66.7%)
Family history	1 (2.1%)
Aneurysm Size (mm±SD)	6.82±3.07
Small/Large/Giant Aneurysms	42 (77.8%)/12 (22.2%)/0 (0%)

SD : Standard deviation, Small : aneurysm <10 mm, Large : 10 mm ≤aneurysm <25 mm, Giant : aneurysm ≥25 mm

Table 2. Presenting symptoms

Symptoms	Number of Aneurysms (%)
Headache	24 (44.4)
Dizziness	6 (11.1)
TIA	5 (9.3)
Ptosis	4 (7.4)
Previous SAH	2 (3.7)
Others	7 (13.0)
Incidental	6 (11.0)

TIA : transient ischemic attack, SAH : subarachnoid hemorrhage

Table 3. Location of the aneurysms

Location	Number of Aneurysms (%)
ACA	12 (22)
AcomA	9 (16.7)
DACA	3 (5.6)
MCA	19 (35.2)
M1	1 (1.9)
MCAb	18 (33.3)
ICA	22 (40.7)
ICAb	3 (5.6)
OA	1 (1.9)
AChA	2 (3.7)
PcomA	15 (27.8)
Paraclinoid	1 (1.9)
PCA/SCA/VBA	1 (1.9)
SCA	1 (1.9)

ACA : anterior cerebral artery, AcomA : anterior communicating artery, DACA : distal ACA, MCA : middle cerebral artery, MCAb : MCA bifurcation, ICA : internal carotid artery, ICAb : ICA bifurcation, OA : ophthalmic artery, AChA : anterior choro-roidal artery, PcomA : posterior communicating artery, PCA : posterior cerebral artery, SCA : superior cerebellar artery, VBA : vertebrobasilar artery

Table 4. Surgical results of unruptured intracranial aneurysms

	Number of patients (%)	Remarks
Complete clipping	50 (92.6)	
Incomplete clipping*	4 (7.4)	
M2 bifurcation	1 (1.9)	Broad neck and severe atherosclerotic change
ICA-Pcom	3 (5.6)	Large PcomA aneurysm and fetal type PCA

*Follow-up transfemoral cerebral angiography or computed tomography angiography showed no growth or change in morphology for more than 1 year after surgery. ICA : internal carotid artery, PcomA : posterior communicating artery, PCA : posterior cerebral artery

neuroradiologists using postoperative three-dimensional angiography. Postoperative outcomes were evaluated using the modified Rankin scale (mRS) at 3 and 12 months after surgery¹⁷⁾. Surgical morbidity was defined as newly developed neurological deficits lasting at least 7 days after surgery and correlated with MRI or CT findings. Perioperative risk factors for postoperative complications were analyzed. All statistical analyses were performed using the SPSS program (version 12.0; SPSS, Inc., Chicago, IL, USA). Categorical variables were compared using Pearson's chi-square tests or Fisher exact tests, where appropriate. Continuous variables were reported as means±standard deviations and compared using independent Student t-tests or Mann-Whitney U-tests. A probability less than 0.05 was considered statistically significant. Postoperative stroke- or death-free survival time was assessed using the Kaplan-Meier method.

RESULTS

Of the 48 patients, 33 were women and 15 were men (Table 1). Preoperative maximum fundus diameter was 6.82±3.07 mm (range, 2.00 to 15.00 mm). Of the 54 aneurysms, none (0%) was a giant aneurysm >25 mm in diameter, 12 (22.2%) were large, ranging from 10 to 24 mm in diameter, and 42 (77.8%) were small, less than 10 mm in diameter. Forty-two (87.5%) patients had single aneurysms and 6 (12.5%) had multiple aneurysms. Symptoms occurred in 42 (87.5%) patients and included headache, dizziness, transient ischemic attack, diplopia, memory disturbance and seizure; 6 (12.5%) patients were asymptomatic (Table 2). Of the 54 aneurysms, 22 (40.7%) were located in the internal carotid artery (ICA), 19 (35.2%) in the middle cerebral artery, 12 (22.2%) in the anterior cerebral artery, and 1 (1.9%) in the superior cerebellar artery (Table 3).

In 50 of the 54 aneurysms (92.6%) surgical clipping resulted in complete clipping, the remaining 4 (7.4%) were incompletely clipped (Table 4). Of these four, one M2 bifurcation aneurysm was treated by reconstruction of the base of the aneurysm due to a broad neck and severe atherosclerotic changes, thus avoiding parent vessel stenosis or occlusion. The other three aneurysms were large posterior communicating artery aneurysms with a fetal type posterior cerebral artery (PCA) and were treated by reconstruction with multiple clips to maintain patency of the PCA. Follow-up radiologic images taken more than 1 year after surgery showed no regrowth or change in morphology in aneurysms that underwent clip reconstruction. Of the 48 patients, 20 underwent

follow up radiologic imaging after 1 year to detect recurrences, but none showed recurrence of the aneurysms.

Except of one illustrated case described below, there were no medical related complications such as postoperative pneumonia or cardiac problem. Procedure-related complications occurred in seven (13.0%) aneurysms following surgery (Table 5);

these complications were not related to the size or location of the aneurysm. Complications included postoperative cerebral infarction in three aneurysms (5.6%), postoperative chronic subdural hematoma in two (3.7%), and ischemic intracranial hemorrhage and wound infection in 1 each (1.9%). Most common complication is postoperative cerebral infarction may be due to small vessel injury. It is similar as previous study⁹⁾. Fortunately, two cases of infarction were treated without sequelae but one case suffered from permanent neurologic sequelae. One patient died due to surgically related complications. Permanent neurological deficits occurred in two patients, one of whom died.

Post-treatment, 3-month outcomes were excellent (mRS 0-1) for 50 aneurysms (92.6%), good (mRS 2-3) for 2 (3.7%); and poor (mRS 4-5) for 1 (1.9%), with 1 death (mRS 6). One year after surgery clinical outcomes were excellent (mRS 0-1) in 93.2%, good (mRS 2-3) in 4.5%, poor (mRS 4-5) in 0%; and death (mRS 6) in 2.3%. At last follow-up, clinical outcomes were excellent (mRS 0-1) in 86.3%, good (mRS 2-3) in 5.9%, poor (mRS 4-5) in 4%, and death (mRS 6) in 3.9% (Table 6). Kaplan-Meier analysis showed that the cumulative rates of stroke- or death-free survival at 5 and 10 years were 100% and 77.8%, respectively. The mean event-free survival time in these 48 patients was 159.44 months (95% confidence interval, 128.11-190.78 months) (Fig. 1).

Case

A 72-year-old woman was admitted to our department due to suffering a headache and left eye ptosis for several days. Computed tomography (CT) showed calcification in both basal ganglia but no definite high density region in the basal or sylvian cistern (Fig. 2). TFCA showed a wide-necked large aneurysm

on her left posterior communicating artery. After pterional craniotomy, the sac was isolated using two right-angled fenestrated clips. To decompress the oculomotor nerve, which was compressed by the aneurysm, we began to dissect the daughter sac adhering to the left oculomotor nerve. However, there was sudden blood flow from the dome of the aneurysm, leading to an unplanned neck dissection for proximal control. The neck portion was clipped temporarily, with multiple clips resulting in successful occlusion. Microvascular Doppler showed good blood flow of the posterior communicating artery and the distal ICA.

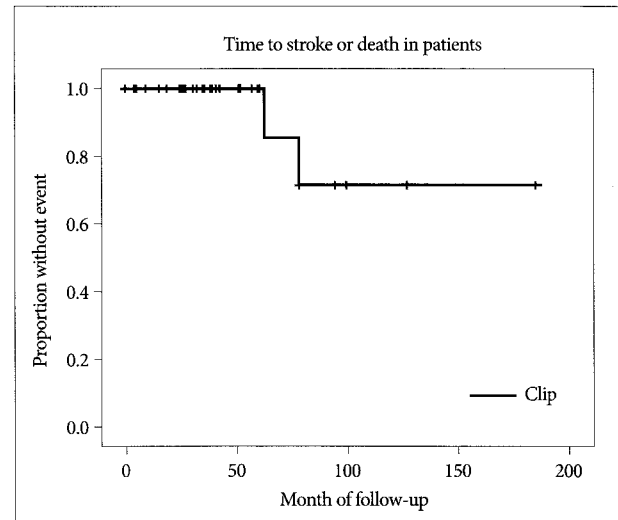


Fig. 1. Kaplan-Meier analysis of cumulative stroke- and death-free survival rate : 100% at 5 years and 77.8% at 10 years. The mean event-free survival was 159.44 months (95% confidence interval, 128.11-190.78 months).

Table 5. Procedure-related complications and clinical outcomes after 3 months

Patient No.	Age/Sex	Location	Clinical data	Size	Complication/ Cause	mRS
1	72/F	ICA (P-comA)	Headache	9.00	ICH on Cerebellum, Infarction on left hemisphere d/t premature rupture, prolong proximal control Pneumonia	6
2	75/F	ACA (A23 junction)	Headache	7.20	Infarction & hemorrhagic transformation d/t cortical vein injury	4
3	73/M	ACA (A23 junctions)	Headache	4.00	Chronic subdural hematoma	1
4	70/F	ICA (P-comA)	TIA	3.10	Wound infection	0
5	70/M	ACA (A-comA)	Hemiparesis	5.50	Chronic subdural hematoma	1
6	72/F	ICA (P-comA)	Headache	4.38	Subtle ischemic change	0
7	70/M	ICA (ICAb)	TIA	7.60	Subtle ischemic change	0

mRS : modified Rankin scale, ACA : anterior cerebral artery, ICA : internal carotid artery, PcomA : posterior communicating artery, ICH : intracranial hemorrhage, AcomA : anterior communicating artery, TIA : transient ischemic attack, ICAb : internal carotid artery bifurcation

Table 6. Clinical outcomes

	At admission	At discharge	At 3 months after surgery	At 12 months after surgery	A last follow-up
Excellent	54	50	50	41	44
Good	0	2	2	2	4
Poor	0	1	1	0	3
Death	0	1	1	1	3
	n=54	n=54	n=54	n=44	n=54

mRS : modified Rankin Scale, N : number of cases, Excellent : mRS 0-1, Good : mRS 2-3, Poor : mRS 4-5, Death : mRS 6

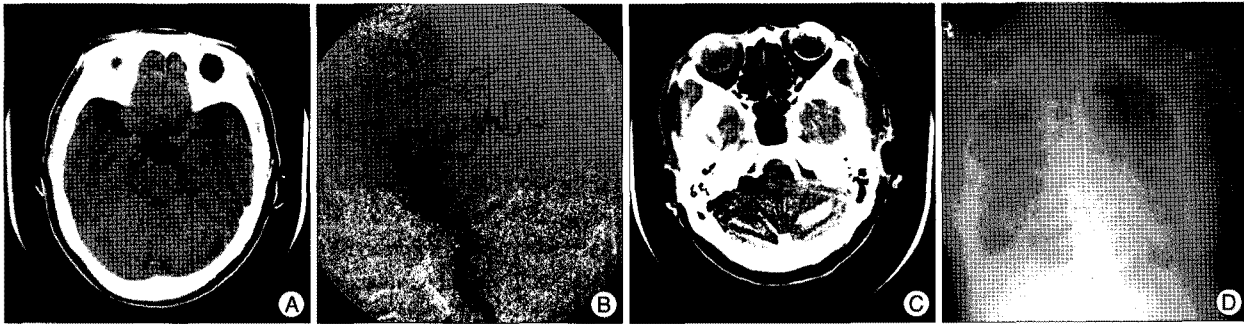


Fig. 2. A 72-year-old woman admitted to our institution due to headache and left eye ptosis. A : Preoperative computed tomography (CT) showing calcification in both basal ganglia but no definite high-density area in the basal or sylvian cistern. B : Transfemoral cerebral angiography showing a wide-necked large aneurysm on the left posterior communicating artery. C : Postoperative CT scan showing a high-density area in the left cerebellum. D : The patient died due to aggravated pneumonia and sepsis.

During the operation, the patient received six pints of packed red blood cells. Postoperative neurologic examination revealed right-sided hemiparesis (grade 2) and stupor mentality. A CT scan after surgery showed a low-density region around the operation site. The patient's neurologic state did not recover and a CT scan 3 days after surgery revealed a high-density area on the left cerebellum and a low-density area on the left hemisphere. The patient died 21 days after surgery due to aggravated pneumonia and sepsis.

DISCUSSION

In South Korea, the average life expectancy of women is 83.3 years and that of men is 76.5 years. The development of new diagnostic technologies and the prolonged average life expectancy have led to increased detection of unruptured intracranial aneurysms in elderly patients. The prevalence of UIA in the general population is 4.2%⁵. Although a systematic review of UIA in international large-scale cohort studies showed that the annual risk of UIA rupture is very low^{1,18,21}, patients with untreated UIA in Japan had a significantly higher risk of rupture¹³. Moreover, the risk of UIA rupture in Korean patients is similar to that in Japanese patients. Subarachnoid hemorrhage (SAH) from rupture of cerebral aneurysm is an important cause of stroke and the incidence of SAH increases with age^{13,18}, from approximately 1.5 to 2.5 per 100,000 persons per year during the third decade of life to approximately 40 to 78 per 100,000 persons per year during the eighth decade^{16,19}. The risk of rupture of UIA is about 3.05-5.7% per year in elderly patients, higher than in the general population¹⁸. In addition, the mortality rate after subarachnoid hemorrhage is high at about 32-67%, with about 30% of survivors having moderate to severe disability⁷. Among these patients, the rate of medical complications associated with poor outcomes was also high, including a death rate from medical complications of 23%²⁰. Complications also increased with patient age, with outcomes being worse in elderly patients with than without complications. Moreover, UIA, and the knowledge that rupture could lead to death, can have a negative impact on quality of life.

UIA can be treated by placing a clip over the neck of the aneurysm, isolating it from the circulation, or endovascularly with detachable coils. Craniotomy to clip the UIA is regarded as more invasive and associated with greater risks for elderly patients because many are in poor general health, with conditions such as heart disease, renal disease, and/or cerebrovascular disease, all of which are poor prognostic factors for major surgery^{3,21}. In contrast, endovascular treatment has low rates of procedural morbidity and mortality, particular advantages in patients with poor general health or multiple risk factors¹⁵. In UIA patients in general, endovascular treatment has been associated with lower rates of complications, mortality and morbidity rate than surgical clipping, with overall 30-day morbidity and mortality rates of 1.8% and 13.7%, respectively, in patients undergoing open surgery and 2.0% and 9.3%, respectively, in patients receiving endovascular treatment²¹. Another study found that the mortality rate was 0%, the morbidity rate was 8.3% and the embolization rate was 76% in patients with UIA¹⁵. Different findings have been observed in elderly patients, however, with endovascular treatment associated with higher rates of procedure-related morbidity and incomplete treatment. Patients' vessels become more tortuous or kinked with age, and advanced atherosclerotic degeneration of the vessel may trigger ischemic complications of thromboembolic events during the endovascular procedure. A previous study (Table 7) found that, although there were no procedure-related deaths, complete embolization was accomplished in only 28% of elderly patients with UIAs, recanalization was common (24%), 14% required further embolization, and the rate of good outcomes (mRS, 0-2) was 91%⁶. Another study found that coiling resulted in excellent outcomes (mRS 0-1) in 83% of elderly patients, with a procedure-related morbidity rate of 9%, and death rate of 4.5%⁴.

Although the surgical risk of craniotomy for patients with UIA has been reported to be unrelated to patient age⁸, other studies have reported surgical morbidity rates of 6-16.7% and mortality rates of 0-5.2%^{8,9,21}, higher than the rates of 2.2-15.3% and 0.3-2.3%, respectively, reported in all patients with UIA^{2,10,11,14,21}. Moreover, the 1-year rate of poor outcomes in patients aged more than 70 years was 30%, higher than in other age groups.

Table 7. Previously reported results of unruptured intracranial aneurysms in patients aged >70 years

	Number of cases	Treatment modality	Complete treatment (%)	Mortality (%)	Morbidity (%)
Cai et al. ⁴⁾	22	Coil	-	4.5	9
Gonzalez et al. ⁶⁾	97	Coil	28	0	6
Inagawa et al. ⁸⁾	18	Clip	-	0	5.6
Kashiwagi et al. ⁹⁾	96	Clip	-	5.2	21.9
Current study	54	Clip	92.6	1.9	13

In our series, the morbidity and mortality rates were 13.0% and 1.9%, respectively. The common complication was cerebral infarction due to small vessel injury during the operation. Moreover, 1-year outcomes were generally excellent, as was the event-free survival rate. Our findings are therefore better than those of previous studies of both surgical and endovascular treatment, with risks similar to those for middle-aged patients (Table 7). Compared with middle-aged patients, the elderly do not differ in the mechanism of the postoperative surgical complication. Avoiding damage to small vessels is most important during the surgery.

CONCLUSION

We found that surgical clipping was associated with favorable outcomes for elderly patients with UIA. Our study design, however, was retrospective in nature, associated with inherent limitations and biases. Randomized prospective studies are required to show that surgical clipping of UIAs in this age group is safe and effective.

References

- Unruptured intracranial aneurysms--risk of rupture and risks of surgical intervention. International Study of Unruptured Intracranial Aneurysms Investigators. *N Engl J Med* 339 : 1725-1733, 1998
- Ahn JS, Kwon Y, Kwun BD : Surgical management of unruptured intracranial aneurysms. *J Korean Neurosurg Soc* 29 : 330-335, 2000
- Barker FG 2nd, Amin-Hanjani S, Butler WE, Hoh BL, Rabinov JD, Pryor JC, et al. : Age-dependent differences in short-term outcome after surgical or endovascular treatment of unruptured intracranial aneurysms in the United States, 1996-2000. *Neurosurgery* 54 : 18-28; discussion 28-30, 2004
- Cai Y, Spelle L, Wang H, Piotin M, Mounayer C, Vanzin JR, et al. : Endovascular treatment of intracranial aneurysms in the elderly : single-center experience in 63 consecutive patients. *Neurosurgery* 57 : 1096-1102; discussion 1096-1102, 2005
- Chang HS : Simulation of the natural history of cerebral aneurysms based on data from the International Study of Unruptured Intracranial Aneurysms. *J Neurosurg* 104 : 188-194, 2006
- Gonzalez NR, Dusick JR, Duckwiler G, Tateshima S, Jahan R, Martin NA, et al. : Endovascular coiling of intracranial aneurysms in elderly patients: report of 205 treated aneurysms. *Neurosurgery* 66 : 714-720; discussion 720-721, 2010
- Hop JW, Rinkel GJ, Algra A, van Gijn J : Case-fatality rates and functional outcome after subarachnoid hemorrhage : a systematic review. *Stroke* 28 : 660-664, 1997
- Inagawa T, Hada H, Katoh Y : Unruptured intracranial aneurysms in elderly patients. *Surg Neurol* 38 : 364-370, 1992
- Kashiwagi S, Yamashita K, Kato S, Takasago T, Ito H : Elective neck clipping for unruptured aneurysms in elderly patients. *Surg Neurol* 53 : 14-20, 2000
- Kim JE, Lim DJ, Hong CK, Joo SP, Yoon SM, Kim BT : Treatment of unruptured intracranial aneurysms in South Korea in 2006 : a nationwide multicenter survey from the Korean Society of Cerebrovascular Surgery. *J Korean Neurosurg Soc* 47 : 112-118, 2010
- King JT Jr, Berlin JA, Flamm ES : Morbidity and mortality from elective surgery for asymptomatic, unruptured, intracranial aneurysms : a meta-analysis. *J Neurosurg* 81 : 837-842, 1994
- Komotar RJ, Mocco J, Solomon RA : Guidelines for the surgical treatment of unruptured intracranial aneurysms : the first annual J. Lawrence Pool Memorial Research Symposium--controversies in the management of cerebral aneurysms. *Neurosurgery* 62 : 183-193; discussion 193-194, 2008
- Morita A, Fujiwara S, Hashi K, Ohtsu H, Kirino T : Risk of rupture associated with intact cerebral aneurysms in the Japanese population: a systematic review of the literature from Japan. *J Neurosurg* 102 : 601-606, 2005
- Moroi J, Hadeishi H, Suzuki A, Yasui N : Morbidity and mortality from surgical treatment of unruptured cerebral aneurysms at Research Institute for Brain and Blood Vessels-Akita. *Neurosurgery* 56 : 224-231; discussion 224-231, 2005
- Park SH, Lee CY, Yim MB : The merits of endovascular coil surgery for patients with unruptured intracranial aneurysms. *J Korean Neurosurg Soc* 43 : 270-274, 2008
- Phillips LH 2nd, Whisnant JP, O'Fallon WM, Sundt TM Jr : The unchanging pattern of subarachnoid hemorrhage in a community. *Neurology* 30 : 1034-1040, 1980
- Rankin J : Cerebral vascular accidents in patients over the age of 60. II. Prognosis. *Scott Med J* 2 : 200-215, 1957
- Rinkel GJ, Djibuti M, Algra A, van Gijn J : Prevalence and risk of rupture of intracranial aneurysms: a systematic review. *Stroke* 29 : 251-256, 1998
- Sacco RL, Wolf PA, Bharucha NE, Meeks SL, Kannel WB, Charette LJ, et al. : Subarachnoid and intracerebral hemorrhage : natural history, prognosis, and precursive factors in the Framingham Study. *Neurology* 34 : 847-854, 1984
- Solenski NJ, Haley EC Jr, Kassell NF, Kongable G, Germanson T, Truskowski L, et al. : Medical complications of aneurysmal subarachnoid hemorrhage : a report of the multicenter, cooperative aneurysm study. Participants of the Multicenter Cooperative Aneurysm Study. *Crit Care Med* 23 : 1007-1017, 1995
- Wiebers DO, Whisnant JP, Huston J 3rd, Meissner I, Brown RD Jr, Piepgras DG, et al. : Unruptured intracranial aneurysms : natural history, clinical outcome, and risks of surgical and endovascular treatment. *Lancet* 362 : 103-110, 2003