

Resorption of labial bone in maxillary anterior implant

Young-Bum Cho, DDS, MSD, Seung-Jin Moon, DDS, MSD, Chae-Heon Chung, DDS, PhD, Hee-Jung Kim*, DDS, PhD

Department of Prosthodontics, Graduate School of Chosun University, Gwangju, Korea

PURPOSE. The purpose of this study was to evaluate the amount of resorption and thickness of labial bone in anterior maxillary implant using cone beam computed tomography with Hitachi CB Mercuray (Hitachi, Medico, Tokyo, Japan). **MATERIALS AND METHODS.** Twenty-one patients with 26 implants were followed-up and checked with CBCT. 21 OSSEOTITE NT® (3i/implant Innovations, Florida, USA) and 5 OSSEOTITE® implants (3i/implant Innovations, Florida, USA) were placed at anterior region and they were positioned vertically at the same level of bony scallop of adjacent teeth. Whenever there was no lesion or labial bone was intact, immediate placement was tried as possible as it could be. Generated bone regeneration was done in the patients with the deficiency of hard tissue using Bio-Oss® (Geistlich, Wolhusen, Switzerland) and Bio-Gide® (Geistlich, Wolhusen, Switzerland). Second surgery was done in 6 months after implant placement and provisionalization was done for 3 months. Definite abutment was made of titanium abutment with porcelain, gold and zirconia, and was attached after provisionalization. Two-dimensional slices were created to produce sagittal, coronal, axial and 3D by using OnDemand3D (Cybermed, Seoul, Korea). **RESULTS.** The mean value of bone resorption (distance from top of implant to labial bone) was 1.32 ± 0.86 mm and the mean thickness of labial bone was 1.91 ± 0.45 mm. **CONCLUSION.** It is suggested that the thickness more than 1.91 mm could reduce the amount and incidence of resorption of labial bone in maxillary anterior implant. [J Adv Prosthodont 2011;3:85-9]

KEY WORDS. Implant, Labial bone, Bone resorption, Cone beam computed tomography

INTRODUCTION

When implants are placed in the maxillary anterior area, aesthetics is the most considerable factor. But it is quite difficult to get an aesthetic result in the maxillary anterior area.

The primary reasons are not only the lack of alveolar bone of maxillary anterior portion and gingiva but also the histological and morphological difference of implant with natural tooth.^{1,2} In order to overcome these problems, both soft / hard tissue augmentation and abutment development, like as customized abutment and ceramic abutment, are being considered, which is contributed to esthetic enhancement.³⁻⁸

In terms of aesthetics, there are still problems such as gingival recession by bone resorption after implant placement or alveolar bone resorption. Many papers were already reported on gingival recession and bone resorption after implant placement or abutment and crown connection.⁹⁻¹⁵ Under the actual clinical situations, just after implant placement or prosthodontic restoration some parts of implant abutment or implant itself might be occasionally exposed due to alveolus or gingival recession.

Oh *et al.*¹⁵ reported that trauma during the treatment, occlusal force, peri-implantitis, microgap, biological width and crestal module are responsible for the bone resorption. Hermann *et al.*¹⁶

emphasized the microgap around restoration margins, which allowed germs and other bacteria to infiltrate implant screw damaging tissues surrounding implants.^{17,18} Broggin *et al.*¹⁹ also notified that inflammation lasted in the contact part between fixture and abutment. Others also informed biologic width was the major factor inducing bone resorption.²⁰⁻²² Lindquist *et al.*⁹ mentioned smoking and bad oral hygiene. According to many results, bone resorption is induced not because of specific factors but because of comprehensive causes.

Level of bone resorption varies to some extent after implant second surgery or abutment connection. It is about 1.5 - 2.0 mm and never exceeds 2 mm in 1 year. Under 0.2 mm a year is regarded as an implant success.²³

Radiographic results were used for the evaluation - same radiography in comparison with several pictures and standard measurement of a specific site on implant or using computer program.^{24,25} These methods determined mesiodistal bone resorption surrounding implants. This is because general radiography did not show the buccolingual resorption. Most clinical reports just introduced gingival recession and periodontal indexes not a bone resorption. Some histological results on animal experiments were reported to evaluate labial bone recession when it comes to aesthetics. But there is not any papers

Corresponding author: Hee-Jung Kim

Department of Prosthodontics, School of Dentistry, Chosun University,

421 Soesuk-dong, Dongk-gu, Gwangju, 520-825, Korea

Tel. 82 62 230-3829; e-mail, khjdds@chosun.ac.kr

Received April 28, 2011 / Last Revision May 2, 2011 / Accepted May 4, 2011

© 2011 The Korean Academy of Prosthodontics

This is an Open Access article distributed under the terms of the Creative Commons Attribution Non-Commercial License (<http://creativecommons.org/licenses/by-nc/3.0>) which permits unrestricted non-commercial use, distribution, and reproduction in any medium, provided the original work is properly cited.

*This study was supported by research funds from Chosun University, 2009.

reported on the change of labial bone when implants placed measured by cone beam computed tomography (CBCT).

The purpose of this study is to evaluate the change, the amount of resorption and thickness of labial bone in anterior maxillary implants using CBCT.

MATERIALS AND METHODS

Materials

Twenty-one patients with 26 implants were followed up and checked with CBCT on the second visit after prosthodontic restoration. Patient consents were obtained. 21 OSSEOTITE NT[®] and 5 OSSEOTITE[®] were placed at anterior region during 2003 to 2007. Average age for 14 males and 7 females was 36.7 years. Sites for implants were 14 maxillary central incisors, 10 maxillary lateral incisors and 2 canines. It took about 3 years and 1 month after implant placement (during 2003 to 2007) to take CBCT.

Immediate placement was considered on the condition of neither inflammation factors nor labial bone resorption. In terms of damage on labial bone or severe resorption of residual bone, bone augmentation was conducted. Most patients had anterior teeth fractures owing to trauma, among them 3 cases - 4 implants - were immediate placement. The others were placed after healing of extraction area. In case of thin labial bone or transparent view of implant screw thread through bone as well as perforation of labial bone, the operation of guided bone regeneration (GBR) was done. Bio-Oss and Bio-Gide were used in all GBR cases. Implant platform was positioned vertically at the same level of bony scallop of adjacent teeth. These platforms were the criteria of labial bone measurement. Second

surgery was done in 6 months after implant placement. 6 weeks later, impression was taken; and provisional restoration with acrylic resin was mounted for 3 months. Final impression was taken and definite abutment and restoration were fabricated.

Methods

1) Measurement of labial bone loss and width

HITACHI CB[®] is used to evaluate the labial bone of implant in maxillary anterior part. Scanner is used at 120 KV, 15 mA, 1 time, and 9.6 seconds. OnDemand3D (Cybermed, Seoul, Korea) program is also used for image reconstruction and analysis.

Firstly, it is needed to set the measurement criteria for labial bone loss. When implant placed, implant platform was positioned vertically at the same level of bony scallop of adjacent teeth. This became a baseline (Fig. 1b, 2b). To determinate the base line or original height of labial bone in CBCT, the length of the placed implant from apex was measured. (Fig. 1) In Fig. 2, L1 is original height of labial bone and L2 is that after bone resorption.

After the platform baseline was determined, labial bone existence with its position were checked out on the axial view through top to apex in CBCT (Fig. 3). In order to rule out the artifact effect, the continuity of labial bone in CBCT between adjacent teeth was considered, which was accepted only it was clear and distinct (Fig. 3).

After examining the residual part of labial bone (C), on the axial view, length from apex to the residual labial bone (L2) was measured in CBCT (Fig. 4).

After residual bone position and bone loss were measured,

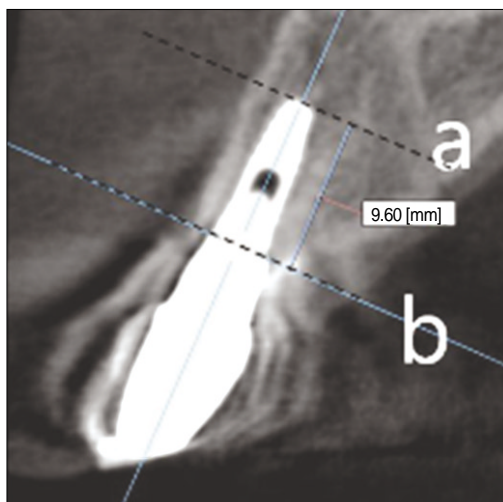


Fig. 1. Determination of the position of platform (Baseline). a: Apex of implant, b: platform of implant, a - b: length of implant.

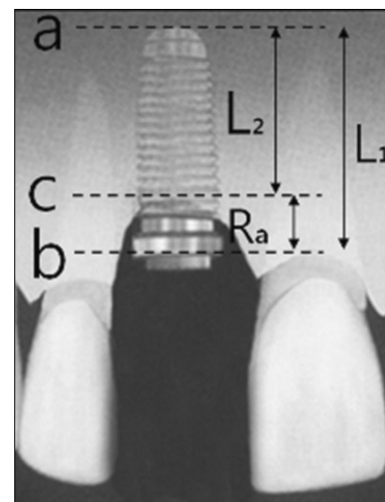


Fig. 2. Measurement of the amount of labial bone loss. a: apex of implant, b: platform of implant, c: position of labial bone, L1: length of implant, L2: length from apex to labial bone, Ra (= L1 - L2): the amount of labial bone loss.

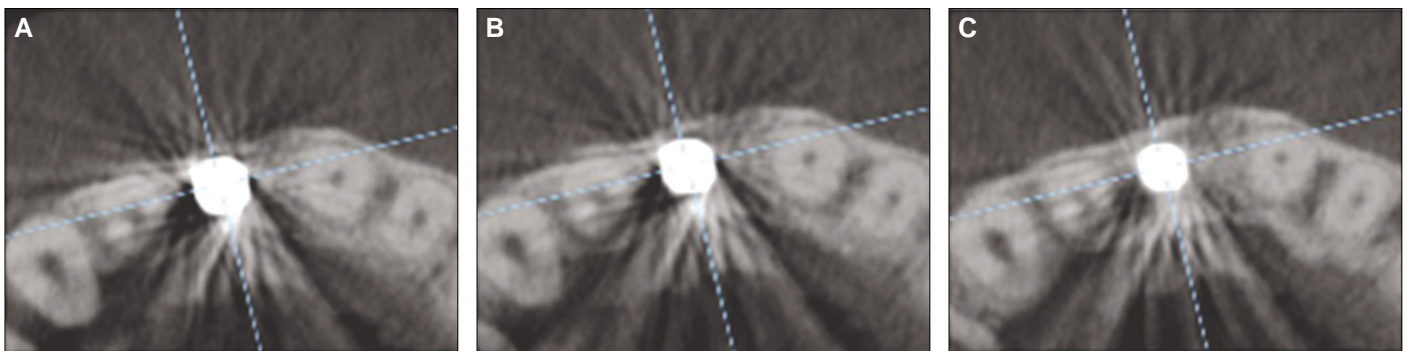


Fig. 3. Determination of the existence of labial bone. A: absence of labial bone, B: labial bone seemed to exist but indistinct, C: labial bone and continuity of labial bone with adjacent tooth were clear (distinct).

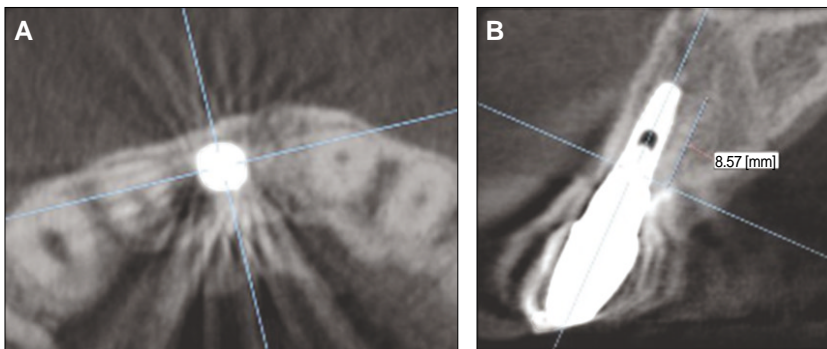


Fig. 4. Determination of the position of labial bone. A: clear labial bone and its continuity, B: the position of labial bone at (A), L2 minus L1 means the amount of labial bone loss in CBCT.

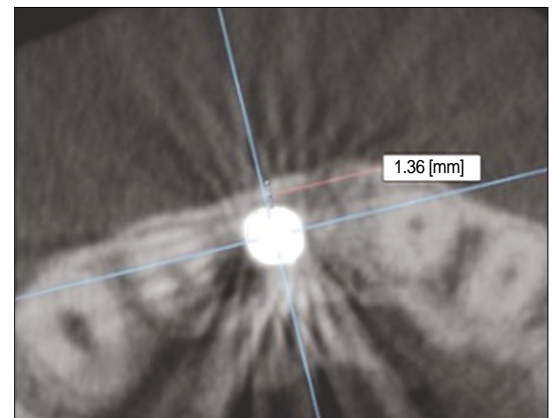


Fig. 5. Measurement of the thickness of labial bone.

thickness of labial bone was detected. The width of labial bone was counted from implant to lateral border of residual labial bone on the axial view (Fig. 5).

RESULTS

Among 26 implants placed in maxillary anterior part, only 17 had a labial bone on the top 1/3 of implants. The nine implants showed severe labial bone resorption to apex of implant or perforation of labial bone. The mean value of resorption of labial bone (from the platform of implant to residual bone) in 17 cases, was 1.32 ± 0.86 mm. The least level was 0.08 mm, and the most severe level was 2.47 mm. In cases that residual bone existed on the top 1/3 of implant, the average thickness of labial bone was 1.91 ± 0.45 mm, the thinnest 1.27 mm, the thickest 2.66 mm.

DISCUSSION

CBCT was used to measure the labial bone resorption and level of residual alveolar bone. CBCT has advantages such as less exposure time than general CT, less X-ray radiation and

the accuracy of radiographic images.²⁶ For these reasons CBCT is more popular in particularly detection of diseases or lesions on orofacial part, the evaluation of pre/post fracture surgery, evaluation of temporomandibular joint (TMJ) and primary diagnostic criteria of implant treatment plan in dental fields.²⁶

Generally, CBCT has a good reputation to reduce the artifact induced by metal using revising algorithms. However, it also has an artifact as well. Due to this reason, no attempt was done to evaluate the buccolingual bone of the implant placement site. Draenert *et al.*²⁷ reported that CBCT had more artifacts around implants than multidetector MDCT did. The main causes were wide cone angle and lack of revising algorithms. Nevertheless, the images by MDCT had less sharpness and artifact compared to latest CBCT images. According to his report precise distinctions were possible more than in 90%. But images taken by MDCT were almost similar to those taken by CBCT and Ondemand3D program. That's because the latest CBCT and revising algorithms were more advanced. When the artifacts were severe, the evaluation of labial bone was undetectable. However, the more advanced the techniques were, the less artifacts prominently produced. Considering that the artifact by implants had tendency of vertically radial shape, labi-

al bone and clear continuity of labial bone with adjacent tooth became the baseline. It was estimated that actual residual bone would exist closer to the apex than the baseline.

Only 17 implants were selected to evaluate the change of labial bone of implant which showed clinically successful or acceptable results. The other 9 were considered as a failure. They showed the apical perforation or severe resorption in labial bone. Among 26 implants placed in maxillary anterior part, 17 had a labial bone on the top 1/3 of implants, which meant approximately 65.38%. There was a considerable difference of general implants success rate which was already known as more than 90%.^{28,29} The causes were like higher failure rate of maxillary anterior implant placement and more technique-sensitive procedure. Also in most cases of no labial bone on top 1/3, they had a tendency of continuous narrow bone loss like craters from platform to apex. But they were rarely detected only by clinical examinations and the standard radiographic images. The overall success rate included all cases like this, which led to higher success rate. On applying to clinical examinations and standard radiographic images, the success rate reached 96%. This had no difference of typical success rate.

17 cases reported residual labial bone existed had it that the average length was 1.32 ± 0.86 mm, in 3.1 years after placement. Lindquist *et al.*⁹ carried out the prospective study on bone loss of initial implant placement for 15 years. They reported 0.5 mm of resorption in the first year and 0.05 mm every year in the condition of mandible edentulous state. There is a difference between the result of us and that of Lindquist. This can be attributed to two factors, one is the difference of position of implant placement and the other is that of measurement site of bone loss. Their research evaluated the amount of bone loss at the mesial and distal of implant in full edentulous mandible with hybrid denture. However, the two considerations, which one is that they reported two times more resorptive pattern in lower anterior part than lower posterior one and they evaluated only mesiodistal site of implants, and the other is that timing of our research was in mean 3.1 years after implant placement, could make such a difference acceptable.

Esposito *et al.*³⁰ reported that in case of single implant, bone resorption 3 years after implant placement had a difference of 0.97 mm when compared between pre-operation and crown setting, and 0.32 mm for 3 years after crown setting. This paper also showed more resorptive pattern in anterior part than posterior one, specifically 1.01 mm of bone loss from pre-operation to crown setting. Although this figure was measured from the mesiodistal of implant to the CEJ of adjacent teeth, just considering bone resorption the result was 1.29 - 1.33 mm. This was approximately similar to the result of this paper. Particularly Esposito's experiment was similar to method using external connection system.³⁰ Internal connection system presented marginal bone resorption as well and it happened at early stage after

implant surgery.^{22,31} Hånggi *et al.*³¹ using internal hexa connection reported that causes of initial bone resorption were the biologic width and the microgap between implant and abutment. And most resorption took place without occlusal force at an initial state. Concerning this experiment and previous experiment reported, buccolingual resorption would happen similar to mesiodistal pattern and the similar loss level as well.

Average bone thickness measured by OnDemand3D program was 1.91 ± 0.45 mm. This showed a considerable difference from that of the labial bone of natural tooth by CBCT, which was estimated less than 1 mm. This data would be quite practical to determine whether the bone augmentation would be done or not and to establish the amount of labial bone necessary for placement of implant in anterior region. The existing labial bone means that if bone level maintained, labial bone resorption and changes would not happen. There was not any report on the thickness of labial bone 3 years after implant placement. However, more studies showed the implant failure and reaction of labial bone on implant placement. Spray *et al.*³² observed the change of labial bone at second surgery after measuring thickness of labial bone as implant placed. According to the paper, average thickness of labial bone was 1.7 mm at implant placement. When second surgery was done, mean bone resorption was 0.7 mm. There was no statistically significant difference in the rate of implant failure, comparing less than 1 mm and 1 - 2 mm of labial bone thickness, however, significantly less implant failure when more than 2 mm of labial bone thickness. Resorptive pattern of labial bone was as followed: the most prominent resorptive pattern in less than 1 - 1.4 mm of labial bone thickness, reduction of resorption level in 1.4 - 1.7 mm, remarkable reduction of resorption or no change in more than 1.8 mm and also had a possibility of bone formation. They suggested that the critical thickness should be 2 mm for the reduction of labial bone resorption and the frequency of bone loss. 2 mm of the critical value that they suggested is similar to the result of this experiment. However, there is a difference in the amount of labial bone resorption between Spray's result 32 and ours one. The mean bone loss of this experiment was 1.32 mm and Spray's, 0.7 mm. This difference compared to Spray's experiments³² came from those factors such as different sites of implant placement - anterior part, measurement time - not at the time of second surgery but of 2 years after final restoration. We had a similar result with more than 1.91 mm of labial bone thickness, 0.88 mm bone loss occurred and with less than 1.91 mm thickness, 1.64 mm bone loss was evident. This meant the clinical thickness was 1.91, which presented similarity.

The minimum bone width for the implant placement used to be more than 1 mm and recently the width became at least more than 1.5 mm than the diameter of implant. Considering the result of this study and Spray's one, however, it is suggested that the minimum change of marginal bone may happened only if labi-

al bone existed more than 2 mm not than the diameter of implant but to the labial side of implant.

CONCLUSION

The purpose of this study was to evaluate the amount of resorption and thickness of labial bone in anterior maxillary implant (average 3.1 years, 2003 - 2007) using Con Beam Computed Tomography. 21 patients with 26 implants were followed up and among 26 implants, 17 cases reported residual labial bone existed on top 1/3 were measured for the resorption and the thickness of labial bone. The results were as followed:

- the average bone resorption of maxillary anterior implant was 1.32 ± 0.86 (0.08 - 2.47) mm and the average thickness of residual labial bone was 1.91 ± 0.45 (1.27 - 2.66) mm.

The result would contribute to determine the thickness of labial bone on implant placement. According to result, approximately more than 2 mm minimized the change and the resorption of labial bone in maxillary anterior implants.

REFERENCES

- Garber DA. The esthetic dental implant: letting restoration be the guide. *J Oral Implantol* 1996;22:45-50.
- Tarnow DP, Eskow RN, Zamzok J. Aesthetics and implant dentistry. *Periodontol* 2000 1996;11:85-94.
- Becker W, Becker BE. Guided tissue regeneration for implants placed into extraction sockets and for implant dehiscences: surgical techniques and case report. *Int J Periodontics Restorative Dent* 1990;10:376-91.
- Bahat O, Fontanesi RV, Preston J. Reconstruction of the hard and soft tissues for optimal placement of osseointegrated implants. *Int J Periodontics Restorative Dent* 1993;13:255-75.
- Kan JY, Rungcharassaeng K. Site development for anterior single implant esthetics: the dentulous site. *Compend Contin Educ Dent* 2001;22:221-6, 228, 230-1.
- Wöhrle PS. Nobel Perfect esthetic scalloped implant: rationale for a new design. *Clin Implant Dent Relat Res* 2003;5:64-73.
- Lazzara RJ, Porter SS. Platform switching: a new concept in implant dentistry for controlling postrestorative crestal bone levels. *Int J Periodontics Restorative Dent* 2006;26:9-17.
- Schrotenboer J, Tsao YP, Kinariwala V, Wang HL. Effect of microthreads and platform switching on crestal bone stress levels: a finite element analysis. *J Periodontol* 2008;79:2166-72.
- Lindquist LW, Carlsson GE, Jemt T. A prospective 15-year follow-up study of mandibular fixed prostheses supported by osseointegrated implants. Clinical results and marginal bone loss. *Clin Oral Implants Res* 1996;7:329-36.
- Jung YC, Han CH, Lee KW. A 1-year radiographic evaluation of marginal bone around dental implants. *Int J Oral Maxillofac Implants* 1996;11:811-8.
- Small PN, Tarnow DP. Gingival recession around implants: a 1-year longitudinal prospective study. *Int J Oral Maxillofac Implants* 2000;15:527-32.
- Bengazi F, Wennström JL, Lekholm U. Recession of the soft tissue margin at oral implants. A 2-year longitudinal prospective study. *Clin Oral Implants Res* 1996;7:303-10.
- Cecchinato D, Bengazi F, Blasi G, Botticelli D, Cardarelli I, Gualini F. Bone level alterations at implants placed in the posterior segments of the dentition: outcome of submerged/non-submerged healing. A 5-year multicenter, randomized, controlled clinical trial. *Clin Oral Implants Res* 2008;19:429-31.
- Albrektsson T, Zarb G, Worthington P, Eriksson AR. The long-term efficacy of currently used dental implants: a review and proposed criteria of success. *Int J Oral Maxillofac Implants* 1986;1:11-25.
- Oh TJ, Yoon J, Misch CE, Wang HL. The causes of early implant bone loss: myth or science? *J Periodontol* 2002;73:322-33.
- Hermann JS, Schoolfield JD, Nummikoski PV, Buser D, Schenk RK, Cochran DL. Crestal bone changes around titanium implants: a methodologic study comparing linear radiographic with histometric measurements. *Int J Oral Maxillofac Implants* 2001;16:475-85.
- Persson LG, Lekholm U, Leonhardt A, Dahlén G, Lindhe J. Bacterial colonization on internal surfaces of Brånemark system implant components. *Clin Oral Implants Res* 1996;7:90-5.
- Guindy JS, Besimo CE, Besimo R, Schiel H, Meyer J. Bacterial leakage into and from prefabricated screw-retained implant-borne crowns in vitro. *J Oral Rehabil* 1998;25:403-8.
- Broggini N, McManus LM, Hermann JS, Medina RU, Oates TW, Schenk RK, Buser D, Mellonig JT, Cochran DL. Persistent acute inflammation at the implant-abutment interface. *J Dent Res* 2003;82:232-7.
- Cochran DL, Hermann JS, Schenk RK, Higginbottom FL, Buser D. Biologic width around titanium implants. A histometric analysis of the implant-to-gingival junction around unloaded and loaded nonsubmerged implants in the canine mandible. *J Periodontol* 1997;68:186-98.
- Hermann JS, Buser D, Schenk RK, Higginbottom FL, Cochran DL. Biologic width around titanium implants. A physiologically formed and stable dimension over time. *Clin Oral Implants Res* 2000;11:1-11.
- Hermann JS, Buser D, Schenk RK, Schoolfield JD, Cochran DL. Biologic Width around one- and two-piece titanium implants. *Clin Oral Implants Res* 2001;12:559-71.
- Abrahamsson I, Berglundh T, Lindhe J. The mucosal barrier following abutment dis/reconnection. An experimental study in dogs. *J Clin Periodontol* 1997;24:568-72.
- Benkow HH. A new principle and appliance for radiographic tooth measurements. *J Dent Res* 1957;36:641-3.
- Rosling B, Hollender L, Nyman S, Olsson G. A radiographic method for assessing changes in alveolar bone height following periodontal therapy. *J Clin Periodontol* 1975;2:211-7.
- Scarfe WC, Farman AG, Sukovic P. Clinical applications of cone-beam computed tomography in dental practice. *J Can Dent Assoc* 2006;72:75-80.
- Draenert FG, Coppentrath E, Herzog P, Müller S, Mueller-Lisse UG. Beam hardening artefacts occur in dental implant scans with the NewTom cone beam CT but not with the dental 4-row multidetector CT. *Dentomaxillofac Radiol* 2007;36:198-203.
- Davarpanah M, Martinez H, Etienne D, Zabalegui I, Mattout P, Chiche F, Michel JF. A prospective multicenter evaluation of 1,583 3i implants: 1- to 5-year data. *Int J Oral Maxillofac Implants* 2002;17:820-8.
- Levin L, Pathael S, Dolev E, Schwartz-Arad D. Aesthetic versus surgical success of single dental implants: 1- to 9-year follow-up. *Pract Proced Aesthet Dent* 2005;17:533-8.
- Esposito M, Ekkestubbe A, Gröndahl K. Radiological evaluation of marginal bone loss at tooth surfaces facing single Brånemark implants. *Clin Oral Implants Res* 1993;4:151-7.
- Hänggi MP, Hänggi DC, Schoolfield JD, Meyer J, Cochran DL, Hermann JS. Crestal bone changes around titanium implants. Part I: A retrospective radiographic evaluation in humans comparing two non-submerged implant designs with different machined collar lengths. *J Periodontol* 2005;76:791-802.
- Spray JR, Black CG, Morris HF, Ochi S. The influence of bone thickness on facial marginal bone response: stage 1 placement through stage 2 uncovering. *Ann Periodontol* 2000;5:119-28.