

## 발뒤꿈치의 재건 시에 사용할 수 있는 다양한 피판술

정연익 · 이동원 · 윤인식 · 나동균 · 이원재  
연세대학교 의과대학 성형외과학교실·인체조직복원연구소

### Various Modalities of Flap Surgery in Heel Pad Reconstruction

Yun Ik Jung, M.D., Dong Won Lee, M.D., In Sik Yoon, M.D.,  
Dong Kyun Rah, M.D., Ph.D., Won Jai Lee, M.D., Ph.D.

Institute for Human Tissue Restoration, Department of  
Plastic & Reconstructive Surgery, Yonsei University, College  
of Medicine, Seoul, Korea

**Purpose:** The reconstruction of a soft tissue defect of the heel pad can be challenging. One vital issue is the restoration of the ability of the heel to bear the load of the body weight. Many surgeons prefer to use local flaps or free tissue transfer rather than a skin graft. In this study, we evaluated the criteria for choosing a proper flap for heel pad reconstruction.

**Methods:** In this study, 23 cases of heel pad reconstruction were performed by using the flap technique. The etiologies of the heel defects included pressure sores, trauma, or wide excision of a malignant tumor. During the operation, the location, size and depth of the heel pad defect determined which flap was chosen. When the defect size was relatively small and the defect depth was limited to the subcutaneous layer, a local flap was used. A free flap was selected when the defect was so large and deep that almost entire heel pad had to be replaced.

**Results:** There was only one complication of poor graft acceptance, involving partial flap necrosis. This patient experienced complete recovery after debridement of the necrotic tissue and a split thickness skin graft. None of the other transferred tissues had complications. During the follow-up period, the patients were reported satisfactory with both aesthetic and functional results.

**Conclusion:** The heel pad reconstructive method is determined by the size and soft-tissue requirements of the defect. The proper choice of the donor flap allows to

achieve satisfactory surgical outcomes in aesthetic and functional viewpoints with fewer complications.

**Key Words:** Heel pad reconstruction, Flap surgery

### I. INTRODUCTION

The epidermal and dermal layers of the heel pad are thicker than those of any other parts of the body. The subcutaneous fat tissue in this area is affixed to the periosteum and planter fascia of the calcaneous bone with firm vertical structured fibrous septa. This unique structure of the sole enables it not only to withstand not only shearing forces, but also to support the body weight during walking or standing.<sup>1,2</sup> Therefore, we need to consider these characteristics of the sole when we choose the modality of reconstruction for soft tissue defects of the heel pad.

It is known that a much better reconstruction can be achieved by using a local flap of tissue from the non-weight-bearing portion of the sole or a free flap that uses distant fasciocutaneous tissue or muscle tissue combined with a skin graft. They offer a superior result compared with that of a simple skin graft.<sup>3-8</sup>

Numerous factors must be considered in the choice of donor flap, including not only the size and depth of the defect, but also the presence of an available recipient pedicle. Furthermore, the degree of viability of the tissue surrounding the defect is also important when the ideal flap is chosen. In most cases, it is difficult to choose the proper donor flap because the indications are not always clear, and the experiences of the surgeon are often used as a basis for decision-making.

In this study, the authors suggest the criteria of donor flap choice for heel pad reconstruction based on our experiences.

### II. MATERIALS AND METHODS

#### A. Subjects

From November 2005 to December 2010, 23 patients

Received March 18  
Revised April 25, 2011  
Accepted April 26, 2011

**Address Correspondence:** Won Jai Lee, M.D., Ph.D., Department  
of Plastic & Reconstructive Surgery, Yonsei University  
College of Medicine, Seoul 120-752, Korea. Tel: 02) 2228-  
2219/Fax: 02) 393-6947/E-mail: pswjlee@yuhs.ac

\* 본 논문은 2009년 제 67차 대한성형외과학회 추계학술대회에서  
구연되었음.

that had a soft tissue defect on the heel pad area were selected for inclusion in this retrospective study. These defects were caused by trauma, pressure sore, or wide excision of a tumor.

The average age of the subjects was 45 years, and the defect sizes were various from 4 × 4 cm to 15 × 10 cm. The depth of the defects varied from the subcutaneous layer to the deep fascia or bone exposure. The defects could not be recovered using a primary repair or simple skin graft. The flaps in our reconstruction were chosen depending on the defect size and depth. The average period of follow-up after surgery was about 13.3 months (Table I).

Preoperative evaluation was performed about labo-

ratory study and patient factors of medical history which could increase postoperative complication related to free flap surgery. High risk patients taking the operative failure with the consequence of donor site morbidity were excluded.

Lower extremity angiography was performed in all patients, and directional doppler tracing was conducted to determine the flow of arterial blood. Those patients who had a concomitant open fracture of the calcaneus bone underwent reconstruction after fracture union. If the wound was accompanied by a chronic infection or osteomyelitis, these conditions were successfully treated with antibiotics, as confirmed via wound culture. After effective debridement, the reconstructive operation was

**Table I.** Patient Characteristics.

No.	Cause	Size (cm)	Depth	F/U (month)	Flap
1	Pressure sore	5 × 3	SQ	6	Adipofascial flap
2	Pressure sore	4 × 4	SQ	12	Adipofascial flap
3	Pressure sore	5 × 5	SQ	8	Adipofascial flap
4	Pressure sore	4 × 3	SQ	2	Adipofascial flap
5	Pressure sore	5 × 4	SQ	2	Adipofascial flap
6	Malignant melanoma	6 × 5	SQ	10	Medial plantar flap
7	Unstable scar	8 × 4	SQ	3	Medial plantar flap
8	Malignant melanoma	7 × 8	SQ	23	Medial plantar flap
9	Malignant melanoma	8 × 8	SQ	14	Medial plantar flap
10	Soft tissue defect	8 × 7	SQ	19	Medial plantar flap
11*	Scar contracture	14 × 5	SQ	8	Medial plantar flap
12	Soft tissue defect	8 × 7	SQ	22	Medial plantar flap
13	Soft tissue defect	9 × 6	Bone	13	ALT free flap
14	Scar contracture	10 × 6	Bone	11	ALT free flap
15	Pressure sore	10 × 6	Bone	8	ALT free flap
16	Soft tissue defect	14 × 7	SQ	16	ALT free flap
17 <sup>*,†</sup>	Soft tissue defect	15 × 6	Bone	16	ALT free flap
18 <sup>†</sup>	Squamous cell ca.	9 × 8	Bone	14	ALT free flap
19	Soft tissue defect	10 × 5	Bone	5	ALT free flap
20	Soft tissue defect	9 × 6	SQ	5	ALT free flap
21	Malignant melanoma	10 × 10	Bone	24	LD muscle free flap + STSG
22 <sup>†</sup>	Soft tissue defect	15 × 10	Bone	35	LD muscle free flap + STSG
23	Malignant melanoma	15 × 10	Bone	30	LD muscle free flap + STSG

SQ, subcutaneous; ALT, anterolateral thigh; LD, latissimus dorsi; STSG, split thickness skin graft.

\*: Partial flap necrosis, †: Anterolateral thigh flap was elevated, involving vastus lateralis muscle, ‡: Debulking procedure was performed.

performed.

### B. Indication of the flap selection

The choice of flap was made based on the defect size and depth.

A local flap was chosen when the defect was small. If the defect size was large or included the muscle or bone layer, a free flap was used. An adipofascial flap or a medial planter artery perforator flap was used for a local flap. If needed, a latissimus dorsi muscle flap was used as a free muscle flap, while an anterolateral thigh flap was used as a free fasciocutaneous flap.

We used the adipofascial local flap for the reconstruction of defects smaller than about  $25\text{ cm}^2$  with a superficial depth. We chose the medial planter artery perforator local flap when the area of the defect was larger than about  $25\text{ cm}^2$  and was confined to the subcutaneous layer with the length of the long axis being shorter than about 9 cm. We used an anterolateral thigh fasciocutaneous free flap if the long axis was longer than 9 cm or if the defect penetrated deeper than the subcutaneous layer over a large area. When there was a more extensive defect area of approximately  $100\text{ cm}^2$ , a latissimus dorsi muscle free flap and a split thickness skin graft were used for reconstruction (Fig. 1).

## III. RESULTS

The results of the heel pad reconstructions of the 23 patients demonstrated no major complications, except the one patient that had partial flap necrosis. Some patients had mild congestion along the flap margin, but they recovered without any aggravation of the conges-

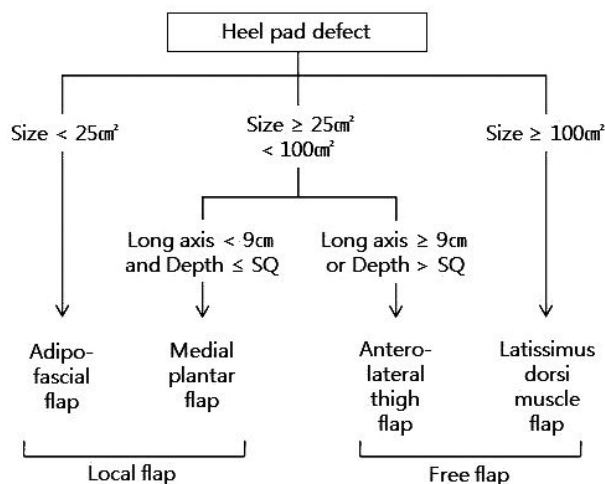


Fig. 1. Indications of the flap selection in this study.

tion or necrotic change in the congested tissue. The period of follow-up ranged from 3 to 35 months.

One patient (case 11) had partial necrosis over nearly the entire flap area. This necrosis was treated with wet dressings to prevent infections or aggravation of the necrosis. The necrotic tissue was then debrided, and the defect was completely covered with a split thickness skin graft.

Two patients with excessive flap volume complained of discomfort when they wore shoes or walked. This situation was corrected with a debulking procedure. The patients were satisfied with the results after volume reduction of the bulky flap.

In addition, all of the patients were satisfied with the cosmetic and functional results. Although it couldn't recover full sensation for every patients, there was no functional disability. Over the follow up period, there was no recurrence of the defect.

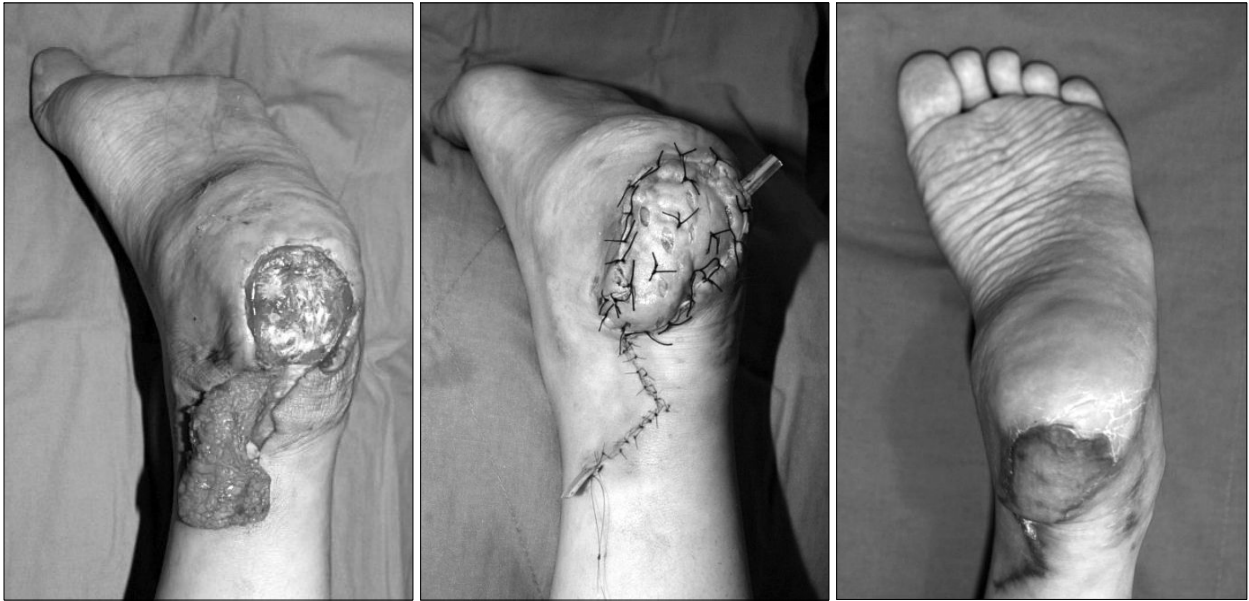## IV. DISCUSSION

In order to achieve an ideal result for heel pad reconstruction, accurate evaluations are needed before the surgery in order to determine the etiology of the heel pad disease. Second, a stable skeletal foot structure must be realized to properly support and distribute the body weight. Therefore, ostectomy of a bony process may be required. Third, sensate reconstruction should be undertaken if possible in order to preserve protective sensations.<sup>9,10</sup> The reconstruction should be performed with a fasciocutaneous or muscle flap of thick skin and sufficient subcutaneous tissue volume to allow the heel to withstand shearing force and the load of the body weight.

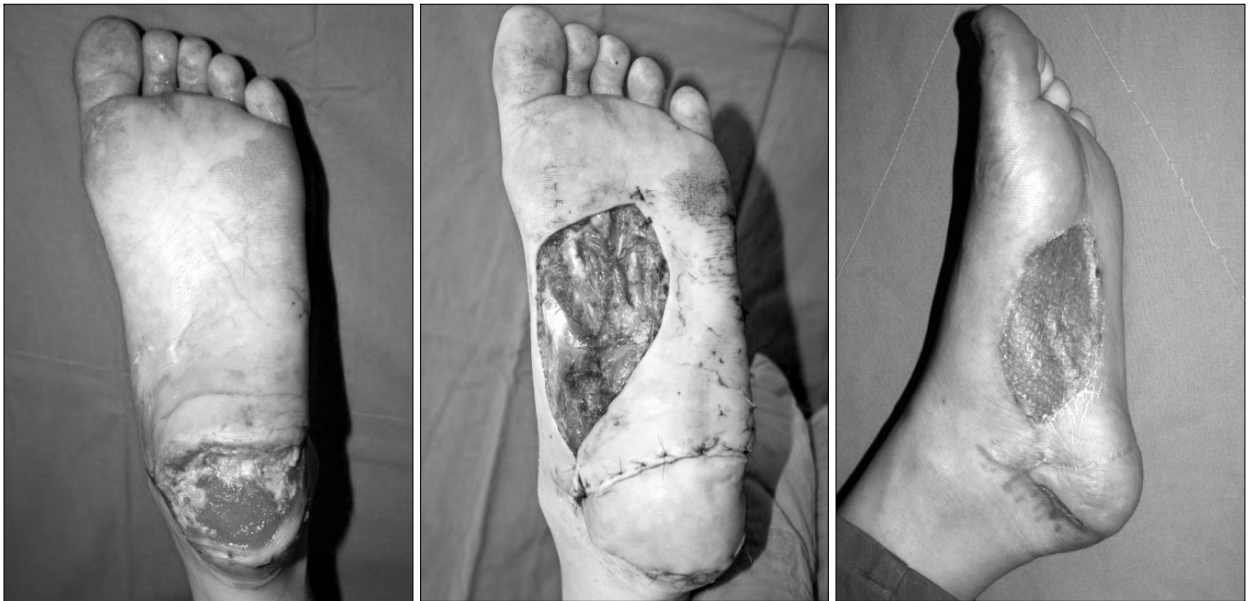The reconstructive method of a split or full thickness skin graft, local flap or free flap could be used for repair of a sole or heel pad defect. However, about half of patients treated with a split thickness skin graft for a defect on a weight-bearing area experience insufficient results that required additional reconstructive surgery.<sup>11</sup>

Full thickness skin grafts should be performed only on healthy and viable tissue surfaces. If there is insufficient soft tissue volume or exposure of the calcaneous bone or tendon accompanied by loss of the paratenon, a simple skin graft will be insufficient.<sup>11</sup> Thus, the authors preferentially considered flap surgery for heel pad reconstruction.

In cases with a small, superficial defect, it is sufficient to reconstruct the defect with a local adipofascial flap and to cover the skin defect with a split thickness skin



**Fig. 2.** Case 3. Adipofascial flap. (Left)  $5 \times 5$  cm soft tissue defect caused by a pressure sore. An incision was made in the medial malleolar area for elevation of the adipofascial tissue. (Center) An adipofascial flap was insetted and a split thickness skin graft was performed. (Right) POD 4 months.



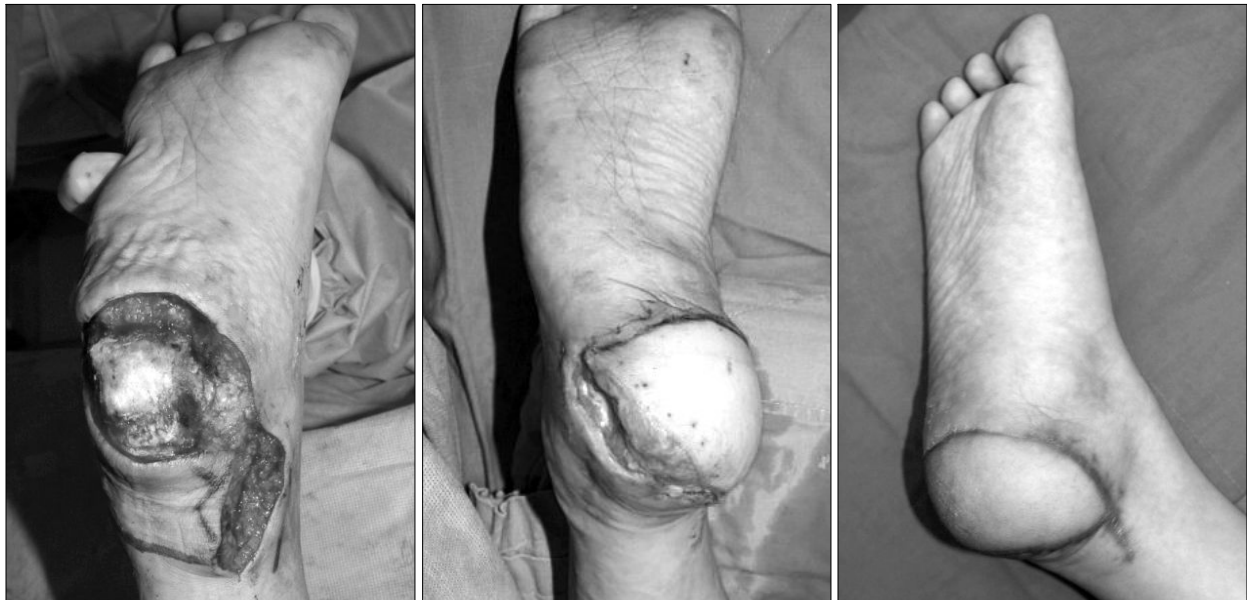**Fig. 3.** Case 12. Medial planter flap. (Left)  $8 \times 7$  cm soft tissue defect caused by trauma. (Center) A medial planter flap was elevated and placed over the defect. (Right) POD 4 months.

graft. This type of coverage can have a good result because much of the weight-bearing normal soft tissue around the defect still remains (Fig. 2).

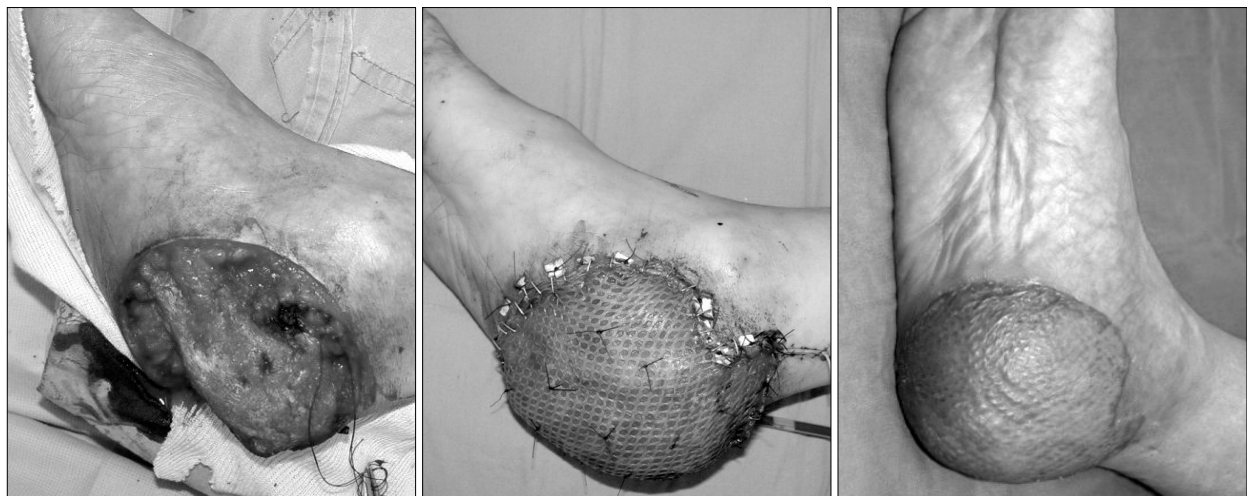
If the defect size was small, the depth was limited to the subcutaneous layer, and there was no damage to the surrounding tissue, the normal sole tissue that does not contact the ground can be used for reconstruction. The

use of the medial planter artery perforator flap could produce satisfactory functional results because the anatomic structure of the flap is similar to that of the heel pad involving the sensory nerve (Fig. 3).

When the defect was large with exposed bone or tendon, increased tissue area and volume are required. We preferred reconstruction with a free flap in these



**Fig. 4.** Case 15. Anterolateral thigh fasciocutaneous free flap. (Left)  $10 \times 6$  cm soft tissue defect caused by a pressure sore. An incision was made in the medial malleolar area in order to approach the pedicle. (Center) An anterolateral thigh flap was placed over the defect (Right) POD 4 months.



**Fig. 5.** Case 21. Latissimus dorsi muscle flap and split thickness skin graft. (Left)  $10 \times 10$  cm soft tissue defect after the wide excision of a malignant melanoma. (Center) A latissimus dorsi muscle flap was used and a split thickness skin graft was performed. (Right) POD 5 months.

circumstances. We used the anterolateral thigh fasciocutaneous free flap for a deep defect because a large volume was needed for reconstruction (Fig. 4). The vastus lateralis muscle could be included to supplement the volume, and the lateral femoral cutaneous sensory nerve could be used for recovery of sensation. If the defect was wide and deep, the volume was supplemented with the latissimus dorsi muscle flap, and the raw surface was covered with a split thickness skin graft. This surgical approach resulted in good coverage and acceptable

stability (Fig. 5). Though it is not possible to recover full sensation, it has been reported that muscle flap maintenance resistance to a shearing force is similar to that of the normal sole skin.<sup>12</sup> This supposition was confirmed in our study.

In general, it is known that the local flap surgery has advantages of reduced donor morbidity, lower complication rate, shorter operation time, and faster postoperative recovery compared with the free flap surgery. However, if a local flap was used for a larger defect, excessive

rotation or transposition could result in pedicle kinking. This compromise can cause congestion and necrosis. Therefore, using a free flap is beneficial for large and deep defects in the heel pad.

In addition to the reconstructive methods suggested here, intrinsic muscle flap or sural artery perforator fasciocutaneous flap could be used for small, superficial defects.<sup>13,14</sup> Also, a local subfascial V-Y advancement flap or rotation flap may be useful for smaller defects.<sup>15</sup>

## V. CONCLUSION

The reconstructive method used to repair heel pad defects is determined by the size and soft-tissue requirements of the defect. It is the proper choice of the donor flap that allows to obtain satisfactory results with fewer complications, leading to good surgical outcomes in aesthetic and functional viewpoints.

## REFERENCES

1. Noever G, Bruser P, Kohler L: Reconstruction of heel and sole defects by free flaps. *Plast Reconstr Surg* 78: 345, 1986
2. Kim DC, Kim SS, Ha DH, Yoo HJ, Lee DH: Reconstruction for the soft tissue defect of heel using free lateral arm neurosensory flap. *J Korean Microsurg Soc* 8: 15, 1999
3. Serafin D, Georgiade NG, Smith DH: Comparison of free flaps with pedicled flaps for coverage of defects of the leg or foot. *Plast Reconstr Surg* 59: 492, 1976
4. Ponten B: The fasciocutaneous flap: its use in soft tissue defects of the lower leg. *Br J Plast Surg* 34: 215, 1981
5. Rainer C, Schwabegger AH, Bauer T, Ninkovic M, Klestil T, Harpf C, Ninkovic MM: Free flap reconstruction of the foot. *Ann Plast Surg* 42: 595, 1999
6. Lee YJ, Ahn HC, Choi SS, Hwang WJ: Reversed adipofascial flap in lower leg: can it replace the free flap? *J Korean Soc Plast Reconstr Surg* 32: 100, 2005
7. Reddy V, Stevenson TR: MOC-PSSM CME Article: lower extremity reconstruction. *Plast Reconstr Surg* 121: 1, 2008
8. Lee JH, Lee JW, Koh JH, Seo DK, Choi JK, Oh SJ, Jang YC: The usability of various flaps for hindfoot reconstruction. *J Korean Soc Plast Reconstr Surg* 37: 136, 2010
9. Chang KN, DeArmond SJ, Buncke HJ Jr: Sensory reinnervation in microsurgical reconstruction of the heel. *Plast Reconstr Surg* 78: 652, 1986
10. Kuran I, Turgut G, Bas L, Ozkan T, Bayri O, Gulgonen A: Comparison between sensitive and nonsensitive free flaps in reconstruction of the heel and planter area. *Plast Reconstr Surg* 105: 574, 2000
11. Colen LB, Uroskie T Jr: Foot reconstruction. In Mathes SJ: *Plastic surgery*. 2nd ed, Philadelphia, Saunders Elsevier, 2006, p 1417
12. May JW, Halls MJ, Simon SR: Free microvascular muscle flaps with skin graft reconstruction of extensive defects of the foot: a clinical and gait analysis study. *Plast Reconstr Surg* 75: 627, 1985
13. Lee WJ, Yang EJ, Tark KC, Chung YK: Adipofascial turnover flap for reconstruction of the foot and ankle. *J Korean Soc Plast Reconstr Surg* 34: 440, 2007
14. Orr J, Kirk KL, Antunez V, Ficke J: Reverse sural artery flap for reconstruction of blast injuries of the foot and ankle. *Foot Ankle Int* 31: 59, 2010
15. Roblin P, Healy CM: Heel reconstruction with a medial plantar V-Y flap. *Plast Reconstr Surg* 119: 927, 2007