

Intrahepatic Splenosis Mimicking Liver Metastasis in a Patient with Gastric Cancer

Kyu Chul Kang, Gyu Seok Cho, Gui Ae Chung, Gil Ho Kang, Yong Jin Kim, Moon Soo Lee, Hee Kyung Kim¹, and Seong Jin Park²

Departments of Surgery, ¹Pathology, and ²Radiology, Soonchunhyang University College of Medicine, Bucheon, Korea

A 54 year old man was referred to our hospital with gastric cancer. The patient had a history of splenectomy and a left nephrectomy as a result of a traffic accident 15 years earlier. The endoscopic findings were advanced gastric cancer at the lower body of the stomach. Abdominal ultrasonography (USG) and magnetic resonance imaging demonstrated a metastatic nodule in the S2 segment of the liver. Eventually, the clinical stage was determined to be cT2cN1cM1 and a radical distal gastrectomy, lateral segmentectomy of the liver were performed. The histopathology findings confirmed the diagnosis of intrahepatic splenosis, omental splenosis. Hepatic splenosis is not rare in patients with a history of splenic trauma or splenectomy. Nevertheless, this is the first report describing a patient with gastric cancer and intrahepatic splenosis that was misinterpreted as a liver metastatic nodule. Intra-operative USG guided fine needle aspiration should be considered to avoid unnecessary liver resections in patients with a suspicious hepatic metastasis.

Key Words: Stomach neoplasms, Splenosis, Neoplasm metastasis, Liver

Introduction

Splenosis is defined as the heterotropic transplantation of splenic tissue onto the peritoneal and intrathoracic surfaces after splenic trauma or splenectomy, and this was first reported on in 1937 by Shaw and Shafi.(1) There is usually multiple autoimplantations of splenic fragments, and this can occur anyplace in the peritoneal cavity, but it commonly appears on the serosal surfaces of the intestine and mesentery, the omentum, the diaphragm and the pelvis. (2) Most cases of splenosis are asymptomatic; however, abdominal symptoms such as pain, recurring Felty syndrome and intestinal obstruction have been reported.(2-4) Most cases have been found incidentally during laparotomy or autopsy, but splenosis occurs in up to 67% of the patients with a history of traumatic splenic rupture.(5) Ectopic spleen implants may be multiple,(6) but a few

reports have demonstrated cases of an isolated hepatic location.(7,8)

The case reports about intrahepatic splenosis are still rare, and it is difficult to make the differential diagnosis of hepatic splenosis from hepatic adenoma, focal nodular hyperplasia, lymphoma, hemangioma and hepatocellular carcinoma.(9-11) Especially, there has been only one report of hepatic splenosis mimicking liver metastases from cancer of another organ in a patient with breast cancer.(12) We describe here a patient with gastric cancer and intrahepatic splenosis, and this was all misinterpreted to be liver metastatic nodules.

Case Report

A 54 old man was referred to us because gastric cancer was found on an annual health examination. The patient had a history of splenectomy and left nephrectomy due to a traffic accident 15 years ago and he had no abdominal discomfort or symptoms. The patient has no history of hepatitis and there was no liver parenchymal abnormality on the abdominal USG performed 7 years previously. On the physical examination, there was no remarkable finding except for a left paramedian incisional scar owing to the

Correspondence to: Gyu Seok Cho

Department of Surgery, Soonchunhyang University Bucheon Hospital, 1174, Jung-dong, Wonmi-gu, Bucheon 420-767, Korea

Tel: +82-32-621-5248, Fax: +82-32-621-5018

E-mail: gschogs@schbc.ac.kr

Received November 2, 2010

Accepted January 3, 2011

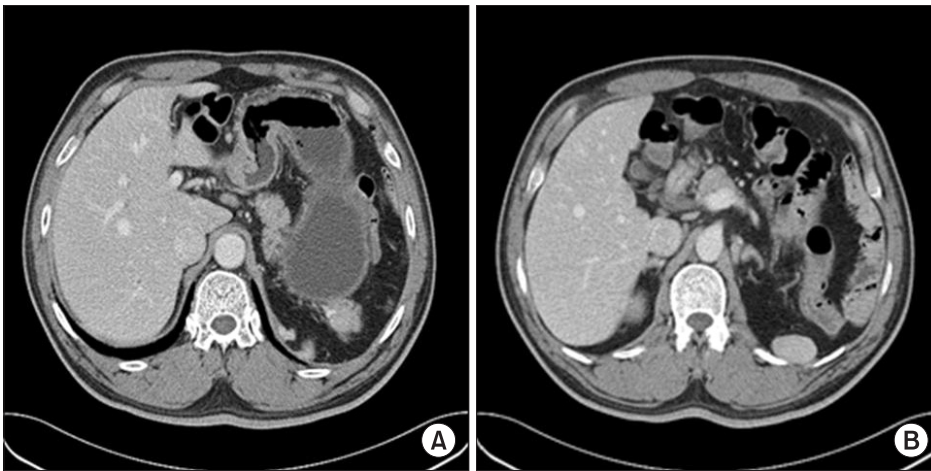


Fig. 1. The axial intravenous contrast enhanced CT scan (the portal venous phase image). (A) Note the wall thickening of the anterior wall of the antrum in the stomach and the lymph node enlargement in the perigastric area. (B) Note the 3.5×1.5 cm sized splenic tissue in the left subdiaphragmatic area with no supplying splenic vessel. CT = computed tomography.

previous operation.

The serum blood count and chemistry tests were within the normal ranges and the patient's serology for hepatitis B and C was negative. The level of carcinoembryonic antigen (CEA) and carcinoma antigen (CA) 19-9 was 0.87 ng/ml and 34.0 U/ml, respectively.

The endoscopic findings were Borrmann type 2 advanced gastric cancer at the angle of the anterior wall and it extended into the proper muscle layer (cT2 stage). The endoscopic biopsy results confirmed a moderately differentiated adenocarcinoma in the stomach. For the staging work-up, we performed abdomen pelvic enhanced computed tomography (CT), USG and positron emission tomography-computed tomography (PET-CT). The CT demonstrated wall thickening of the anterior wall of the antrum in the stomach, lymph node enlargement in the perigastric area (cN1 stage) and gall bladder stone. Small sized (3.5×1.5 cm) splenic tissue was seen on the CT scan in the left subdiaphragmatic area with no supplying splenic vessel (Fig. 1).

Interestingly, a CT scan revealed no parenchymal abnormality in the liver, and a PET-CT demonstrated no focal hypermetabolism in the stomach and liver. However, an abdomen US examination revealed a 2.5×1.7 cm sized nodular heterogenous hypoechoic lesion with clear margins in segment II of the liver (Fig. 2). Superparamagnetic iron oxide (SPIO) enhanced liver MRI was performed in order to confirm the presence of hepatic nodule. Liver MRI showed a 2.0×1.5 cm sized nodule in segment two of the liver with slightly high signal intensity on the T2-weighted image and low signal intensity on the T1-weighted image. This nodule still showed high signal intensity on the SPIO-enhanced T2 weighted image (Fig. 3).

We diagnosed the patient as having advanced gastric cancer with liver metastasis and gall bladder stone, and so we performed

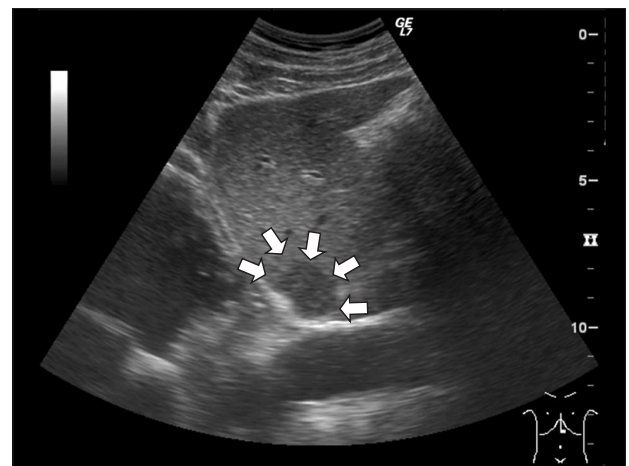


Fig. 2. Ultrasound revealed a 2.5×1.7 cm sized nodular heterogenous hypoechoic lesion with clear margins in segment two of the liver.

radical distal gastrectomy, including D2 lymph node dissection, liver lateral segmentectomy and cholecystectomy. During laparotomy, the external surface of the liver was smooth and glistening with one exofitic mass and during intraoperative USG, we found another round hypoechoic lesion in segment two of the liver parenchyma. On the multiple serial sections of the liver, there were two encapsulated red-blue nodules, measuring 2.3×1.9 cm and 0.7×0.6 cm, respectively, in segment II. They were located near the liver capsule (Fig. 4). The pathological examination of these lesions found a full component of red and white splenic pulp. These findings along with a history of splenectomy confirmed the diagnosis of hepatic splenosis with no evidence of metastasis (Fig. 5). The histopathologic diagnosis of the radical distal gastrectomy specimen confirmed early gastric cancer that had invaded the submucosa, lymph node metastasis in 4 out of the 44 harvested regional lymph nodes and omental splenosis. The patient was discharged without complication and he did not undergo adjuvant chemotherapy.

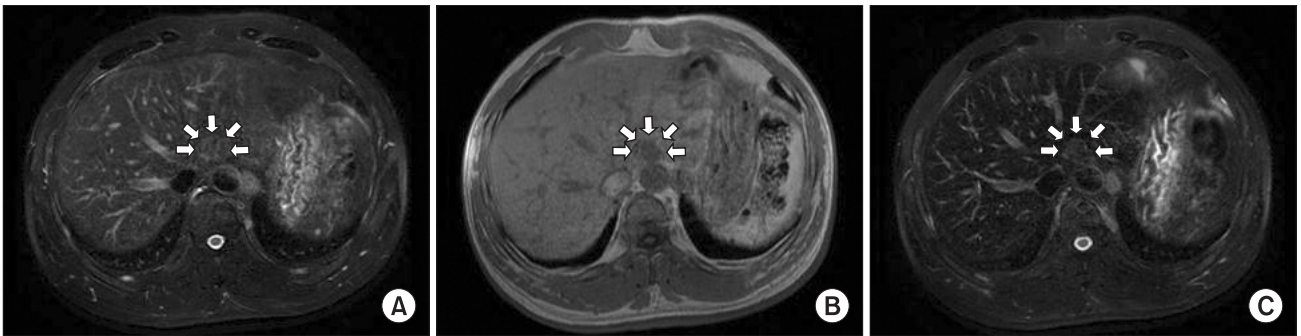

Fig. 3. Axial liver MRI. (A) there was a 2.0×1.5 cm sized nodule in segment two of the liver with slightly high signal intensity on the T2-weighted image and (B) low signal intensity on the T1-weighted image. This nodule still showed high signal intensity on the superparamagnetic iron oxide (SPIO) enhanced T2 weighted image (C). MRI = magnetic resonance imaging.

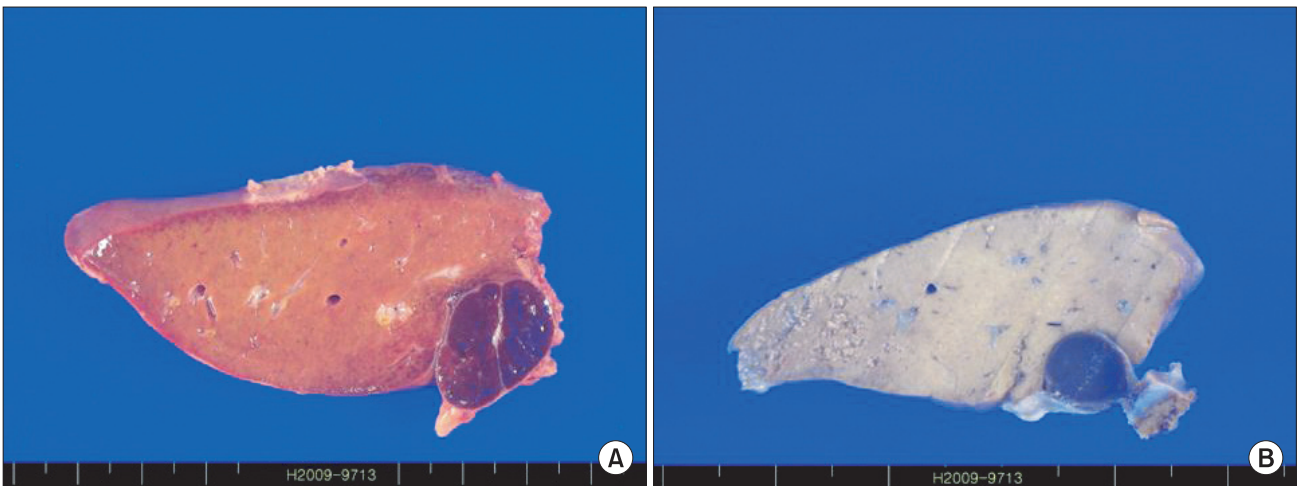


Fig. 4. On the multiple serial sections of the liver, there were two encapsulated red-blue nodules that measured 2.3×1.9 cm (A) and 0.7×0.6 cm (B), respectively. They were located near the liver capsule.

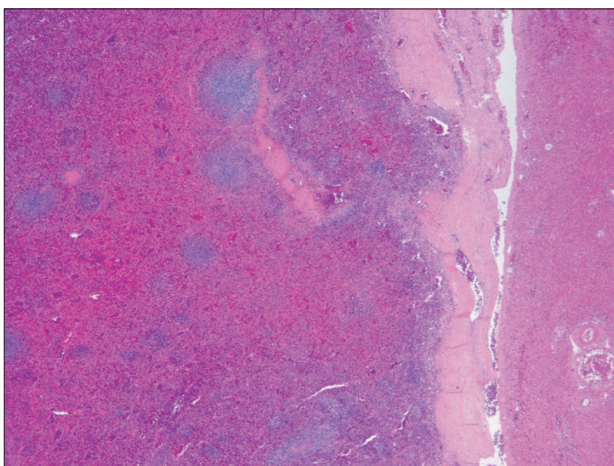


Fig. 5. The pathological examination of this lesion found a full component of red and white pulp of the spleen and this confirmed the diagnosis of splenosis, with no evidence of metastasis (H&E, ×20).

Discussion

Gastric cancer is the most common malignancy in South Korea. Unlike the well-established surgical benefits for liver metastasis from colorectal cancer, liver resection for hepatic metastases from gastric cancer is not a common procedure because of the poor prognosis. However, the advancement of surgical techniques for liver resection and better perioperative management has made the outcome of liver resection safer. Therefore, liver resection for metastasis from gastric cancer is increasingly being performed because complete surgical resection appears to be the only method of curing this disease.(13)

The ultrasonography characteristics of hepatic splenosis is a hypoechoic, homogenous soft tissue mass with a thin rim of a hyperechoic wall, and a CT scan shows a single or multiple soft tissue masses with variable sizes, shapes and enhancements. Yet there is a possibility of not detecting liver metastasis from gastric cancer

on a CT scan. The signal intensities and enhancement patterns of the splenosis on MRI appear to be identical to those of the normal spleen (hypointense on the T1-weighted imaging and hyperintense on the T2-weighted imaging).(14) So, making the differential diagnosis between splenosis and hepatocellular carcinoma (HCC) or other liver tumors by routine USG, CT and MRI is very difficult because splenosis has no typical radiologic findings.(10)

On the other hand, SPIO-enhanced MRI has been reported as a useful diagnostic tool to differentiate hepatic splenosis from malignant hepatic tumor.(5,9) The phagocytic reticuloendothelial cells located in the liver and spleen show a tissue-specific distribution after intravenous SPIO injection and they show the loss of signal intensity on T2-weighted MRI. But malignant tumor shows no signal loss because it does not have reticuloendothelial cells. MRI also has the advantages over nuclear medicine techniques of higher spatial resolution. However, scintigraphic imaging with heat-denatured technetium-99m-labeled red blood cells (RBCs) is the most sensitive and specific imaging modality.(15) Eventually, histologic examination via a localized needle biopsy or excisional biopsy during laparotomy is the gold standard for making the diagnosis. In this patient, even though we did not perform a scintigraphic imaging technique, USG demonstrated a new intrahepatic mass, which was not detected five years ago, and MRI revealed high signal intensity on the T2-weighted image after SPIO injection. Therefore, we concluded the intrahepatic nodule was liver metastasis from gastric cancer and we performed left lateral segmentectomy of the liver.

Intra-operative US is known to be a diagnostic method that is more accurate for determining the number, location and circumference anatomy of intra-hepatic nodules. Intra-operative US was performed in this case, and another intra-hepatic nodule was found besides the first known lesion. The other lesion was located on the inner side of the liver parenchyma, and this finding was suspected to be liver metastasis from gastric cancer. However, if we had performed intra-operative US guided fine needle aspiration before liver resection, we could have correctly diagnosed this man's condition as splenosis and there would be no need to resect the liver parenchyma.

To the best of our knowledge, this is the first report to describe a patient with gastric cancer and intrahepatic splenosis that was misinterpreted as liver metastatic nodule. Hepatic splenosis is not a rare disease if a patient has a history of splenic injury or splenectomy. SPIO enhanced MRI or scintigraphy using heat-denatured technetium-99m-labeled RBCs can be used to differentiate intrahepatic splenosis from other liver tumors. For the final analysis,

histologic confirmation by biopsy should be performed to avoid unnecessary liver resection.

References

1. Shaw AFB, Shafi A. Traumatic autoplasmic transplantation of splenic tissue in man with observations on the late results of splenectomy in six cases. *J Pathol* 1937;45:215-235.
2. Fleming CR, Dickson ER, Harrison EG Jr. Splenosis: autotransplantation of splenic tissue. *Am J Med* 1976;61:414-419.
3. Marchant LK, Levine MS, Furth EE. Splenic implant in the jejunum: radiographic and pathologic findings. *Abdom Imaging* 1995;20:518-520.
4. Bock DB, King BF, Hezmall HP, Oesterling JE. Splenosis presenting as a left renal mass indistinguishable from renal cell carcinoma. *J Urol* 1991;146:152-154.
5. De Vuysere S, Van Steenberghe W, Aerts R, Van Hauwaert H, Van Beckevoort D, Van Hoe L. Intrahepatic splenosis: imaging features. *Abdom Imaging* 2000;25:187-189.
6. Stein S, Duarte PS, Alavi A, Zhuang H, Alavi JB. Multiple intraabdominal soft-tissue masses in a man awaiting liver transplantation: a case study and discussion. *Am J Clin Oncol* 2000;23:506-508.
7. Lee JB, Ryu KW, Song TJ, Suh SO, Kim YC, Koo BH, et al. Hepatic splenosis diagnosed as hepatocellular carcinoma: report of a case. *Surg Today* 2002;32:180-182.
8. D'Angelica M, Fong Y, Blumgart LH. Isolated hepatic splenosis: first reported case. *HPB Surg* 1998;11:39-42.
9. Kondo M, Okazaki H, Takai K, Nishikawa J, Ohta H, Uekusa T, et al. Intrahepatic splenosis in a patient with chronic hepatitis C. *J Gastroenterol* 2004;39:1013-1015.
10. Abu Hilal M, Harb A, Zeidan B, Steadman B, Primrose JN, Pearce NW. Hepatic splenosis mimicking HCC in a patient with hepatitis C liver cirrhosis and mildly raised alpha fetoprotein; the important role of explorative laparoscopy. *World J Surg Oncol* 2009;7:1.
11. Nakajima T, Fujiwara A, Yamaguchi M, Makiyama A, Wakae T, Fujita K, et al. Intrahepatic splenosis with severe iron deposition presenting with atypical magnetic resonance images. *Intern Med* 2008;47:743-746.
12. Foroudi F, Ahern V, Peduto A. Splenosis mimicking metastases from breast carcinoma. *Clin Oncol (R Coll Radiol)* 1999;11:190-192.
13. Shirabe K, Shimada M, Matsumata T, Higashi H, Yakeishi Y,

- Wakiyama S, et al. Analysis of the prognostic factors for liver metastasis of gastric cancer after hepatic resection: a multi-institutional study of the indications for resection. *Hepatology* 2003;50:1560-1563.
14. Lin WC, Lee RC, Chiang JH, Wei CJ, Chu LS, Liu RS, et al. MR features of abdominal splenosis. *AJR Am J Roentgenol* 2003;180:493-496.
15. Hagman TE, Winer-Muram HT, Meyer CA, Jennings SG. Intrathoracic splenosis: superiority of technetium Tc 99m heat-damaged RBC imaging. *Chest* 2001;120:2097-2098.