

## Altered Expression of RANKL/OPG after Alendronate Administration in the Developing Teeth of Postnatal Rats

Min-Ju Kim, Yun-Jeong Jun, Hong-Il Yu, So-Yeong Yang, Won-Man Oh, Sun-Hun Kim, and Min-Seok Kim\*

Dental Science Research Institute, 2nd Stage Brain Korea, School of Dentistry, Chonnam National University

(received January 12, 2011 ; revised February 16, 2011 ; accepted March 4, 2011)

The working mechanism of bisphosphonate on bone cells is unclear despite its powerful inhibitory activity on bone resorption. The differentiation and activation of osteoclasts are essential for bone resorption and are controlled by the stimulatory RANKL and inhibitory OPG molecules. Teeth exhibit a range of movement patterns during their eruption to establish their form and function, which inevitably accompanies peripheral bone resorption. Hence, the mandible, which contains the teeth during their eruption processes, is a good model for revealing the inhibitory mechanism of bisphosphonate upon bone resorption. In the present study, RANKL and OPG expression were examined immunohistochemically in the mandible of rats with developing teeth after alendronate administration (2.5 mg/kg). The pre-eruptive mandibular first molars at postnatal days 3 to 10 showed the developing stages from bell to crown. No morphological changes in tooth formation were observed after alendronate administration. The number of osteoclasts in the alveolar bone around the developing teeth decreased markedly at postnatal days 3, 7 and 10 compared with the control group. RANKL induced strong positive immunohistochemical reactions in the dental follicles and stromal cells around the mandibular first molar. In particular, many osteoclasts with strongly positive reactions to RANKL appeared above the developing mandibular first molars at postnatal days 3 and 10. Immunohistochemical reactions with RANKL after alendronate administration were weaker than the control groups. However, the immunohistochemical reactivity to OPG was stronger after alendronate admini-

stration, at postnatal days 3 and 10. These results suggest that alendronate may decrease bone resorption by regulating the RANKL/OPG pathway in the process of osteoclast formation, resulting in a delay in tooth eruption.

**Key words :** tooth development, bisphosphonate, RANKL, OPG

### Introduction

Bisphosphonates are used as effective therapeutic agents by inhibiting bone resorption, in bone metabolic diseases, such as osteoporosis or Paget's disease, which were characterized by increased bone resorption and loss (Papapoulos, 1996; Fleisch, 1997). The mechanisms by which bisphosphonate inhibit bone resorption has been explained principally by the direct action on osteoclasts, such as a decrease in differentiation to osteoclasts from an osteoclast precursor, inhibition of mature osteoclasts activity and increase in osteoclast apoptosis at high doses (Hughes *et al.*, 1989; Parfitt *et al.*, 1996; Jilka *et al.*, 1998). However, differentiation or activation of osteoclasts are basically regulated by a range of factors secreted from osteoblasts or surrounding stromal cells *in vivo*. Recently, evidence suggesting the possibility of indirect regulation of the osteoclast function indicated that bisphosphonate can inhibit extracellular matrix formation by osteoblasts and regulate the expression of a range of growth factors secreted by the surrounding cells acting on osteoclasts (Sahni *et al.*, 1993; Vitte *et al.*, 1996; Plotkin *et al.*, 1999).

Among these growth factors, osteoclast differentiation factor (ODF), also known as RANKL, is a cell membrane-associated protein that is expressed from bone marrow stromal cells and osteoblasts, and functions as an essential molecule for osteoclastogenesis and activation (Lacey *et al.*, 1998; Yasuda *et al.*, 1998; Jeong *et al.*, 2005). Osteoclastogenesis

\*Corresponding author: Min-Seok Kim, D.D.S., PhD, Associate Professor Department of Oral Anatomy, School of Dentistry, Chonnam National University, Yongbongdong 300, Gwangju 500-757, Korea  
Tel.: +82-62-530-4823; Fax.: +82-62-530-4829  
E-mail : greatone@chonnam.ac.kr

inhibitory factor (OCIF), also known as osteoprotegerin (OPG), is a type of secretory glycoprotein, functioning as a decoy receptor of ODF by conjugating with ODF, thereby blocking the signaling between cells and causing the failure of osteoclastogenesis (Simonet *et al.*, 1997). RANKL and OPG act as potential mediators that promote or inhibit the bone resorption of many osteotropic agents (Suda *et al.*, 1999; Hofbauer *et al.*, 2000; Shin *et al.*, 2005). However, it is unclear if the inhibitory action of bone resorption of bisphosphonate is due to the competitive roles of RANKL/OPG.

Bone resorption is essential for the proper eruption pathway in tooth development. Some reports have suggested that bisphosphonate affects hard tissue formation and tooth eruption during tooth development. Kawata *et al.* (2004) administered bisphosphonate to experimental animals, resulting in a decrease in the number or size of osteoclasts, which eventually prevents or delays tooth eruption. A recent *in vitro* study reported that RANKL and OPG was detected in the dental follicle, which is an essential structure for tooth eruption. There is also experimental evidence suggesting that inhibition of RANKL and OPG gene expression can affect the time and aspect of tooth eruption (Wise *et al.*, 2002a, 2002b). Therefore, delayed tooth eruption by bisphosphonate may be related to the RANKL/OPG interaction. On the other hand, most results were obtained from *in vitro* studies using cell cultures, and there is little evidence established from morphologic studies using *in vivo* animal models.

This study examined the mechanism behind the effect of bisphosphonate on hard tissue formation and eruption in tooth development by observing RANKL and OPG expression with time after the administration of alendronate in a postnatal rat mandible including the developing molar.

## Material and method

All procedures were performed in accordance with the ethical standards recommended by the Chonnam National University Institutional Animal Care and Use Committee. Subcutaneous injections of 2.5 mg/kg/day alendronate (MK-217<sup>®</sup>, Merck, USA) diluted in distilled water were performed on the back of neck of postnatal 1 day Sprague-Dawley rats ( $n = 24$ ) for 1, 3, 7 and 10 days. The control groups were injected daily with a sterile saline solution for 10 days in the same area.

After drug administration for 3, 7 and 10 days, the mandible including developing tooth was dissected under anesthesia with a pentobarbital sodium (50 mg/kg) and the separated jaw was fixed in a 4% paraformaldehyde (4°C, pH 7.4) solution for 24 hours, and decalcified in a 10% EDTA (4°C, pH 7.4) solution. The specimens were washed in PBS, dehydrated in ethanol, and embedded in paraffin. 5  $\mu$ m serial sections were prepared from paraffin embedded tissues and stained with H-E. The morphological characteristics of the osteoclasts in the

developing tooth, dental follicle, and alveolar bone surrounding the erupting tooth were observed by optical microscopy.

Immunohistochemical staining was performed using a Vectastain Elite ABC Kit (Vector Laboratories, Burlingame, CA, USA) according to the manufacturer's protocol. Briefly, after blocking endogenous peroxidase using 3% H<sub>2</sub>O<sub>2</sub> for 10 min, the sections were reacted with purified monoclonal mouse anti-RANKL and anti-OPG (Santa Cruz Lab, Santa Cruz, CA, USA) as the primary antibody overnight at 4°C, and subsequently in biotinylated anti-mouse IgG as the secondary antibody for 10 min. Normal serum was substituted with the primary antibodies for the negative control. Finally, the sections were incubated in avidin and biotinylated horseradish peroxidase reagent for 10 min. After colorization by AEC for 5 min, the reactants were counterstained with Meyer's hematoxyline, dehydrated, sealed with Canada balsam, and observed by optical microscopy.

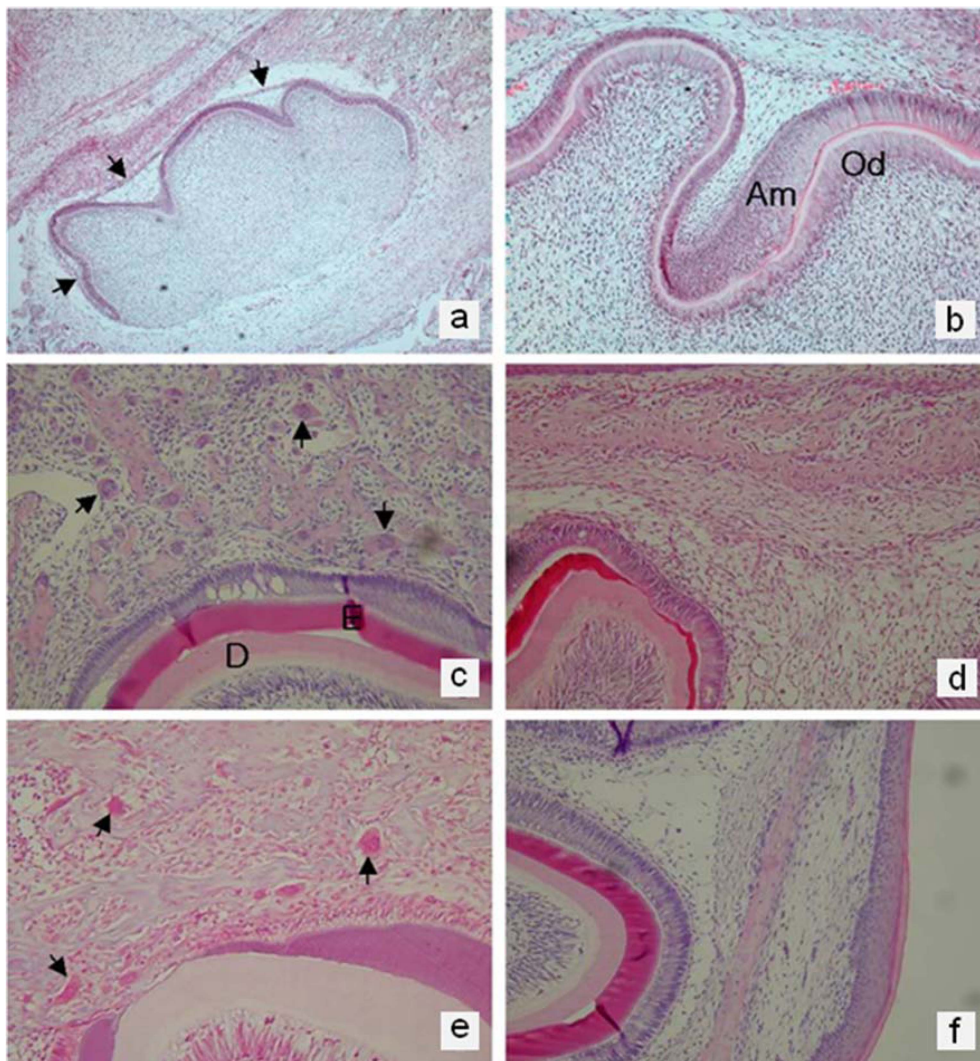
## Results

### General histological findings

The pre-eruptive mandibular 1<sup>st</sup> molar tooth germ of a postnatal rat took various forms from the bell stage to crown stage of tooth development. The tooth germ of the mandibular 1<sup>st</sup> molar at the postnatal 1 day rat showed the configuration of the bell stage and dental organ, which has four distinctly isolated layers including the outer dental epithelium, inner dental epithelium, stellate reticulum and stratum intermedium, was distinguished from the dental papilla by the acellular zone. The developing tooth was separated from the adjacent alveolar bone by the surrounding dental follicle (Fig. 1a). No morphological changes in tooth formation were observed after alendronate administration, and crown stage started, forming dentin and enamel in both control and experimental groups after postnatal 3 day (Fig. 1b). Several osteoclasts for bone resorption necessary for tooth migration appeared in the alveolar bone around the developing tooth at postnatal day 3. The emergence of osteoclasts appeared to decrease at postnatal day 7, but increased at postnatal day 10. The number of osteoclasts was decreased markedly compared to that of the control group at postnatal days 3, 7 and 10 (Fig. 1c-f).

### Immunohistochemical findings

Strong immunohistochemical positive reactions for RANKL were detected in the dental follicular cells and stromal cells surrounding the mandibular 1<sup>st</sup> molar. In particular, strong positive reactions to RANKL with the appearance of many osteoclasts in the alveolar bone in the upper and lower part of postnatal 3 and 10 day 1<sup>st</sup> mandibular molars forming a root were observed in control groups. The reaction was relatively weak in the postnatal 7 day tooth germ of the control group (Fig. 2a, c). In the experimental groups, immunohistochemical reactions with RANKL in terms of the degree and area of



**Fig. 1.** General histological findings of mandibular 1<sup>st</sup> molar tooth germ by H-E stain. (a) The tooth germ of the mandibular 1<sup>st</sup> molar in postnatal day 1 rats shows the configurations of a bell stage for tooth development. The tooth germ is surrounded by the well developed dental follicle (arrows) and isolated from the alveolar bone. control groups,  $\times 40$ , (b) The tooth germ of the mandibular 1<sup>st</sup> molar in postnatal day 3 rats shows the configurations of crown stage for tooth development. odontoblasts (Od), ameloblast (Am), alendronate group,  $\times 200$ , (c) Several osteoclasts (arrows) appear in the alveolar bone above the tooth germ of the mandibular 1<sup>st</sup> molar in postnatal day 3 rats. enamel(E), dentin(D), control group,  $\times 400$ , (d) Only a few osteoclasts can be observed near the tooth germ of the mandibular 1<sup>st</sup> molar in postnatal day 7 rats. control group,  $\times 200$ , (e) The number of osteoclasts (arrows) increased at postnatal day 10. control group,  $\times 400$ , (f) Osteoclasts are rarely observed near the tooth germ of the mandibular 1<sup>st</sup> molar in postnatal day 3 rats. alendronate group,  $\times 400$

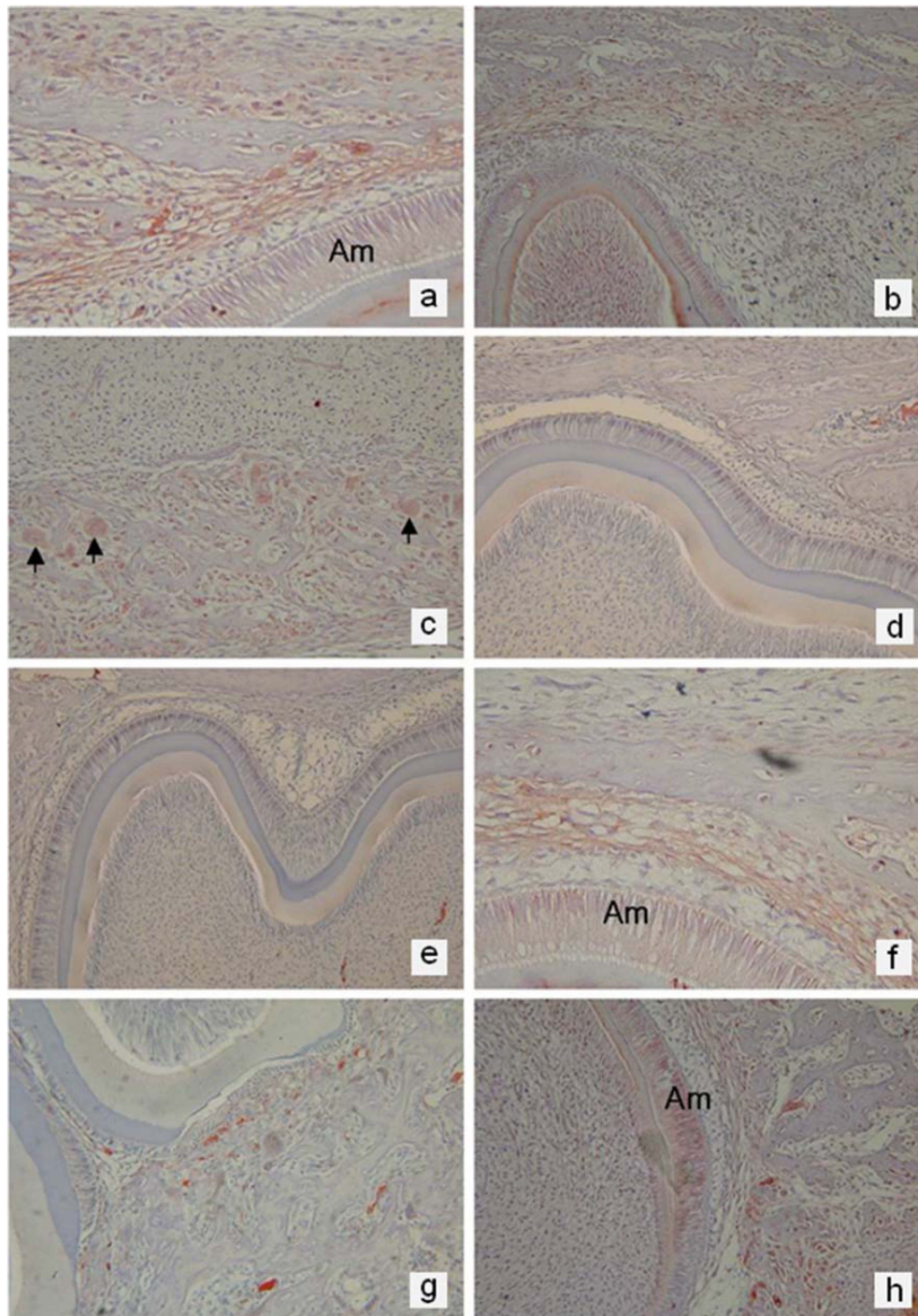
overall reactivity were markedly lower than the control groups (Fig. 2b, d).

Immunohistochemical reactions for OPG were similar to the distribution patterns of RANKL showing positive reactivity in the dental follicular cells surrounding the tooth germ and adjacent stromal cells. The immunoreactivity depending on time was lower in the cells surrounding the tooth germ at the postnatal day 3 and 10 when several osteoclasts appeared (Fig. 2e, g). On the other hand, the experimental groups showed strong reactivity compared to the control groups at postnatal days 3 and 10 (Fig. 2f, h).

## Discussion

Osteoclasts, derived from the hematopoietic precursors of monocyte/macrophage lineage, are bone resorbing cells that play a key role in bone remodeling with osteoblasts in physiological and pathological conditions (Roodman, 1996; Suda *et al.*, 1999). Inhibition of osteoclast activation is a major goal in the treatment of osteolytic diseases because increased bone resorption is the principal incident in the progression of disease. Bisphosphonates have a P-C-P motif structure, replacing the central oxygen atom of inorganic pyrophosphate in the body with a carbon atom, and effectively inhibiting bone resorption by osteoclasts (Russel *et al.*, 1970). This





**Fig. 2.** Immunohistochemical findings of mandibular 1<sup>st</sup> molar tooth germ, (a) Immunostaining with antiserum to RANKL in the developing mandibular 1<sup>st</sup> molar tooth germ at postnatal day 3. Strong immunoreactivity was detected in the dental follicular cells and surrounding stromal cells including osteoclasts. ameloblast (Am) control group,  $\times 400$ , (b) Dental follicles adjacent to the developing mandibular 1<sup>st</sup> molar tooth germ postnatal day 3 show weak immunoreactivity for RANKL antiserum. alendronate group,  $\times 400$ , (c) Immunostaining with antiserum to RANKL in the postnatal 10 day developing mandibular 1<sup>st</sup> molar tooth germ at postnatal day 10. Strong immunoreactivity was also observed in the lower part of alveolar bone with the developing tooth germ and osteoclasts (arrows). control group,  $\times 400$ , (d) Immunopositivity for RANKL antiserum is rarely observed near the tooth germ of the mandibular 1<sup>st</sup> molar at postnatal day 10. alendronate group,  $\times 400$ , (e) Immunopositivity for OPG is very weak compared to that of RANKL at postnatal day 3. control group,  $\times 200$ , (f) Strong immunoreactivity with the antiserum to OPG is observed in the dental follicles surrounding the postnatal day 3 tooth germ compared to those in Fig.1e. ameloblast (Am), alendronate group,  $\times 400$ , (g) OPG antiserum is stained very weakly except for some immunopositivity near the postnatal day 10 tooth germ. control group,  $\times 400$ , (h) Immunoreactivity for OPG in postnatal day 10 tooth germ is stronger than the control groups. ameloblast (Am) alendronate group,  $\times 400$

structure has high affinity for hydroxyapatite and bone, and regulates the affinity to bone or inhibitory bone resorption, based on the P-C-P motif, by replacing several chemical materials. The alendronate used in this study, nitrogen-containing bisphosphonate, is used as an effective therapeutic agent for Paget disease, tumor-associated bone disease, and osteoporosis (Saag *et al.*, 1999; Orwoll *et al.*, 2000). It also selectively inhibits the function of osteoclasts, inducing apoptosis, and decreasing bone loss (Rogers *et al.*, 2000).

The inhibition of bone resorption by bisphosphonates has been attributed mainly to their direct inhibitory effect on osteoclasts, but recent studies have focused on their indirect actions, such as the relation to osteoblasts or surrounding stromal cells (Klein *et al.*, 1998; Reinholz *et al.*, 2000). Dental follicles, loose connective tissue that entirely surrounds the developing tooth germ, are believed to perform the important role in regulating tooth germ migration including tooth eruptive movement in the jaw. These cells can synthesize and secrete a range of molecules concerning the resorption of the surrounding alveolar bone (Wise and Lin, 1995; Wise *et al.*, 1999). In this study, RANKL and OPG, the most important factors regulating the differentiation and activation of osteoclasts, were spatiotemporally distributed in the dental follicle and stromal cells, which are similar to the osteoblasts of the surrounding alveolar bone. In addition, dental follicular cells appear to play important roles in regulating the differentiation and activation of osteoclasts for tooth eruption.

In this study, the number of osteoclasts found in the alveolar crypt including the developing mandibular 1<sup>st</sup> molar was markedly different over time, and appeared to be related to RANKL and OPG expression regulating the differentiation and activation of osteoclasts. The RANKL-immunopositive reaction, which is related to the stimulation of osteoclastogenesis and osteoclastic activity, was observed in the dental follicle and surrounding stromal cells at postnatal day 3 and 10 when many osteoclasts emerged, and the postnatal day 7 specimens showed fewer RANKL-positive cells. On the other hand, in the case of OPG expression, which is related to the inhibition of differentiation and the activation of osteoclasts, strong staining was observed at postnatal 7 day, and a relatively weak reaction was noted at postnatal days 3 and 10. This suggests that the differentiation and activation of osteoclasts, which results in the resorption of bone around the developing tooth germ, can be regulated by the relative RANKL : OPG ratio. Several factors related to osteoclastogenesis, such as colony stimulating factor-1, monocyte chemotactic factor-1 and vascular endothelial growth factor, which were expressed from the dental follicle, were also similar to those of RANKL (Wise, Yao, 2003).

These results showed that RANKL/OPG expression observed in the developing tooth germ and appearance of osteoclasts were changed markedly by alendronate administration. After alendronate administration, the immunohistochemical reactivity for RANKL decreased particularly in the postnatal 3 and 10 day control groups, which showed

well-defined positive staining with the appearance of many osteoclasts. In contrast, alendronate increased the immunoreactivity for OPG at postnatal days 3 and 10. Therefore, alendronate inhibits the secretion of RANKL and increases the synthesis of OPG by acting on the dental follicle and stromal cells of the alveolar bone, consequently inhibiting the differentiation and activation of osteoclasts required for eruptive tooth movement. Recently, a decrease in RANKL mRNA expression was observed in UMR-106 osteosarcoma cells treated with bisphosphonate (Mackie *et al.*, 2001). However, both RANKL and OPG gene expression were constant in rodent osteoblasts and bone marrow cells treated with bisphosphonate, (Kim *et al.*, 2002). These results appear contradictory when explaining the action mechanism of bisphosphonate. This discrepancy might be due to the differences in cell sources e.g. which the species or whether the cells originated from cancer or not. In addition, bisphosphonates would change only the protein levels of RANKL and OPG through post-translational modification without altering their gene expression levels.

This study showed that alendronate affects the expression of RANKL and OPG by acting on the dental follicular cells and stromal cells of the surrounding alveolar bone, and can regulate the differentiation and activation of osteoclasts for the resorption of the surrounding alveolar bone. There is still the possibility that effects of bisphosphonate on osteoclastogenesis arose from other factors besides RANKL and OPG. Therefore, further studies using molecular biological methods, such as western blotting, will be needed to analyze the quantitative differences in RANKL and OPG expression as a function of time after drug administration.

---

## Acknowledgements

This study was supported financially by Chonnam National University, 2007.

---

## Reference

- Fleisch H. Bisphosphonates in bone disease: From the laboratory to the patient 3rd Ed. 1997.
- Hughes DE, MacDonald BR, Russell RG, Gowen M. Inhibition of osteoclast-like cell formation by bisphosphonates in long-term cultures of human bone marrow. *J Clin Invest.* 1989; 83(6):1930-5.
- Hofbauer LC, Khosla S, Dunstan CR, Lacey DL, Boyle WJ, Riggs BL. The roles of osteoprotegerin and osteoprotegerin ligand in the paracrine regulation of bone resorption. *J Bone Miner Res.* 2000;15(1):2-12.
- Jeong HJ, Yushun T, Kim BH, Nam MY, Lee HA, Yoo YJ, Seo JT, Shin DM, Ohk SH, Lee SI. Hypertonicity Down-regulates the  $1\alpha,25(\text{OH})_2$  Vitamin D3-induced Osteoclastogenesis Via the Modulation of RANKL Expression in Osteoblast. *Int J Oral Biol.* 2005;30(1):23-30.

- Jilka RL, Takahashi K, Munshi M, Williams DC, Roberson PK, Manolagas SC. Loss of estrogen upregulates osteoblastogenesis in the murine bone marrow. Evidence for autonomy from factors released during bone resorption. *J Clin Invest.* 1998;101(9):1942-50.
- Kawata T, Tenjou K, Tokimasa C, Fujita T, Kaku M, Matsuki A, Kohno S, Tsutsui K, Ohtani J, Motokawa M, Shigekawa M, Tohma Y, Tanne K. Effect of alendronate on osteoclast differentiation and bone volume in transplanted bone. *Exp Anim.* 2004;53(1):47-51.
- Kim YH, Kim GS, Jeong-Hwa B. Inhibitory action of bisphosphonates on bone resorption does not involve the regulation of RANKL and OPG expression. *Exp Mol Med.* 2002; 34(2):145-51.
- Klein BY, Ben-Bassat H, Breuer E, Solomon V, Golomb G. Structurally different bisphosphonates exert opposing effects on alkaline phosphatase and mineralization in marrow osteoprogenitors. *J Cell Biochem.* 1998;68(2):186-94.
- Lacey DL, Timms E, Tan HL, Kelley MJ, Dunstan CR, Burgess T, Elliott R, Colombero A, Elliott G, Scully S, Hsu H, Sullivan J, Hawkins N, Davy E, Capparelli C, Eli A, Qian YX, Kaufman S, Sarosi I, Shalhoub V, Senaldi G, Guo J, Delaney J, Boyle WJ. Osteoprotegerin ligand is a cytokine that regulates osteoclast differentiation and activation. *Cell.* 1998; 93(2):165-76.
- Mackie PS, Fisher JL, Zhou H, Choong PF. Bisphosphonates regulate cell growth and gene expression in the UMR 106-01 clonal rat osteosarcoma cell line. *Br J Cancer.* 2001; 84(7):951-8.
- Orwoll E, Ettinger M, Weiss S, Miller P, Kendler D, Graham J, Adami S, Weber K, Lorenc R, Pietschmann P, Vandormael K, Lombardi A. Alendronate for the treatment of osteoporosis in men. *N Engl J Med.* 2000;343(9):604-10.
- Papoulous S. Bisphosphonates: Pharmacology and use in the treatment of osteoporosis. In *Osteoporosis.* pp. 1209-34. 1996.
- Parfitt AM, Mundy GR, Roodman GD, Hughes DE, Boyce BF. A new model for the regulation of bone resorption, with particular reference to the effects of bisphosphonates. *J Bone Miner Res.* 1996;11(2):150-9.
- Plotkin LI, Weinstein RS, Parfitt AM, Roberson PK, Manolagas SC, Bellido T. Prevention of osteocyte and osteoblast apoptosis by bisphosphonates and calcitonin. *J Clin Invest.* 1999;104(10):1363-74.
- Reinholz GG, Getz B, Pederson L, Sanders ES, Subramaniam M, Ingle. Bisphosphonates directly regulate cell proliferation, differentiation, and gene expression in human osteoblasts. *Cancer Res.* 2000;60(21):6001-7.
- Renshaw-Gegg L, Hughes TM, Hill D, Pattison W, Campbell P, Boyle WJ et al. Osteoprotegerin: a novel secreted protein involved in the regulation of bone density. *Cell.* 1997;89(2): 309-19.
- Rogers MJ, Gordon S, Benford HL, Coxon FP, Luckman SP, Monkonen J, Frith JC. Cellular and molecular mechanisms of action of bisphosphonates. *Cancer.* 2000;88(12 Suppl): 2961-78.
- Roodman GD. Advances in bone biology: the osteoclast. *End Rev.* 1996;17:308-22.
- Saag KG, Emkey R, Schnitzer TJ, Brown JP, Hawkins F, Goemaere S, Thamsborg G, Liberman UA, Delmas PD, Malice MP, Czachur M, Daifotis AG. Alendronate for the prevention and treatment of glucocorticoid-induced osteoporosis. Glucocorticoid-Induced Osteoporosis Intervention Study Group. *N Engl J Med.* 1998;339(5):292-9.
- Sahni M, Guenther HL, Fleisch H, Collin P, Martin TJ. Bisphosphonates act on rat bone resorption through the mediation of osteoblasts. *J Clin Invest.* 1993;91(5):2004-11.
- Simonet WS, Lacey DL, Dunstan CR, Kelley M, Chang MS, Luthy R, Nguyen HQ, Wooden S, Bennett L, Boone T, Shimamoto G, DeRose M, Elliott R, Colombero A, Tan HL, Trail G, Sullivan J, Davy E, Bucay N, Renshaw-Gegg L, Hughes TM, Hill D, Pattison W, Campbell P, Boyle WJ et al. Osteoprotegerin: a novel secreted protein involved in the regulation of bone density. *Cell.* 1997;89(2):309-19.
- Shin JY, Baek DH, Han SB. The Effects of Sex Hormones on the Expression of ODF/OPG in Human Gingival Fibroblast and Periodontal Ligament Cell at Serum Concentration During Pregnancy. *Int J Oral Biol.* 2005;30(3):105-110.
- Suda T, Nakamura I, Jimi E, Takahashi N. Regulation of osteoclast function. *J Bone Miner Res.* 1997; 2(6):869-79.
- Suda T, Takahashi N, Udagawa N, Jimi E, Gillespie MT, Martin TJ. Modulation of osteoclast differentiation and function by the new members of the tumor necrosis factor receptor and ligand families. *Endocr Rev.* 1999;20(3):345-57.
- Vitte C, Fleisch H, Guenther HL. Bisphosphonates induce osteoblasts to secrete an inhibitor of osteoclast-mediated resorption. *Endocrinology.* 1996;137(6):2324-33.
- Wise GE, Lin F. The molecular biology of initiation of tooth eruption. *J Dent Res.* 1995; 74(1):303-6.
- Wise GE, Huang H, Que BG. Gene expression of potential tooth eruption molecules in the dental follicle of the mouse. *Eur J Oral Sci.* 1999;107(6):482-6.
- Wise GE, Yao S, Zhang Q, Ren Y. Inhibition of osteoclastogenesis by the secretion of osteoprotegerin in vitro by rat dental follicle cells and its implications for tooth eruption. *Arch Oral Biol.* 2002a;47(3):247-54.
- Wise GE, Frazier-Bowers S, D'Souza RN. Cellular, molecular, and genetic determinants of tooth eruption. *Crit Rev Oral Biol Med.* 2002b;13(4):323-34.
- Wise GE, Yao S. Expression of vascular endothelial growth factor in the dental follicle. *Crit Rev Eukaryot Gene Expr.* 2003;13(2-4):173-80.
- Yasuda H, Shima N, Nakagawa N, Yamaguchi K, Kinosaki M, Mochizuki S, Tomoyasu A, Yano K, Goto M, Murakami A, Tsuda E, Morinaga T. Osteoclast differentiation factor is a ligand for osteoprotegerin/osteoclastogenesis-inhibitory factor and is identical to TRANCE/RANKL. *Proc Natl Acad Sci USA.* 1998;95(7):3597-602.