

Case series of maxillary sinus augmentation with biphasic calcium phosphate: a clinical and radiographic study

Jae-Kook Cha, Jung-Chul Park, Ui-Won Jung, Chang-Sung Kim, Kyoo-Sung Cho, Seong-Ho Choi*

Department of Periodontology, Research Institute for Periodontal Regeneration, Yonsei University College of Dentistry, Seoul, Korea

Purpose: The aim of this study was to evaluate 3.5 years-cumulative survival rate of implants placed on augmented sinus using Osteon, a bone graft material, and to assess the height of the grafted material through radiographic evaluation.

Methods: Twenty patients were treated with maxillary sinus augmentation and 45 implant fixtures were installed simultaneously or after 6 months healing period. The height of the augmented sinus and the loss of marginal bone were measured by panoramic and intraoral radiographs immediately after augmentation and up to 42 months (mean, 19.4 months) subsequently. Changes in the height of the sinus graft material were calculated radiographically.

Results: The cumulative survival rate was 95.56% in all 45 implants. Additionally, normal healing process without any complication was observed in all patients. The original sinus height was mean 4.3 mm and the augmented sinus height was mean 13.4 mm after the surgery. The mean marginal bone loss till 42 months was 0.52 ± 0.56 mm. The reduced height of Osteon was 0.83 ± 0.38 mm and it did not show significant correlation with the follow up periods ($P=0.102$). There were no statistically significant differences in reduced height of Osteon according to the simultaneous/delayed implantation ($P=0.299$) and particle size of Osteon ($P=0.644$).

Conclusions: It can be suggested that Osteon may have predictable result when it was used as a grafting material for sinus floor augmentation.

Keywords: Dental implants, Maxillary sinus, Survival rate.

INTRODUCTION

One of the necessary requirements for a dental implant is the presence of at least a moderate amount of bone in order to place an implant with the appropriate length and diameter. The loss of the alveolar ridge due to trauma, periodontal disease, or the failure of endodontic treatment, however, may make it difficult to place the implant in the best location for proper esthetics and function. The maxillary posterior area, is known to be especially difficult for implant treatment and to have a low success rate because of the poor bone quality.

Moreover, the posterior edentulous maxilla has represented a challenge for clinicians owing to the resorption of the alveolar ridge and pneumatization of the maxillary sinus.

This has led to the development of a bone augmentation technique, the onlay bone graft and sinus augmentation. Sinus augmentation via lateral window osteotomy has been routinely performed in the last few years and has been regarded as a predictable procedure [1-4]. However, the choice of the bone graft material is still under discussion.

The use of autogenous bone in sinus augmentation has been regarded as a superior method because of the repro-

Received: Dec. 30, 2010; **Accepted:** Feb. 25, 2011

***Correspondence:** Seong-Ho Choi

Department of Periodontology, Research Institute for Periodontal Regeneration, Yonsei University College of Dentistry, 250 Seongsan-no, Seodaemun-gu, Seoul 120-752, Korea

E-mail: shchoi726@yuhs.ac, Tel: +82-2-2228-3189, Fax: +82-2-392-0398

ducible healing mechanism of osteogenesis, osteoinduction, and osteoconduction. Nevertheless, there are some limitations, e.g., the need for additional surgical sites and the rapid resorption rate when the autogenous bone is used as a sinus grafting material [5-7]. Therefore, the use of synthetic bone has been recently appraised for its biocompatibility and volume maintenance capacity [8,9].

Various synthetic materials have been developed for use in maxillary sinus augmentation to allow bone ingrowth and to prevent sinus pneumatization after grafting. Among them, the mixture of hydroxiapatite (HA) and beta-tricalcium phosphate (β -TCP) has been studied extensively as a new alloplastic material [10]. HA can play an osteoconductive role due to its appropriate space maintenance capacity, but it has a low-grade osteogenetic property. On the other hand, β -TCP, with its good biocompatibility, has been used as a substitute for autogenous bone [11,12]. In light of this, mixing adequate ratios of HA and β -TCP allows for controlling the resorption rate without distorting its the bone's osteoconductive property [13-15].

Osteon (Dentium, Seoul, Korea) is synthetic material containing 70% HA and 30% β -TCP. It has a porous structure, which can accelerate new bone ingrowth and maturation (Fig. 1). Two different particle sizes of Osteon have been used (0.5-1.0 mm and 1.0-2.0 mm). In several previous studies, Osteon was regarded as a suitable sinus augmentation material based on histologic analysis [16]. Moreover, we have previously reported on the volume maintenance of grafted Osteon and implant success rate in a pilot study [17]. In that study, the grafted material was well maintained in the sinus and decreased slightly over 1 year (0.05 mm/month). It is suggested that Osteon may produce predictable results when it




Figure 1. Scanning electron microscope image of Osteon.

is used as a grafting material for sinus floor augmentation.

The aim of the present study was to evaluate the cumulative survival rate (CSR) of implants placed in sinuses augmented with Osteon, and to assess the resorption rate of the grafted material radiographically with increased sample size and statistical power as an extension to our previous studies.

CASE DESCRIPTION

This study was approved by the Institutional Review Board of Yonsei University College of Dentistry (Approval No. 5-2008-3). A total 45 implants were placed in 20 maxillary sinuses of 20 patients (8 males, 12 females, mean age 57.2 ± 11.3 years) with the condition of having under 5 mm of residual alveolar bone height, using a sinus augmentation technique via lateral window osteotomy [18]. All implants were maintained with at least 6 months of prosthetic loading time. Patients' exclusion criteria were: 1) heavy smoking (more than 20 cigarettes per day), 2) a debilitating systemic disease such as uncontrolled diabetes mellitus 3) signs and symptoms of maxillary sinus disease, or 4) active periodontal disease involving the residual dentition.

Five implants were from Branemark System-MKIII TiUnite (NobelBiocare AB, Gotenborg, Sweden); 12 implants were from Xive (Dentsply Friadent, Mannheim, Germany), 5 implants were from Astra (Astra Tech AB, Mölndal, Sweden), 6 implants were from Osstem GSII (Osstem Implant Co., Busan, Korea), and 17 implants were from Implantium (Dentium). Five implants had a machined surface; 29 implants had a sandblasted, large-grid and acid etched surface; and 11 implants had a resorbable blast media surface. All implants were placed in either one- or two-stage surgery. The timing of implantation was determined, depending on the primary stabilization of implants. In the two-stage approach, implantation was performed 6 months after the augmentation of the maxillary sinus.

A mixture of 2 different types of Osteon in a 1:1 ratio was used in 10 patients, while only the larger particle size of Osteon was used in the other 10 patients. The quality of bone was evaluated according to Lekholm and Zarb's classification during the surgical procedure [19]. Most of the examined subsinus ridges were composed of bone with poor quality (type III and IV). General information on each case is presented in Table 1.

Surgical technique

A modified Caldwell-Luc sinus augmentation was performed under local anesthesia (2% lidocaine hydrochloride-epinephrine 1:100,000; Huons Co., Seoul, Korea) [20,21]. In brief, the surgical area was prepared via elevation of a full

Table 1. Case summary.

Case	Age/ Sex	Area	System	Diameter	Length	1 or 2 stage	Original bone height (mm)	Dose of Osteon (mL)	Type of Osteon	Bone quality	F/U (mo)
1	54/F	15	Branemark	4	10.5	simultaneous	4.3	3	S/L	IV	30
		16	Branemark	5	11.5	simultaneous	2.5				
2	75/F	15	Branemark	4	11.5	simultaneous	5.0	2.5	S/L	III	42
		16	Branemark	4	11.5	Delayed	2.9				
		17	Branemark	4	11.5	Delayed	3.5				
3	71/M	26	Implantium	3.8	10	Delayed	5.7	2	S/L	III	16
		27	Implantium	3.8	10	Delayed	2.5				
4	64/F	25	Xive	3.4	9.5	Simultaneous	5.5	1.5	S	III	18
		27	Xive	3.8	9.5	Simultaneous	3.2				
5	47/F	15	Xive	3.8	9.5	Simultaneous	5.6	1.5	S	III	29
		16	Xive	4.5	9.5	Simultaneous	5.5				
		17	Xive	4.5	9.5	Simultaneous	3.3				
6	54/M	16	Implantium	4.3	8	Simultaneous	5.0	2.5	S/L	III	19
		17	Implantium	4.3	8	Simultaneous	3.5				
7	59/M	26	Implantium	4.8	12	Simultaneous	4.8			III	17
		27	Implantium	4.8	10	Simultaneous	4.9				
8	47/F	25	Astra	4	9	Simultaneous	5.8	2	S/L	III	18
		26	Astra	4	9	Simultaneous	4.3				
		27	Astra	4	9	Simultaneous	5.4				
9	70/M	25	Osstem GSII	4	11.5	Simultaneous	5.6	1.5	S/L	III	21
		26	Osstem GSII	4	8.5	Simultaneous	4.0				
		27	Osstem GSII	4	8.5	Simultaneous	4.7				
10	77/F	15	Xive	3.4	9.5	Simultaneous	4.5	3	S	III	24
		16	Xive	3.4	9.5	Simultaneous	3.5				
11	52/F	26	Xive	3.8	9.5	Delayed	3.8	1.5	S	III	18
12	52/F	26	Implantium	4.8	10	Delayed	3.2	1.5	S/L	III	15
		27	Implantium	4.3	10	Delayed	3.4				
13	55/M	15	Osstem GSII	4	10	Simultaneous	4.8	1.5	S	III	20
		16	Osstem GSII	4	10	Simultaneous	3.7				
		17	Osstem GSII	4.5	10	Simultaneous	3.6				
14	41/M	16	Xive	3.8	9.5	Simultaneous	3.8	2	S	III	24
		17	Xive	3.8	9.5	Simultaneous	5.1				
15	40/M	16	Astra	4	13	Delayed	4.7	2.5	S/L	III	17
		17	Astra	4	13	Delayed	5.7				
16	45/F	16	Implantium	4.3	10	Delayed	2.5	2.5	S	II	12
		17	Implantium	4.3	10	Delayed	3.7				
17	58/M	25	Implantium	4.3	8	Simultaneous	4.3	1.5	S	IV	12
		26	Implantium	4.3	8	Simultaneous	4.1				
18	74/F	25	Implantium	3.8	8	Simultaneous	5.4	1.5	S	III	12
		26	Implantium	4.3	8	Simultaneous	3.2				
		27	Implantium	3.8	8	Simultaneous	5.6				
19	53/F	16	Xive	4.5	9.5	Simultaneous	3.7	4	S	III	12
		17	Xive	4.5	9.5	Simultaneous	3.6				
20	56/F	25	Implantium	4.3	10	Simultaneous	4.4	2.5	S	II	12
		26	Implantium	4.3	10	Simultaneous	3.8				

S: small particle, L: large particle, F/U: follow up.

thickness muco-periosteal flap. Osteotomy was performed at the lateral surface of the sinus wall using a diamond round bur and piezoelectric device (Piezosurgery, Mectron Spa, Carasco Genova, Italy) and the sinus membrane was carefully lifted. The sinus cavity was then packed with Osteon, and the lateral window was covered by an absorbable sponge (Collatape, Zimmer Dental, Calsbad, CA, USA). The muco-periosteal flap was repositioned and sutured with absorbable suture material (Monosyn 4.0 Glyconate Monofilament, B. Braun Melsungen AG, Melsungen, Germany; Vicryl 5.0 Polylactim, Johnson & Johnson, New Brunswick, NJ, USA). The prosthodontic procedure was completed after a mean healing period of 6-12 months.

Implant survival rate

The 42 months cumulative survival rate for implants was evaluated using life table analysis [22]. The success criteria for implants presented by Buser et al. [23] was used.

Radiographic analysis

The radiographic analysis was performed by panoramic radiographs and intraoral radiographs using software (Starpacs, Infinit Co., Seoul, Korea). All the values were calibrated precisely based on the length of the implant fixture, and these were double checked by a single investigator. At least 2 consecutive panoramic radiographs were taken--one immediately after the sinus augmentation, the other 1 year after the surgery. Additional radiographs were obtained every 6 to 12 months through the follow-up period. The linear measurements taken from radiographs were described below (Fig. 2).

The original alveolar bone heights prior to the surgery [24], from the alveolar crest to the base of the sinus were measured

(Table 1). The augmented sinus heights (ASH) were measured from the 1st bone to implant contact points to the base of the maxillary sinus, which was elevated with Osteon at the mesial and distal aspects of the implants. The volume of marginal bone loss (MBL) was obtained compared with the intraoral radiographs immediately taken after the surgery and 1 year postoperatively. The reduced height of Osteon (RHO) was calculated based on the changes in the ASH and MBL.

Statistical analysis

The individual mean values were calculated. Differences in RHO according to the timing of implantation and the type of Osteon were analyzed using a independent *t*-test. A one way analysis of variance was used to evaluate the difference in RHO according to the implant sites. A post-hoc Scheffe test was used to evaluate the differences between groups. A *P* value of <0.05 was considered significant. Correlation between the RHO and follow-up period were determined by Spearman's test. SPSS ver. 12.0.0 (SPSS Inc., Chicago, IL, USA) was used for all of the statistical analyses.

Implant survival rate

No complications, including wound dehiscence and sinus membrane perforation, were observed in any of the patients. Two of the 45 implants were removed between implantation and the follow up period (case 2, I_{16,17}). All loss of implants occurred prior to prosthetic loading. Both cases were successfully restored by wider diameter implants. The 0 to 6 month CSR was 95.56%, and this value continues to 42 months (Table 2).

Radiographic results

The mean follow up period for implants after the sinus augmentation was 19.4 months (range, 12 to 42 months). The original sinus height was a mean of 4.3 mm (range, 2.5 to 5.8 mm) and the augmented sinus height was a mean of 13.4 mm (range, 9.81 to 18.1 mm) after the surgery. The mean crown/Implant ratio was 1.19 ± 0.24 mm which was relatively higher than the natural molar. The marginal bone loss up to 12

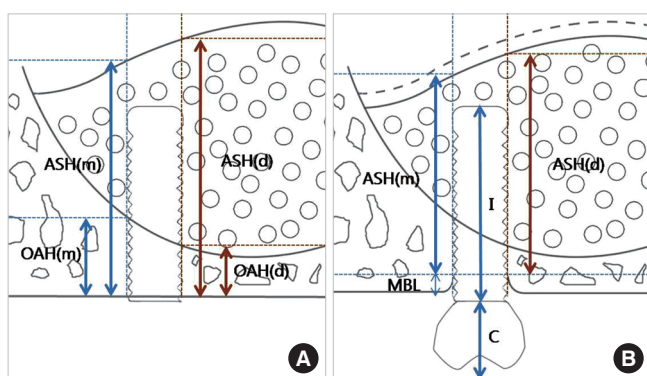


Figure 2. Schematic drawing illustrating the linear measurements taken from radiographs. (A) Immediately after the sinus augmentation. (B) 1-year after the sinus augmentation. ASH (m): mesial augmented sinus height, ASH (d): distal augmented sinus height, OAH (m): mesial original alveolar bone height, OAH (d): distal original alveolar bone height, MBL: marginal bone loss, I: implant fixture length, C: crown length.

Table 2. Life table analysis.

Time (mo)	Implant at risk	Failure during interval	Interval survival (%)	CSR (%)
0-6	45	2	95.56	95.56
7-12	43	0	100	95.56
13-18	32	0	100	95.56
19-24	18	0	100	95.56
25-30	6	0	100	95.56
31-36	1	0	100	95.56
37-42	1	0	100	95.56

CSR: cumulative survival rate.

Table 3. Radiographic analysis (mean \pm SD).

C/I ratio	MBL (mm)		RHO (mm)	
	Time (mo)		Time (mo)	
	0-12	0-42	0-12	0-42
Mean	1.19 \pm 0.24	0.29 \pm 0.42	0.52 \pm 0.56	0.83 \pm 0.38
			0.88 \pm 0.39	

C/I ratio: crown/implant ratio, MBL: marginal bone loss, RHO: reduced height of Osteon.

Table 4. Differences according to the timing of implantation (mean \pm SD).

	Simultaneous (n=34)	Delayed (n=11)	P-value (<0.05)
RHO (mm)	0.80 \pm 0.40	0.91 \pm 0.30	0.299

RHO: reduced height of Osteon.

months was measured as 0.29 \pm 0.42 mm and up to 42 months as 0.52 \pm 0.56 mm. The RHO 1 year postoperatively was 0.83 \pm 0.38 mm, and at 42 months postoperatively was 0.88 \pm 0.39 mm (Table 3). No significant correlation was noted between the RHO and follow up periods by Spearman's test ($P=0.102$). There were no statistically significant differences in the reduced height of Osteon depending on simultaneous or delayed implantation ($P=0.299$; Table 4) and particle size of the Osteon ($P=0.644$; Table 5). In addition, no significant difference in the RHO was observed according to the site of implantation ($P=0.527$; Table 6).

DISCUSSION

An ideal material for maxillary sinus augmentation should provide biocompatibility to allow bone ingrowth and have a space maintaining property to prevent sinus pneumatization [24]. In the results of the present study, the grafted Osteon was well maintained in the sinus and decreased slightly over a 3.5-year time period, demonstrating that it is a clinically suitable material for sinus augmentation.

Some volumetric loss of grafted material is unavoidable because of the air pressure from respiration in the maxillary sinus regardless of the type of material used [2,25,26]. Therefore, the change in the height of the grafted material is an important factor for implant stability.

Previous studies about the loss of grafted material have been mixed. Hatano et al. [27] used autogenous bone and xenogenous bone mixed at a ratio of 2:1 for sinus augmentation with simultaneous implant placement and evaluated the resorption rate. They reported that statistically significant resorption had occurred after 2-3 years, and the maxillary sinus floor was observed at a similar level or slightly below that of the implant apex. On the other hand, Maiorana et al. [28] evaluated the resorption rate after 4 years of maxillary sinus aug-

Table 5. Differences according to the type of material (mean \pm SD).

	S (n=22)	S/L (n=23)	P-value (<0.05)
RHO (mm)	0.81 \pm 0.43	0.85 \pm 0.33	0.644

S: small particle size (0.5-1 mm), L: large particle size (1-2 mm), RHO: reduced height of Osteon.

Table 6. Differences according to the site of implants (mean \pm SD).

	P2 (n=8)	M1 (n=22)	M2 (n=15)	P-value (<0.05)
RHO (mm)	0.92 \pm 0.42	0.85 \pm 0.34	0.75 \pm 0.42	0.527

P2: the 2nd premolar, M1: the 1st molar, M2: the 2nd molar, RHO: reduced height of Osteon.

mentation using synthetic bone graft material (hydroxyapatite and collagen). The survival of implants was 97% and the grafted material remained steady, showing a 0.5-1 mm resorption height. Generally, it was reported that the resorption rate is influenced by the type of graft material [2]. The resorption rate was 1.76 mm in autograft, 2.09 mm in allograft (freeze-dried demineralized bone), and 0.96 mm in alloplast (hydroxyapatite).

The maxillary sinus cavity is a kind of contained defect surrounded by sinus basal bone and the Schneiderian membrane; thus it has excellent healing potential even without bone graft materials. From this perspective, the long-lasting synthetic and xenogenic bone materials are considered to be a better choice in terms of material resorption.

Two out of 45 implants were removed in this study before prosthetic loading, so this can be regarded as an early failure. It seems that excessive hematoma causes the formation of exuberant granulation tissue, which can be detrimental to initial osseointegration. The overall CSR was 95.56%, and this result was comparable with other studies despite the small sample size [1-4].

The reduction in volume of the Osteon was higher than in our previous report (0.48 mm resorption in 13 months) [17]. No significant difference in the reduced volume of the Osteon was observed according to the timing of implantation. From our previous studies, it was reported that the largest amount of Osteon resorption occurred in the 1st molar area and the augmented sinus membrane was changed from a convex shape to a flat shape. In this study, however, there was no correlation between the area of the implantation and the resorption rate.

Interestingly, the resorption of Osteon occurred regardless of the flow of time. In most other papers, it was found that the graft materials might undergo gradual resorption and pneumatization by time [2,27]. Hieu et al. [29] radiographically evaluated the changes in height of the xenogenic materials (Bio-Oss, Geistlich Sons, Wolhusen, Switzerland; OCS-B, Ni-

bec, Seoul, Korea) after maxillary sinus augmentation over the course of 2 years. This study reported that significant material resorption can take place over time. Nonetheless, it could be assumed that many other factors, e.g., the air pressure in the maxillary sinus, the form of augmented material, and the density of the grafted material, are more important than the time flow. Therefore, it is possible that the resorption rate of the grafted material is affected by the host's environment. This would be expected to be clarified with further study.

Two dimensional panoramic radiographs have been used to evaluate the grafted material and its relationship with implants [27,30,31]. Recently, a study utilizing computed-tomography and magnetic resonance imaging assessed the grafted sinus floor and this showed more accurate results on the volumetric change [32]. However, in the present study, we used only 2-dimensional images; thus further study using 3-dimensional images would provide a more accurate volumetric measurement of Osteon.

Within the limitations of this study, it can be suggested that Osteon may have predictable results when it was used as a grafting material for sinus floor augmentation due to its excellent osteoconductive property.

CONFLICT OF INTEREST

No potential conflict of interest relevant to this article was reported.

ACKNOWLEDGMENTS

This research was supported by Basic Science Research Program through the National Research Foundation of Korea (NRF) funded by the Ministry of Education, Science and Technology (R13-2003-013-04002-0).

REFERENCES

1. Chiapasco M, Zaniboni M, Rimondini L. Dental implants placed in grafted maxillary sinuses: a retrospective analysis of clinical outcome according to the initial clinical situation and a proposal of defect classification. *Clin Oral Implants Res* 2008;19:416-28.
2. Jensen OT, Shulman LB, Block MS, Iacono VJ. Report of the Sinus Consensus Conference of 1996. *Int J Oral Maxillofac Implants* 1998;13 Suppl:11-45.
3. Pjetursson BE, Tan WC, Zwahlen M, Lang NP. A systematic review of the success of sinus floor elevation and survival of implants inserted in combination with sinus floor elevation. *J Clin Periodontol* 2008;35(8 Suppl):216-40.
4. Wallace SS, Froum SJ. Effect of maxillary sinus augmentation on the survival of endosseous dental implants. A systematic review. *Ann Periodontol* 2003;8:328-43.
5. Hallman M, Hedin M, Sennerby L, Lundgren S. A prospective 1-year clinical and radiographic study of implants placed after maxillary sinus floor augmentation with bovine hydroxyapatite and autogenous bone. *J Oral Maxillofac Surg* 2002;60:277-84.
6. Johansson B, Grepe A, Wannfors K, Hirsch JM. A clinical study of changes in the volume of bone grafts in the atrophic maxilla. *Dentomaxillofac Radiol* 2001;30:157-61.
7. Misch CE, Dietsch F. Bone-grafting materials in implant dentistry. *Implant Dent* 1993;2:158-67.
8. Dalkýz M, Ozcan A, Yapar M, Gökay N, Yüncü M. Evaluation of the effects of different biomaterials on bone defects. *Implant Dent* 2000;9:226-35.
9. Kim YK, Yun PY, Kim SG, Lim SC. Analysis of the healing process in sinus bone grafting using various grafting materials. *Oral Surg Oral Med Oral Pathol Oral Radiol Endod* 2009;107:204-11.
10. Daculsi G, LeGeros RZ, Nery E, Lynch K, Kerebel B. Transformation of biphasic calcium phosphate ceramics in vivo: ultrastructural and physicochemical characterization. *J Biomed Mater Res* 1989;23:883-94.
11. Gauthier O, Bouler JM, Aguado E, Pilet P, Daculsi G. Macroporous biphasic calcium phosphate ceramics: influence of macropore diameter and macroporosity percentage on bone ingrowth. *Biomaterials* 1998;19:133-9.
12. Karabuda C, Ozdemir O, Tosun T, Anil A, Olgaç V. Histological and clinical evaluation of 3 different grafting materials for sinus lifting procedure based on 8 cases. *J Periodontol* 2001;72:1436-42.
13. Nery EB, LeGeros RZ, Lynch KL, Lee K. Tissue response to biphasic calcium phosphate ceramic with different ratios of HA/beta TCP in periodontal osseous defects. *J Periodontol* 1992;63:729-35.
14. Yamada S, Heymann D, Bouler JM, Daculsi G. Osteoclastic resorption of biphasic calcium phosphate ceramic in vitro. *J Biomed Mater Res* 1997;37:346-52.
15. Yamada S, Heymann D, Bouler JM, Daculsi G. Osteoclastic resorption of calcium phosphate ceramics with different hydroxyapatite/beta-tricalcium phosphate ratios. *Biomaterials* 1997;18:1037-41.
16. Kim YK, Yun PY, Lim SC, Kim SG, Lee HJ, Ong JL. Clinical evaluations of OSTEON as a new alloplastic material in sinus bone grafting and its effect on bone healing. *J Biomed Mater Res B Appl Biomater* 2008;86:270-7.
17. Lee JH, Jung UW, Kim CS, Choi SH, Cho KS. Maxillary sinus augmentation using macroporous biphasic calcium phosphate (MBCP(TM)): three case report with histologic

- evaluation. *J Korean Acad Periodontol* 2006;36:567-77.
18. Zitzmann NU, Schärer P. Sinus elevation procedures in the resorbed posterior maxilla. Comparison of the crestal and lateral approaches. *Oral Surg Oral Med Oral Pathol Oral Radiol Endod* 1998;85:8-17.
 19. Zarb GA, Zarb FL. Tissue integrated dental prostheses. *Quintessence Int* 1985;16:39-42.
 20. Boyne PJ, James RA. Grafting of the maxillary sinus floor with autogenous marrow and bone. *J Oral Surg* 1980;38:613-6.
 21. Kent JN, Block MS. Simultaneous maxillary sinus floor bone grafting and placement of hydroxylapatite-coated implants. *J Oral Maxillofac Surg* 1989;47:238-42.
 22. Cutler SJ, Ederer F. Maximum utilization of the life table method in analyzing survival. *J Chronic Dis* 1958;8:699-712.
 23. Buser D, Weber HP, Lang NP. Tissue integration of non-submerged implants. 1-year results of a prospective study with 100 ITI hollow-cylinder and hollow-screw implants. *Clin Oral Implants Res* 1990;1:33-40.
 24. Block MS, Kent JN, Kallukaran FU, Thunthy K, Weinberg R. Bone maintenance 5 to 10 years after sinus grafting. *J Oral Maxillofac Surg* 1998;56:706-14.
 25. Chanavaz M. Maxillary sinus: anatomy, physiology, surgery, and bone grafting related to implantology--eleven years of surgical experience (1979-1990). *J Oral Implantol* 1990;16:199-209.
 26. Chanavaz M, Francke JP, Donazzan M. The maxillary sinus and implantology. *Chir Dent Fr* 1990;60:45-54.
 27. Hatano N, Shimizu Y, Ooya K. A clinical long-term radiographic evaluation of graft height changes after maxillary sinus floor augmentation with a 2:1 autogenous bone/xenograft mixture and simultaneous placement of dental implants. *Clin Oral Implants Res* 2004;15:339-45.
 28. Maiorana C, Sigurtà D, Mirandola A, Garlini G, Santoro F. Sinus elevation with alloplasts or xenogenic materials and implants: an up-to-4-year clinical and radiologic follow-up. *Int J Oral Maxillofac Implants* 2006;21:426-32.
 29. Hieu PD, Chung JH, Yim SB, Hong KS. A radiographical study on the changes in height of grafting materials after sinus lift: a comparison between two types of xenogenic materials. *J Periodontal Implant Sci* 2010;40:25-32.
 30. Kahnberg KE, Ekkestubbe A, Gröndahl K, Nilsson P, Hirsch JM. Sinus lifting procedure. I. One-stage surgery with bone transplant and implants. *Clin Oral Implants Res* 2001;12:479-87.
 31. Keller EE, Eckert SE, Tolman DE. Maxillary antral and nasal one-stage inlay composite bone graft: preliminary report on 30 recipient sites. *J Oral Maxillofac Surg* 1994;52:438-47.
 32. Gray CF, Redpath TW, Bainton R, Smith FW. Magnetic resonance imaging assessment of a sinus lift operation using reoxidised cellulose (Surgicel) as graft material. *Clin Oral Implants Res* 2001;12:526-30.