

Masticator space abscess in a 47-day-old infant

Eunhee Kim, MD¹, Ju Hee Jeon, MD², Yoon Hee Shim, MD², Kyu-Seok Lee, MD³, So Young Kim, MD⁴, Eun Ryoung Kim, MD²

¹Department of Pediatrics, Gwang-Myeong Sung-Ae General Hospital, Gwangmyeong, Departments of ²Pediatrics, ³Otorhinolaryngology, and ⁴Radiology, Sung-Ae General Hospital, Seoul, Korea

Received: 13 December 2010, Revised: 7 January, 2011

Accepted: 1 March 2011

Corresponding author: Eun Ryoung Kim, MD
Department of Pediatrics, Sung-Ae General Hospital, 451-5 Singil 1-dong, Yeongdeungpo-gu, Seoul 150-960, Korea
Tel: +82-2-840-7230, Fax: +82-2-840-7755
E-mail: eunicu@hotmail.com

Copyright © 2011 by The Korean Pediatric Society

A 47-day-old male infant presented with fever, poor oral intake, irritability, and right-sided bluish buccal swelling. Contrast-enhanced computed tomography of the neck showed a round mass lesion of about 2.0×1.5 cm that suggested abscess formation in the right masticator space. Ultrasound-guided extraoral aspiration of the abscess at the right masseter muscle was successful. *Staphylococcus aureus* was identified in the culture from the aspirated pus and blood. Appropriate antibiotics were given and the patient recovered. The patient underwent follow-up ultrasonography that showed an improved state of the previously observed right masseter muscle swelling at about 1 month after hospital discharge. A masticator space abscess usually originates from an odontogenic infection in adults. We report a case of masticator space abscess in a 47-day-old infant in whom septicemia without odontogenic infection was suspected.

Key words: Abscess, Infant, Bacteremia

This is an open-access article distributed under the terms of the Creative Commons Attribution Non-Commercial License (<http://creativecommons.org/licenses/by-nc/3.0/>) which permits unrestricted non-commercial use, distribution, and reproduction in any medium, provided the original work is properly cited.

Introduction

The masticator space is defined as the separate fascial compartment containing the pterygoid, masseter and temporalis muscles and the mandible^{1,2}. Masticator space abscess represents an advanced stage of a commonly odontogenic infection indicated by buccal pain, swelling and trismus³. Jaw swelling and trismus after a dental procedure are the typical clinical manifestations of a masticator space abscess in adults^{4,5}. Masticator space abscess without dental procedure is an uncommon infection and can be seen with poor sucking, irritability, fever and dehydration in the infant. It is imperative that a meticulous medical history be obtained and a thorough physical examination be completed in infants with such clinical symptoms¹. The clinical diagnosis is usually obvious, but it is confirmed by ultrasonography (US) or computed tomography (CT)^{1,5}.

Masticator space abscess has not been reported in newborns, and rarely been reported in infants. Here we report a 47 day old male

diagnosed as masticator space abscess with nonspecific symptoms without evidence of dental disease, traumatic injuries to the head and neck, or parotid swelling¹.

Case report

A 47 day old male was admitted for fever, poor oral intake, irritability and right side mild bluish buccal swelling which have persisted for two days ago. He was born 3.47 kg at term by repeated Caesarean section. He was admitted for neonatal jaundice at the 5th day of life, but was generally healthy after discharge. He had no airway compromise, respiratory symptoms, or traumatic injuries. He received a bacille de calmette-guerin vaccine, and a first and second hepatitis B vaccination on schedule. He was fed by breast milk. He had no known drug allergies and was not taking any medication. He had no specific family history of recurrent infections except the cervical cancer of his aunt.

There were no inflammatory sign in the oral cavity and no discharge from Stensen's duct orifice. There were no other abnormal findings on physical examination.

Laboratory findings were as following: leukocytes 19,110/ μ L (segmented neutrophil 47.3%), platelet 516,000/ μ L, hemoglobin 12.6 g/dL, sodium 137 mmol/L, potassium 5.47 mmol/L, chloride 100

mmol/L, amylase 7 IU/L, CRP 7.425 mg/dL, and mumps virus immunoglobulin M negative. *Staphylococcus aureus* (methicillin sensitive staphylococcus aureus, MSSA) was cultured from blood.

The first US taken at second hospital day revealed a mild cellulitis of the right cheek and soft tissue. Follow up ultrasonography was taken at the 5th hospital day. Early abscess formation at the right masticator space was suspected, but there was no inflammatory sign at the right parotid area on the second US (Fig. 1A). CT scan taken at 8th hospital day showed abscess formation at the right masticator space with adjacent cellulitis (Fig. 2).

The patient was referred to the Dental and Otorhinolaryngologic Department for a complete evaluation of odontogenic and oral/pharyngeal inflammation. No dental or gingival disease were observed.

The abscess was aspirated under the third US guidance at the 10th hospital day. One milliliter of turbid pus was aspirated and sent for culture and susceptibility tests. Ampicillin and cefotaxime was given intravenously to cover gram positive and gram negative bacteriae from the date of admission and clindamycin was added to cover anaerobes after the confirmation of abscess formation and aspiration of pus. *S. aureus* was isolated from the aspirated pus. The second blood culture sampled at the 6th hospital day showed no bacterial growth.

Fever had been subsided and swollen area had been reduced in size. The patient was discharged on the 16th hospital day with oral cefnidir. Antibiotics were continued for 5 days in outpatient clinic. Follow up US taken after a week from discharge showed no abscess in right masticator space, but right masseter muscle swelling and cortical irregularity on right mandible were still present. We checked the US taken after a month from discharge showed an improved state of the previously observed right masseter muscle and mandible lesion (Fig. 1B).

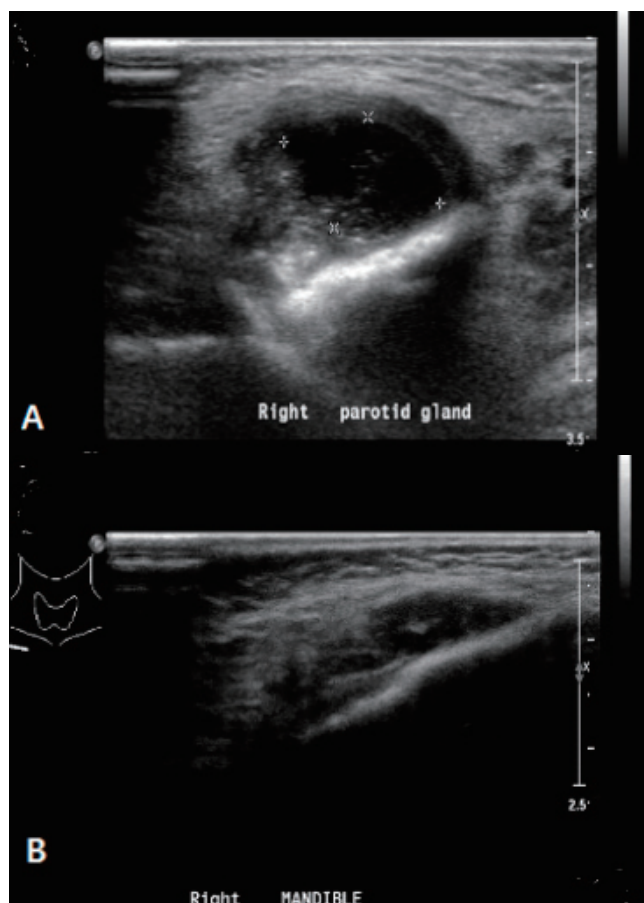


Fig. 1. Ultrasonography of face and neck. (A) At the 5th hospital day, early abscess formation was seen in the right masticator space. (B) The previously seen masseter muscle swelling was decreased at about 1 month after discharge.

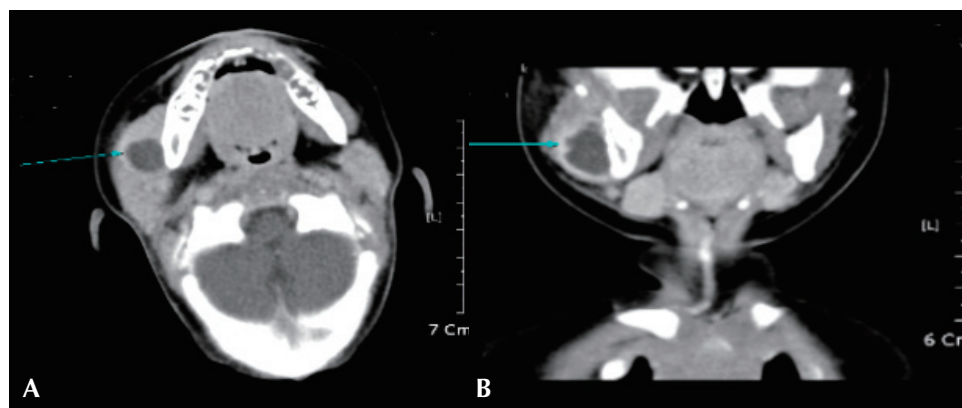


Fig. 2. Computed tomography scan showed abscess formation (arrow) in the right masticator space combined with adjacent cellulitis at the 7th hospital day.

Discussion

A lesion arising within the masticator space tends to displace the parapharyngeal space posteromedially as it expands⁶. Children with deep neck abscesses, defined as involving the retropharyngeal or parapharyngeal regions; anterior or posterior triangle; the submandibular or submental areas and the parotid glands, present clinically different from adults⁷. Children younger than 4 years of age sometimes present with fever, agitation, nutritional problems caused by dysphagia, drooling, poor oral intake and respiratory illnesses like cough, stridor and respiratory distress⁷. Children younger than 6 years of age do not often present with trismus¹.

The hallmark of masticator space abscesses under one year of age is not obvious, but it may manifest by the swelling of the cheek² and irritability during pressure on the affected site.

The most common lesions underlying the masticator space abscess are odontogenic infections, which are encountered more frequently than neoplasm^{3,6}. Most infections of the masticator space arise from the molars, especially the third molar². The most common route of spread is posteriorly and medially extending to the temporal space without breakdown of the space barriers or it can break through the cervical fascia and spread medially to the parapharyngeal space². Infiltration of the muscles by infectious spread from dental caries or as a complication of tooth extractions are frequently seen⁶. However, there was no case originated from odontogenic infections in children without dental procedure. The patient in this report had the masticator space abscess without a dental procedure and no obvious source of infection in the oral cavity.

Daramola et al.⁸ reported that there were parotid space, submandibular space, posterior neck and submandibular masticator space abscesses in pediatric patients and other studies showed that pediatric neck abscesses may arise from necrotic lymph nodes in limited cases. Small uncomplicated deep neck space abscesses may respond to intravenous antibiotics alone or antibiotics with needle aspiration^{7,9,10}. Recently, ultrasonography had been recognized not only as diagnostic tool in the management of abscesses in the maxillofacial region but also as therapeutic tool¹¹.

This patient presented with right posterior buccal swelling, thus parotitis had to be excluded². Palpation is quite helpful in differential diagnosis since in parotid swelling, tenderness is mostly felt at the region of the gland along the posterior border of the masseter muscle, while a submasseteric abscess causes tenderness anteriorly². A thorough history must always be taken, and parotid disease can be suspected if pain increases during meals². Clinical suspicion of masticator space abscess could be given in this patient because he showed irritability during pressure on the anterior border of the

affected parotid region and no abnormality of the right parotid gland was observed by ultrasonography.

CT scanning with contrast is performed as an important tool because it can locate the site of lesion and extent of head and neck infections. Whether it is a cellulitis or an abscess, its size, and its location are particularly revealed in relation to the great vessels¹².

In this patient, CT scan showed abscess formations in the right masseter muscle with adjacent cellulitis with no parotid space inflammation. Ultrasound-guided aspiration of masticator space abscess was done and 1ml of pus from the abscess was obtained. The *S. aureus* we obtained from the culture of pus is also the most common organism responsible for parotid disease¹³. According to Cotichia et al.⁷, it is also the most common causative organism in infants younger than 12 months of age with deep neck infections, whereas group A streptococcus is more frequently identified in older children. The patient has no clearly identifiable source of infection, but *S. aureus* was cultured from the initial blood test.

Daramola et al.⁸ reported that empiric antibiotic coverage for deep neck space abscesses must consider aerobic and anaerobic pathogens that synthesize beta-lactamase. According to Yang et al.¹⁴, Penicillin G is the drug of choice for infections caused by streptococci, and non-penicillinase-producing staphylococci, which represent the majority of aerobic organisms. Clindamycin is effective against all streptococci, most pneumococci, and most penicillin-resistant (but not methicillin-resistant) staphylococci. Third-generation parenteral cephalosporins have a broad spectrum of activity against enteric gram-negative rods. The patient was managed with ampicillin, cefotaxime, and clindamycin and the result of second blood culture showed no growth. He took the third generation cephalosporin drug, cefnidir, after discharge. MSSA cultured from this patient was sensitive to cephalothin, ceftazidime, and cefotaxime. However, we think the first generation cephalosporin drugs, cephalothin or ceftazidime, were better than the third generation cephalosporin drug.

The patient had a follow-up US which showed an improved state of the previously observed right masseter muscle swelling after about 1 month from the hospital discharge. We will continue to observe for any changes in it.

In conclusion, an infant with nonspecific symptoms such as fever, poor oral intake, irritability and right side mild bluish buccal swelling may indicate deep neck infections. US and CT scans of the head and neck, detailed history taking and physical examination would be important in identifying and adequately treating this infection.

References

1. Steelman R, Milczuk H, Grosz A. Masticator space abscess in a 21-month-

- old child. *Int J Pediatr Otorhinolaryngol Extra* 2006;1:185-7.
- Balatsouras DG, Kloutsos GM, Protopapas D, Korres S, Economou C. Submasseteric abscess. *J Laryngol Otol* 2001;115:68-70.
 - Schuknecht B, Stergiou G, Graetz K. Masticator space abscess derived from odontogenic infection: imaging manifestation and pathways of extension depicted by CT and MR in 30 patients. *Eur Radiol* 2008; 18:1972-9.
 - Khanna G, Sato Y, Smith RJ, Bauman NM, Nerad J. Causes of facial swelling in pediatric patients: correlation of clinical and radiologic findings. *Radiographics* 2006;26:157-71.
 - Sivarajasingam V, Sharma V, Crean SJ, Shepherd JP. Ultrasound-guided needle aspiration of lateral masticator space abscess. *Oral Surg Oral Med Oral Pathol Oral Radiol Endod* 1999;88:616-9.
 - Johnson BA. Suprahyoid head and neck tumors. *Proceedings of Advanced MRI 2002, from Head to toe-the cutting edge, Vermed, Fortbildung in der Medizin; 2002 May 2-4;37-40.*
 - Coticchia JM, Getnick GS, Yun RD, Arnold JE. Age-, site-, and time-specific differences in pediatric deep neck abscesses. *Arch Otolaryngol Head Neck Surg* 2004;130:201-7.
 - Daramola OO, Flanagan CE, Maisel RH, Odland RM. Diagnosis and treatment of deep neck space abscesses. *Otolaryngol Head Neck Surg* 2009;141:123-30.
 - Brook I. Microbiology and management of peritonsillar, retropharyngeal, and parapharyngeal abscesses. *J Oral Maxillofac Surg* 2004;62:1545-50.
 - Nagy M, Pizzuto M, Backstrom J, Brodsky L. Deep neck infections in children: a new approach to diagnosis and treatment. *Laryngoscope* 1997;107(12 Pt 1):1627-34.
 - Al-Belasy FA. Ultrasound-guided drainage of submasseteric space abscesses. *J Oral Maxillofac Surg* 2005;63:36-41.
 - Nagy M, Backstrom J. Comparison of the sensitivity of lateral neck radiographs and computed tomography scanning in pediatric deep-neck infections. *Laryngoscope* 1999;109:775-9.
 - Kaban LB, Troulis MJ. *Pediatric oral and maxillofacial surgery*. Philadelphia: WB Saunders, 2004:198.
 - Yang SW, Lee MH, See LC, Huang SH, Chen TM, Chen TA. Deep neck abscess: an analysis of microbial etiology and the effectiveness of antibiotics. *Infect Drug Resist* 2008;1:1-8.