



# Treatment of steroid-resistant pediatric nephrotic syndrome

Hee Gyung Kang, MD, PhD

Division of Pediatric Nephrology, Department of Pediatrics, Research Center for Rare Diseases, Seoul National University Children's Hospital, Seoul National University College of Medicine, Seoul, Korea

Received: 22 June 2011, Accepted: 22 August 2011  
Corresponding author: Hee Gyung Kang, MD, PhD  
Division of Pediatric Nephrology, Department of Pediatrics, Seoul National University Children's Hospital, Seoul National University College of Medicine, 101 Daehak-ro, Jongno-gu, Seoul 110-744, Korea  
Tel: +82-2-2072-0658, Fax: +82- 2-2072-0274  
E-mail: kanghg@snu.ac.kr

Copyright © 2011 by The Korean Pediatric Society

This is an open-access article distributed under the terms of the Creative Commons Attribution Non-Commercial License (<http://creativecommons.org/licenses/by-nc/3.0/>) which permits unrestricted non-commercial use, distribution, and reproduction in any medium, provided the original work is properly cited.

Children who suffer from steroid-resistant nephrotic syndrome (SRNS) require aggressive treatment to achieve remission. When intravenous high-dose methylprednisolone fails, calcineurin inhibitors, such as cyclosporine and tacrolimus, are used as the first line of treatment. A significant number of patients with SRNS progress to end-stage renal disease if remission is not achieved. For these children, renal replacement therapy can also be problematic; peritoneal dialysis may be accompanied by significant protein loss through the peritoneal membrane, and kidney allograft transplantation may be complicated by recurrence of SRNS. Plasmapheresis and rituximab were initially used for treatment of recurrent SRNS after transplantation; these are now under consideration as rescue therapies for refractory SRNS. Although the prognosis of SRNS is complicated and unfavorable, intensive treatment in the early stages of the disease may achieve remission in more than half of the patients. Therefore, timely referral of pediatric SRNS patients to pediatric nephrology specialists for histological and genetic diagnosis and treatment is highly recommended.

**Key words:** Nephrotic syndrome, Steroid-resistant, Treatment, Calcineurin inhibitor, Transplantation, Child

## Introduction

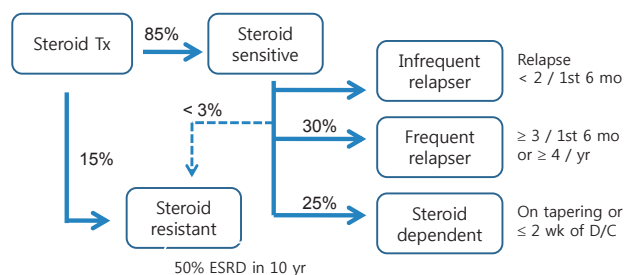
While most of the children who presented with primary nephrotic syndrome (NS) respond to steroid treatment, 10 to 20% of these children do not achieve remission despite receiving second or third-line of treatment (Fig. 1), and more than half of the patients progress to end-stage renal disease (ESRD) within 10 years<sup>1)</sup>. Thus, various modalities have been tried to induce remission in these patients. In this review, several commonly-practiced treatments will be reviewed while simultaneously following the progression of a clinical case of

pediatric steroid-resistant nephrotic syndrome (SRNS).

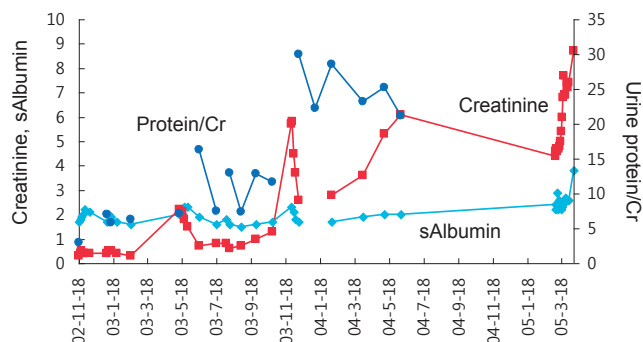
## Pharmacological treatment of SRNS

### 1. Case; Part 1

A 5-years-old boy was transferred to our center for treatment of steroid-resistant nephrotic syndrome. He had developed edema with proteinuria and did not respond to oral steroid treatment. Kidney biopsy revealed focal segmental glomerulosclerosis with segmental mesangial hypercellularity and segmental sclerosis in 7%



**Fig. 1.** Outcomes of childhood-onset nephrotic syndrome. Tx, treatment; ESRD, end-stage renal disease; D/C, steroid discontinuation.



**Fig. 2.** Clinical course of a case of steroid-resistant nephrotic syndrome. Cr, creatinine.

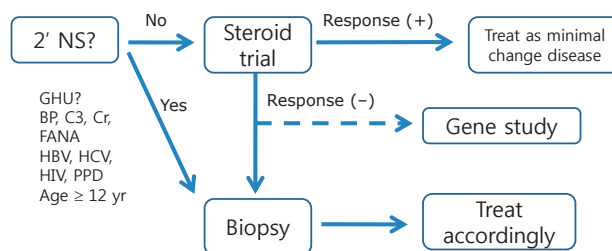
of glomeruli. To achieve remission, intravenous methylprednisolone pulse therapy and cyclosporine treatment were attempted (Fig. 2).

### 1) SRNS

SRNS is defined as NS that does not respond to one month's treatment with oral prednisolone at a dosage of 60 mg/m<sup>2</sup>/day. When SRNS is suspected, a meticulous search for the possibility of concurrent infection (e.g., sinusitis and skin infection), drug interaction (e.g., antiepileptic drugs), inappropriate dosage, or compliance problem is necessary. If those possibilities are ruled out, tissue diagnosis from a kidney biopsy is the next step. Histological findings of SRNS are, and occasionally, a secondary glomerulopathy such as amyloidosis is unexpectedly found. At the same time, mutational analysis for genes known to cause SRNS is recommended. Mutations of *WT1*, *INF2*, *LAMB2*, *ACTN4*, *NPHS1*, and *NPHS2* have been found in Korean children with SRNS by Cheong et al.<sup>2-5</sup>. While more aggressive treatment is required to achieve remission in the case of SRNS of unknown cause (primary SRNS) to achieve remission, such an aggressive treatment is not effective for those with SRNS that arises from genetic causes; therefore genetic testing may shield these children from the unnecessary side effects of immunosuppressive medications (Fig. 3).

### 2) Methylprednisolone pulse treatment

When oral prednisolone treatment fails, intravenous methyl-



**Fig. 3.** Approach of childhood-onset nephrotic syndrome. NS, nephrotic syndrome; GHU, Gross hematuria; BP, blood pressure; FANA, fluorescent antinuclear antibody test; HBV, Hepatitis B virus; HCV, Hepatitis C virus; HIV, Human immunodeficiency virus; PPD, purified protein derivative.

prednisolone pulse therapy (30 mg/kg, every other day, 6 doses in total) is commonly tried. The original treatment protocol developed by Mendoza et al.<sup>6</sup>; however, remission rates as high as 70% were reported with this protocol. The current practice involves the administration of 3 to 6 doses of high-dose intravenous methylprednisolone before kidney biopsy, and patients who respond to this treatment are often regarded as responsive to steroid therapy. Commonly encountered side effects of methylprednisolone pulse treatment are infection, Cushing's syndrome, hypertension, glucose intolerance, and arrhythmia during infusion.

### 3) Calcineurin inhibitors (CNI)

Cyclosporine and tacrolimus (FK-506) were originally introduced as immunosuppressive agents for allograft transplantation due to their inhibitory effect on calcineurin, a key signal transduction molecule activating T lymphocytes. In the past, the anti-proteinuric effect of calcineurin inhibitors (CNIs) was believed to arise from their immunosuppressive effect on lymphocytes<sup>7</sup>. However, CNI CNIs have recently been found to stabilize the cytoskeleton of glomerular epithelial cells (podocytes) and thereby reduce glomerular proteinuria<sup>8</sup>. This effect explains why cyclosporine has partial success in some cases of proteinuria of proteinuria arising from genetic causes<sup>9</sup>. The response rate of SRNS to cyclosporine is roughly 40 to 60. A typical SRNS treatment protocol using cyclosporine involves the administration of cyclosporine (150 to 200 mg/m<sup>2</sup>/day) and prednisolone (30 mg/m<sup>2</sup>/day) for 1 month, followed by alternate-day prednisolone for 5 months; this has been shown to result in complete remission in 42% of recipients within the first 6 months<sup>10</sup>. Cyclosporine has a well-known spectrum of side effects such as nephrotoxicity, infection, hypertension, hyperkalemia, renal tubular acidosis, tremor, glucose intolerance, gum hypertrophy, and hirsutism. The therapeutic drug level (trough) of cyclosporine is <100-200 ng/mL.

Another CNI, tacrolimus, is also used in the treatment of SRNS, although Korean Food and Drug Administration has not approved

this medication for treatment of NS<sup>11</sup>). The dosage of tacrolimus for SRNS is 0.05 to 1 mg/kg/day with a trough level <5 to 10  $\mu\text{g/L}$ . Tacrolimus has a similar spectrum of side effects as cyclosporine but does not cause gum hypertrophy or hirsutism.

#### 4) Alkylating agents and anti-proliferative agents

While cyclophosphamide or chlorambucyl have been used in early reports; however, a recent review by the Children's Nephrotic Syndrome Consensus Conference concluded that these alkylating agents were not superior to steroid mono-therapy<sup>12</sup>). Additionally, mofetil<sup>13</sup>) and sirolimus<sup>14</sup>) have also been tried recently with moderate results.

### Non-conventional treatment of SRNS

#### 1. Case; Part 2 (Fig. 4)

Despite various treatments, the patient's proteinuria and hypoalbuminemia did not disappear and instead progressed to end-stage renal disease (ESRD) in 2 years and 1 month (Fig. 1). Peritoneal dialysis was started at the age of 8 years and 3 months. After 4 years, the patient received cadaveric donor kidney transplantation. Following the surgery, his serum creatinine level began to drop, but soon increased again to staggering levels. At the same time, his serum albumin level began to decrease as well. Urine albumin levels were found to be 3+.

#### 1) Renal replacement therapy for children with nephrotic syndrome

##### (1) Dialysis

When kidney function deteriorates and progresses to ESRD, there are 3 options for renal replacement: hemodialysis, peritoneal dialysis, and transplantation. Peritoneal dialysis requires less strict diet control and enables a more flexible life style; therefore, peritoneal dialysis

is preferred to hemodialysis in pediatric patients, despite the risk of complicating peritonitis. Protein loss through the kidneys in children with SRNS diminishes with the deterioration of kidney function and their intractable edema improves accordingly. On peritoneal dialysis. However, protein loss through the peritoneal membrane may develop with peritoneal dialysis, especially in children with SRNS, as documented at our center<sup>15</sup>). Therefore, the possibility of protein malnutrition should be considered and adequate nutritional support is required.

##### (2) Kidney transplantation

Kidney transplantation is by far the most advantageous modality of renal replacement for children, since only with kidney transplantation normal or near-normal growth can be achieved only with kidney transplantation. Currently, the outcomes of kidney transplantation are excellent with one-year survival of 93%, 10-year survival rates of around ~80%, and a median graft survival time of >15 years. However, children with SRNS run the risk of recurrence of NS following transplantation, as illustrated in the case. Recurrence often precipitates delayed graft function, acute rejection, and poor graft outcomes<sup>16</sup>). Nevertheless, the expected graft survival rate of kidney allograft in patients with SRNS is as good as that of cadaveric donors; therefore, SRNS is not a contraindication for kidney transplantation.

##### (3) Recurrence of SRNS after transplantation

Risk factors for SRNS recurrence following transplantation include childhood-onset SRNS, age of onset greater than 5-6 years, rapid progression to ESRD, and recurrence following a previous allograft<sup>17</sup>). On the other hand, cases of secondary SRNS, such as those secondary to infection, medication, reflux nephropathy, or obesity, and SRNS arising from genetic causes are not likely to recur<sup>18</sup>).

Recurrence often develops within 48 hours of transplantation. Other possible diagnoses of post-transplant proteinuria include chronic allograft rejection, de novo glomerulopathy, and proteinuria from the native kidneys. Nevertheless, significant proteinuria following kidney transplantation in SRNS patients should be presumed to be a recurrence. In this case, aggressive and timely treatment with plasmapheresis and/or high-dose cyclosporine (250 to 350 ng/mL) or rituximab is required, since treatment within 48 hours of recurrence is the only modifiable factor that can effect the remission of recurrent SRNS. For prompt detection of recurrence, meticulous monitoring of pediatric SRNS patients is required following kidney transplantation; urinalysis with protein quantitation must be performed everyday for 2 weeks after transplantation, followed by testing once a week for 1 month, then once a month for 1 year<sup>17</sup>).

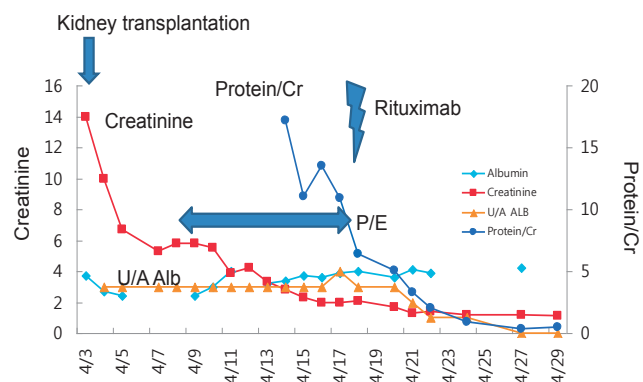


Fig. 4. Clinical course of the case after kidney transplantation. U/A, urinalysis; Alb, albumin; P/E, plasmapheresis

## 2) Plasmapheresis

Observations of SRNS recurrence following graft resulted in the introduction of the concept of a ‘circulating permeability factor’ as a pathogenic mechanism of SRNS<sup>19</sup>. Thus, the first-line treatment to avoid recurrence is to remove the ‘permeability factor’ by plasmapheresis therapy. Plasmapheresis replaces patient’s plasma containing the ‘permeability factor’ with 4 to 5% albumin solution or fresh frozen plasma. Immediate initiation of this treatment may induce remission in 50 to 90% of recurrent cases<sup>20</sup>.

Reports of favorable outcomes of plasmapheresis in patients with recurrent SRNS resulted in the application of this treatment modality in primary SRNS of native kidneys, with success in some cases<sup>21</sup>. However, it is not yet possible to predict patient responsiveness to this procedure, and the effectiveness of pre-emptive plasmapheresis to prevent SRNS recurrence following transplantation has not yet been established.

## 3) Rituximab

Rituximab is a monoclonal antibody against CD20, a marker of B cells, which is manufactured as a therapeutic agent for B cell lymphoma. Following the report of a case of post-transplant lymphoproliferative disease where rituximab treatment eradicated both recurrent SRNS and B cell lymphoma after kidney transplantation<sup>22</sup>, this biological agent has been used for SRNS as a rescue treatment<sup>23</sup> with success rate of 20 to 50%. However, treatment indications and an optimal rituximab treatment protocol have not yet been established, and significant adverse effects such as opportunistic infections and rituximab-associated lung injury<sup>24</sup> have been reported.

## Conclusion

### Case; Part 3

The patient was treated with plasmapheresis and his proteinuria and hypoalbuminemia improved gradually. To eradicate his nephrotic syndrome, we gave him one dose of rituximab, and complete remission was achieved. He has been in a state of remission for more than two years.

Although the prognosis of SRNS is complicated and unfavorable, intensive treatment in the early stage of the disease may achieve remission in more than half of the patients. Thus, timely referral of these patients to pediatric nephrology specialists for histological and genetic diagnosis and treatment is highly recommended.

## Acknowledgement

This study was supported by a grant from the Korea Healthcare Technology R&D Project, Ministry for Health and Welfare, Republic of Korea (A080588).

## References

- Mekahli D, Liutkus A, Ranchin B, Yu A, Bessenay L, Girardin E, et al. Long-term outcome of idiopathic steroid-resistant nephrotic syndrome: a multicenter study. *Pediatr Nephrol* 2009;24:1525-32.
- Lee HK, Han KH, Jung YH, Kang HG, Moon KC, Ha IS, et al. Variable renal phenotype in a family with an INF2 mutation. *Pediatr Nephrol* 2011;26:73-6.
- Lee BH, Ahn YH, Choi HJ, Kang HK, Kim SD, Cho BS, et al. Two Korean infants with genetically confirmed congenital nephrotic syndrome of finnish type. *J Korean Med Sci* 2009;24(Suppl 1):S210-4.
- Choi HJ, Lee BH, Cho HY, Moon KC, Ha IS, Nagata M, et al. Familial focal segmental glomerulosclerosis associated with an ACTN4 mutation and paternal germline mosaicism. *Am J Kidney Dis* 2008;51:834-8.
- Cho HY, Lee JH, Choi HJ, Lee BH, Ha IS, Choi Y, et al. WT1 and NPHS2 mutations in Korean children with steroid-resistant nephrotic syndrome. *Pediatr Nephrol* 2008;23:63-70.
- Mendoza SA, Reznik VM, Griswold WR, Krensky AM, Yorgin PD, Tune BM. Treatment of steroid-resistant focal segmental glomerulosclerosis with pulse methylprednisolone and alkylating agents. *Pediatr Nephrol* 1990;4:303-7.
- Sharma M, Sharma R, McCarthy ET, Savin VJ. The focal segmental glomerulosclerosis permeability factor: biochemical characteristics and biological effects. *Exp Biol Med (Maywood)* 2004;229:85-98.
- Faul C, Donnelly M, Merscher-Gomez S, Chang YH, Franz S, Delfgaauw J, et al. The actin cytoskeleton of kidney podocytes is a direct target of the antiproteinuric effect of cyclosporine A. *Nat Med* 2008;14:931-8.
- Bensman A, Niaudet P. Non-immunologic mechanisms of calcineurin inhibitors explain its antiproteinuric effects in genetic glomerulopathies. *Pediatr Nephrol* 2010;25:1197-9.
- Fuchshuber A, Jean G, Gribouval O, Gubler MC, Broyer M, Beckmann JS, et al. Mapping a gene (SRN1) to chromosome 1q25-q31 in idiopathic nephrotic syndrome confirms a distinct entity of autosomal recessive nephrosis. *Hum Mol Genet* 1995;4:2155-8.
- Choudhry S, Bagga A, Hari P, Sharma S, Kalaivani M, Dinda A. Efficacy and safety of tacrolimus versus cyclosporine in children with steroid-resistant nephrotic syndrome: a randomized controlled trial. *Am J Kidney Dis* 2009;53:760-9.
- Ingulli E, Tejani A. Incidence, treatment, and outcome of recurrent focal segmental glomerulosclerosis posttransplantation in 42 allografts in children--a single-center experience. *Transplantation* 1991;51:401-5.
- Sener A, Bella AJ, Nguan C, Luke PP, House AA. Focal segmental glomerular sclerosis in renal transplant recipients: predicting early disease recurrence may prolong allograft function. *Clin Transplant* 2009;23:96-100.
- Hristea D, Hadaya K, Marangon N, Buhler L, Villard J, Morel P, et al. Successful treatment of recurrent focal segmental glomerulosclerosis after kidney transplantation by plasmapheresis and rituximab. *Transpl Int*

- 2007;20:102-5.
15. Ahn YH, Jung E, Lee SE, Lee HK, Lee SH, Kang HG, et al. Peritoneal protein loss in nephrotic syndrome on peritoneal dialysis. *J Korean Soc Pediatr Nephrol* 2009;13:189-96.
  16. Senggutuvan P, Cameron JS, Hartley RB, Rigden S, Chantler C, Haycock G, et al. Recurrence of focal segmental glomerulosclerosis in transplanted kidneys: analysis of incidence and risk factors in 59 allografts. *Pediatr Nephrol* 1990;4:21-8.
  17. Vinai M, Waber P, Seikaly MG. Recurrence of focal segmental glomerulosclerosis in renal allograft: an in-depth review. *Pediatr Transplant* 2010;14:314-25.
  18. Benoit G, Machuca E, Antignac C. Hereditary nephrotic syndrome: a systematic approach for genetic testing and a review of associated podocyte gene mutations. *Pediatr Nephrol* 2010;25:1621-32.
  19. McCarthy ET, Sharma M, Savin VJ. Circulating permeability factors in idiopathic nephrotic syndrome and focal segmental glomerulosclerosis. *Clin J Am Soc Nephrol* 2010;5:2115-21.
  20. Cheong HI, Han HW, Park HW, Ha IS, Han KS, Lee HS, et al. Early recurrent nephrotic syndrome after renal transplantation in children with focal segmental glomerulosclerosis. *Nephrol Dial Transplant* 2000;15:78-81.
  21. Vécsei AK, Müller T, Schratzberger EC, Kircher K, Regele H, Arbeiter K, et al. Plasmapheresis-induced remission in otherwise therapy-resistant FSGS. *Pediatr Nephrol* 2001;16:898-900.
  22. Nozu K, Iijima K, Fujisawa M, Nakagawa A, Yoshikawa N, Matsuo M. Rituximab treatment for posttransplant lymphoproliferative disorder (PTLD) induces complete remission of recurrent nephrotic syndrome. *Pediatr Nephrol* 2005;20:1660-3.
  23. Prytuła A, Iijima K, Kamei K, Geary D, Gottlich E, Majeed A, et al. Rituximab in refractory nephrotic syndrome. *Pediatr Nephrol* 2010; 25:461-8.
  24. Lands LC. New therapies, new concerns: rituximab-associated lung injury. *Pediatr Nephrol* 2010;25:1001-3.