

Ultrasound-guided Nerve Blocks for Post-hernia Repair Pain

Department of Anesthesiology and Pain Medicine, Asan Medical Center,
University of Ulsan College of Medicine, Seoul, Korea

Jeong Gill Leem, MD

Chronic pain is the most frequent long-term complication of treating inguinal hernia. It may restrict the patient's daily activities for several years postoperatively. Onset of post-hernia repair pain usually occurs immediately after surgery [1], and predictive factors include repair of recurrent hernia, preoperative pain, severe early postoperative pain, younger age, psychological vulnerability or psychiatric disorder, and workers' compensation [1,2]. There are two predominant types of post-hernia repair pain: nociceptive pain, due predominantly to inflammation, and neuropathic pain, due to nerve injury. The most common type of postoperative pain is nociceptive pain presenting with tenderness along the inguinal ligament and radiation to the thigh. Nociceptive pain after hernia repair, commonly characterized as tender, gnawing, or pounding, is mostly due to tissue damage by sutures or mesh fixation devices. The suggested underlying pathomechanism is chronic inflammation resulting from tissue injury [3]. Neuropathic pain is typically a result of surgical injury to a specific nerve(s) such as the ilioinguinal, iliohypogastric, the genital branch of the genitofemoral or lateral femoral cutaneous nerve. Nerve injury may be caused by partial or complete nerve sectioning, entrapment by sutures and mesh fixation devices, or unintended trauma (e.g., contusion, electrocautery), subsequently causing irritation and compression by foreign material and scar tissue. Neuro-

pathic pain is characterized by a transient electrical stabbing or burning pain that occurs either spontaneously or after provocation test. Treatments include medical treatment, injection of local anesthetics with or without steroids, cryotherapy, and behavioral therapy [1-3]. Chemical neurolysis or surgical revision with radical neurectomy may be required for some patients [4,5].

The following actual case illustrates one potential pitfall of ultrasound-guided nerve blocks for diagnosis and treatment of neuralgic pain following laparoscopic inguinal hernia repair. A 44-year-old woman was referred to our pain clinic for management of persistent right inguinal area pain after laparoscopic right herniorrhaphy performed 5 days previously. She was diagnosed with right inguinal hernia and chronic cholecystitis. She had undergone laparoscopic right herniorrhaphy with placement of mesh by autosuture and cholecystectomy at our general surgery department.

Immediately following the procedure, the patient experienced severe right inguinal pain radiating to the medial and lateral area of her right thigh. Pain was exacerbated by walking, leg raising and increased in intensity over time. Suspecting that the neuralgia was secondary to ilioinguinal nerve entrapment by autclip or mesh, the patient underwent surgical exploration including laparoscopic mesh reposition and autclip removal 2 days after the original

Correspondence to: Jeong Gill Leem, MD

Department of Anesthesiology and Pain Medicine, Asan Medical Center, University of Ulsan College of Medicine, 388-1, Pungnap 2-dong, Songpa-gu, Seoul 138-736, Korea

Tel: +82-2-3010-3861, Fax: +82-2-3010-6790, E-mail: jgleem@amc.seoul.kr

© This is an open-access article distributed under the terms of the Creative Commons Attribution Non-Commercial License (<http://creativecommons.org/licenses/by-nc/3.0/>), which permits unrestricted non-commercial use, distribution, and reproduction in any medium, provided the original work is properly cited.

Copyright © The Korean Pain Society, 2010

surgery. After removing autoclips, the patient experienced slight improvement in her medial thigh pain, but still complained of pain in her lateral thigh that caused severe limitation of the patient's daily activities. Symptomatic treatment with oral medication, including trileptal 300 mg, and pregabalin 300 mg, were given daily. As these conservative medications were not effective, the patient was referred to our clinic.

Based on pain distribution, the patient had ultrasonography-guided local anesthetic (lidocaine) injections in the ilioinguinal nerve and lateral femoral cutaneous nerves twice. The pain responded to regional nerve blocks immediately after first injection, even though no complete resolution of pain was achieved. After the second block, she had a significant (>50%) reduction in her pain and was able to ambulate.

Ultrasound-guided nerve block has been investigated and used in human anesthesia over the past 15 years. Compared with other imaging techniques, ultrasonography holds some crucial advantages such as complete elimination of radiation exposure, direct visualization of nerves and adjacent anatomical structures (blood vessels, muscles, bones, and tendons), direct visualization of the spread of local anesthetic during injection, with the possibility of

repositioning the needle in cases of maldistribution, avoidance of intraneural or intravascular injections and reduction of local anesthetic doses [6,7]. Therefore, accurately placed local anesthetic can have faster onset, more predictable duration and overall improvement of block quality. For ilioinguinal and iliohypogastric nerve block, the patient is placed in a supine position, and the anterior superior iliac spine (ASIS) and inguinal ligament are identified as surface landmarks. A linear probe of high frequency (6–13 MHz) is oriented perpendicular to the inguinal ligament and is first positioned so the lateral aspect of the probe lies on top of the iliac crest, just posterior to ASIS. Ilioinguinal and iliohypogastric nerves are sought in the fascial plane between the internal oblique and transverse abdominus muscle. The ilioinguinal nerve is usually found close to the iliac crest, and the iliohypogastric nerve lies medial to it (Fig. 1A). The peritoneal fascia and peritoneal cavity lie deep to the transverse abdominus muscle, and peristaltic movements of the bowel may be detected. The needle is advanced to the fascial plane between the internal oblique and transversus abdominal muscles and is placed adjacent to the ilioinguinal and iliohypogastric nerves. Five ml of local anesthetic with or without steroid is infiltrated into the split fascial plane. For lateral femoral cutaneous nerve

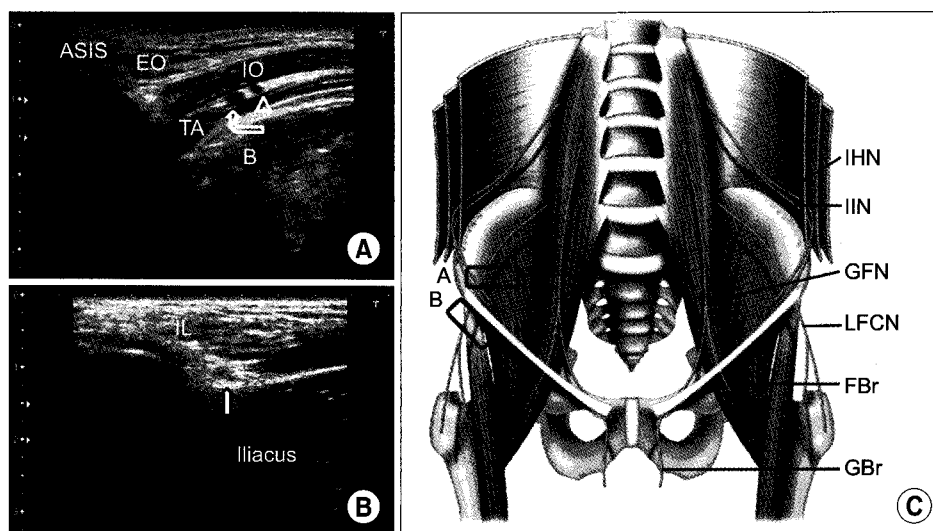


Fig. 1. Ultrasound-guided nerve blocks for post-hernia repair pain. (A) Transverse 10 MHz ultrasound image obtained medial to the anterior superior iliac spine (ASIS). Ilioinguinal (curved arrow) and iliohypogastric nerve (arrow head) lie in the fascial plane between internal oblique (IO) and transverse abdominus (TA) muscles. EO: external oblique muscle, B: bowel. (B) Oblique 12 MHz ultrasound image obtained caudal to the anterior superior iliac spine. Lateral femoral cutaneous nerve (LFCN) lies medial to ASIS just below the inguinal ligament (IL). (C) Course of the ilioinguinal (IIN), iliohypogastric (IHN), genitofemoral (GFN) and lateral femoral cutaneous nerves (LFCN) through the muscular layers of the abdomen. FBr: femoral branch of the GFN, GBr: genital branch of the GFN.

block, ASIS is identified via high frequency probe as a hyperechoic structure with posterior acoustic shadowing. The lateral end of the linear probe is placed on the ASIS and the medial end angled slightly in a caudal direction so the transducer is parallel with the inguinal ligament. The transducer is gently moved in a medial-caudal direction while the operator searches for the echo signature of the lateral femoral cutaneous nerve (Fig. 1B). Tiny genital branches of the genitofemoral nerve enter the inguinal canal at the deep inguinal ring and run adjacent to the external spermatic vessels in male or round ligaments in female. Patients complaining of symptoms consistent with injury to this nerve are very rare [8]. Therefore, infiltration of local anesthetics or neurectomy of this nerve is not advocated as a standard procedure.

In conclusion, ultrasound-guided block of the border nerves and lateral femoral cutaneous nerve can be useful for assisting in diagnosis and therapy of post-hernia repair pain. Ultrasonography offers pain physicians a readily available imaging modality with which to perform these interventions in a safe and accurate manner.

REFERENCES

1. Aasvang E, Kehlet H. Chronic postoperative pain: the case of inguinal herniorrhaphy. *Br J Anaesth* 2005; 95: 69–76.
2. O'Dwyer PJ, Alani A, McConnachie A. Groin hernia repair: postherniorrhaphy pain. *World J Surg* 2005; 29: 1062–5.
3. Nienhuijs SW, Boelens OB, Strobbe LJ. Pain after anterior mesh hernia repair. *J Am Coll Surg* 2005; 200: 885–9.
4. Aasvang E, Kehlet H. Surgical management of chronic pain after inguinal hernia repair. *Br J Surg* 2005; 92: 795–801.
5. Amid PK. A 1-stage surgical treatment for postherniorrhaphy neuropathic pain: triple neurectomy and proximal end implantation without mobilization of the cord. *Arch Surg* 2002; 137: 100–4.
6. Gofeld M. Ultrasonography in pain medicine: a critical review. *Pain Pract* 2008; 8: 226–40.
7. Abrahams MS, Aziz MF, Fu RF, Horn JL. Ultrasound guidance compared with electrical neurostimulation for peripheral nerve block: a systematic review and meta-analysis of randomized controlled trials. *Br J Anaesth* 2009; 102: 408–17.
8. Vuilleumier H, Hübner M, Demartines N. Neuropathy after herniorrhaphy: indication for surgical treatment and outcome. *World J Surg* 2009; 33: 841–5.