



- 이문환, 김응창¹, 이수연², 박래준³
- 한국국제대학교 물리치료학과; ¹을지대학교 보건대학원 물리치료학과; ²대구대학교 대학원 재활과학과 물리치료전공; ³대구대학교 재활과학대학 물리치료학과

The Effects of Taping on Metacarpophalangeal Disorders of the Thumb

Moon-Hwan Lee, PT, PhD; Eung-Chang Kim, PT¹; Soo-Yeon Lee, PT, MS²; Rae-Joon Park, PT, PhD³

Department of Physical Therapy, International University of Korea; ¹Department of Physical Therapy, Graduate School of Public Health, Eulji University; ²Department of Rehabilitation Science, Major in Physical Therapy, Daegu University; ³Department of Physical Therapy, College of Rehabilitation Science, Daegu University

Purpose: This study investigated the effect of taping therapy on metacarpophalangeal (MCP) disorders of the thumb.

Methods: Twenty eight patients were enrolled in this study. They were randomly assigned to experimental (n=16) or a control group (n=12). The experimental and control groups received Ultrasound (Gymna Pulson 200) operating at a frequency of 3MHz and an intensity of 1.0W/cm² with a 100% duty cycle for 10 minutes. The experimental group received, additionally, taping using Kinesiotape on the injured thumb. The following parameters were measured: pain during rest and flexion of the thumb, tenderness, range of motion (ROM), pinch and spherical grip power pre- and post-treatment. This study was carried out 3 days per week throughout the 2-week treatment.

Results: There were significant improvements in pain during rest and flexion of the thumb, tenderness, ROM, pinch and spherical grip power between pre- and post-treatment times in both groups (p<0.05). However, there was a significant difference in all parameters between the experimental and control groups (p<0.05). Finally, the satisfaction level after intervention was significantly higher in the experimental group than in the control group (p<0.05).

Conclusion: Taping is effective for treating pain and dysfunction in patients with thumb disorders.

Keywords: Taping, Thumb, Metacarpophalangeal, MCP, Pain

논문접수일: 2009년 11월 11일

수정접수일: 2009년 12월 15일

게재승인일: 2010년 01월 25일

교신저자: 이수연, serhan0520@hanmail.net

I. Introduction

The term “Gamekeeper’s thumb” is an injury to the ulnar collateral ligament in metacarpophalangeal (MCP) joint of the thumb.¹ This term was initially coined by Campbell in 1955, to describe a chronic injury of the ulnar collateral ligament of the thumb in which the injury follows a valgus injury to the abducted thumb.² The alternative term, “Skier thumb” coined by Gerber et al. in 1981, is used widely in

Europe to describe an acute rupture of the ulnar collateral ligament of the thumb from forced abduction of the proximal phalanx.³ The essential characteristic of this injury is that it occurred through a direct blow to the thumb or falls onto the abducted thumb, and is not associated with skiing accidents.²

After an injury to the MCP joint of the thumb, previous studies on various treatment approaches were classified into orthosis and surgical repair. In a relatively early period after an injury, an orthosis can immobilize the

thumb, decrease the level of pain, and prevent further injury.⁴⁻⁶ However, surgery is recommended if there is more than 25% joint involvement.⁷⁻⁹

Although several authorities advocated the effect of orthosis as a conservative method, the most frequent complications associated with orthosis are itching, pain, joint contracture, and pressure sores.⁴ In addition, disuse atrophy and swelling can occur as a result of poor blood circulation.

A splint applied to the thumb incorrectly can lead to acute compression neuropathy of the ulnar digital nerve of the thumb similar to a Bowler's thumb.¹⁰ This is a compressive neuropathy caused by an external neural mechanical pressure applied to the ulnar digital nerve of the thumb from a splint.

Most previous studies have focused the outcomes of surgery and orthosis of the MCP disorders. But in addition to the above mentioned treatments, there are various therapies available that can be used for patients in clinics and athletes in sports. One of them is taping. Taping has no side effects from immobilization and pressure from an orthosis, no complications from surgery, and can apply easily by untrained personnel. Taping has been reported to be effective in treating musculoskeletal disorders in the elbow,¹¹ shoulder,¹² knee,¹³⁻¹⁵ and back.¹⁶

Taping studies in previous were mostly related to the gross muscles and large joints. However, there is a paucity of reports related to functional improvement and pain control in a small joint such as the thumb.

Therefore, this study examined the effect of taping on a MCP joint disorder of the thumb in patients recommended for conservative treatment by doctors in a rehabilitation medicine clinic.

II. Methods

1. Subjects

Twenty eight patients with a traumatic injury to the MCP joint of the thumb were enrolled in this study. The patients were assigned randomly to an experimental group (male: 6, female: 10) and control group (male: 5, female: 7). Patients with pain from a thumb fracture or a stenosing tenosynovitis were excluded. Outpatients with a sprain of ulnar (medial) and radial (lateral) collateral ligament through a physical and manual examination were included. All subjects signed a written informed consent form and participated in the study voluntarily. Table 1 shows the general characteristics of the subjects.

Table 1. General characteristics of the subjects

		Experimental group	Control group	p
Gender	male	6	5	0.83
	female	10	7	
Age (years)		37.31±13.03	32.33±10.21	0.28
Height (cm)		170.18±6.01	160.16±27.16	0.16
Weight (kg)		58.75±16.09	58.16±13.55	0.92
Involved side	right	12	9	1.00
	left	4	3	

All values were expressed by Mean±SD

2. Design

The experimental and control group received Ultrasound (Gymna Pulson 200) operating at a frequency of 3 MHz and an intensity of 1.0 W/cm² with a 100% duty cycle for 10 minutes. And then experimental group received additionally Taping on the injured thumb. All patients underwent pre-treatment measurement sessions that included the resting pain, pain during flexion of the MP joint, tenderness, active ROM of thumb flexion, and the pinch and spherical grip power. After applying these treatments for 3 days per week over a 2-week treatment period, the pre-treatment measurements were repeated and the subjective level of satisfaction was measured at the end of the intervention.

3. Taping procedure

Normally 20 cm and 30 cm lengths of Kinesio tape with a 2 cm width, or 50 cm lengths with a 1.5 cm width as a single strip were prepared. The methods for applying the tape were as follows: Step 1) 20 cm of Kinesio taping was applied from the dorsal side of interphalangeal joint via the MCP joint to the middle of the forearm in the direction of the abductor pollicis. Step 2) The middle of a 50 cm piece of taping as a sling was attached from around the palmar side of the thumb to approximately the MCP joint, and crossed in the dorsal side of the painful MCP joint and wound around the ulnar side of the wrist finally ending at the radial side of the forearm. Step 3) Finally, in order to maintain external rotation, 30 cm taping was applied diagonally from the interphalangeal joint to the end of the dorsum of the forearm (Figure 1).

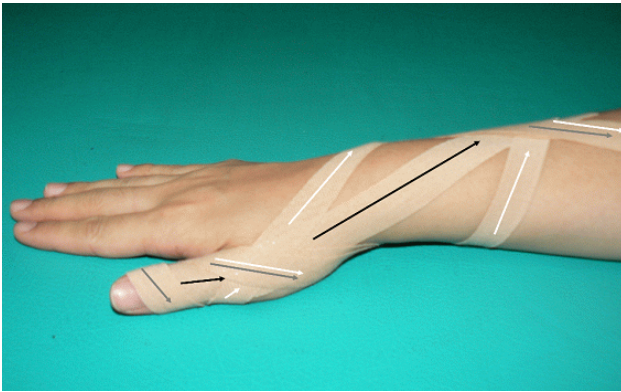


Figure 1. Applying methods of taping therapy. Black colored arrows indicates step 1. White colored arrows indicate step 2. Gray colored arrows indicate step 3.

4. Measurements

1) A resting pain

When there was no resistance by the thumb or wrist, the subjects described the degree of pain degree using a 10-point VAS (visual analogue scale, 0=none; 10=maximum). The change between the pre- and post-treatment was determined.

2) A pain in flexion of MCP joint on the thumb

The subjective pain score (VAS) was recorded in a MCP joint after the subjects performed the maximal voluntary flexion of the thumb.

3) Tenderness

The subjective pain score (VAS) was recorded in the MCP joint after the painful area was pressed with the therapists thumb.¹⁷

4) Active thumb flexion ROM of MCP joint

The active ROM during flexion of the MCP joint on the thumb was measured using a goniometer (Preston, USA).

5) A pinch grip power

The maximal pinch grip that occurs when a force is applied primarily between the fingers and thumb was measured using a dynamometer (Baseline Hydraulic Pinch Gauge, BASELINE, USA).

6) A spherical grip power

A hand dynamometer (Baseline Pneumatic Squeeze Dynamometer, BASELINE, USA) was used to measure the maximal power grip, which occurs when a force is applied primarily between the fingers and palm with the fingers

wrapped around the object being held and the thumb overlapping the index finger.

7) Satisfaction level

The 10-point Satisfaction level was measured as the cognitive product of a comparison between pre-treatment and post-treatment. The subjects were asked to report their level of satisfaction with the treatment with reference to the last 2 weeks independently of their objective health status.

5. Data analysis

A paired t-test was used to test for any significant differences between the mean of the pre-treatment and post-treatment scores in the two groups. An independent samples Student's t-test was used to test for the differences between the experimental and control groups at the baseline on all of the measured variables. A p value <0.05 was considered significant.

III. Results

1. Resting pain

The resting pain of the experimental and control groups was significantly lower after treatment than before treatment ($p<0.05$)(Table 2).

2. Pain in flexion of MCP joint on the thumb

The pain in flexion of the thumb in the experimental and control groups was significantly lower after treatment than before treatment ($p<0.05$)(Table 2).

3. Tenderness

The tenderness on pressure in the experimental and control groups was significantly lower after treatment than before treatment ($p<0.05$)(Table 2).

4. Active thumb flexion ROM of MCP joint

The active thumb flexion ROM of the MCP joint in the experimental and control groups was significantly higher after treatment than before treatment ($p<0.05$)(Table 2).

5. Pinch grip power

The pinch grip power of the experimental and control groups was significantly higher after treatment than before treatment ($p<0.05$)(Table 2).

6. Spherical grip power

The spherical grip power of the experimental and control groups was significantly higher after treatment than before treatment ($p < 0.05$) (Table 2).

Table 2. The effect of kinesio-taping therapy on experimental variables

		Pre	Post	t	p
Resting pain (score)	Exp.	4.81±0.91	1.94±0.57	8.45	0.00
	Cont.	4.42±1.08	3.00±1.21	2.54	0.02
Pain in flexion (score)	Exp.	6.06±0.77	2.94±0.85	13.05	0.00
	Cont.	6.25±0.75	4.50±1.38	4.70	0.00
Tenderness (score)	Exp.	6.38±0.62	3.88±1.02	10.35	0.00
	Cont.	6.17±0.83	4.83±0.72	4.30	0.00
Active ROM (degree)	Exp.	59.63±9.67	85.00±4.08	-9.03	0.00
	Cont.	55.42±7.82	62.92±5.82	-3.00	0.00
Pinch grip (lb)	Exp.	28.13±5.74	43.75±3.42	-11.49	0.00
	Cont.	30.42±7.53	40.00±7.69	-3.83	0.00
Spherical grip (lb)	Exp.	40.00±4.83	65.95±8.41	-10.33	0.00
	Cont.	40.42±7.53	55.42±10.54	-4.69	0.00

All values were expressed by Mean±SD
Exp: Experimental group, Cont: Control group

7. Differences between experimental and control group

The resting pain, pain in flexion, tenderness, active thumb flexion ROM, pinch grip and spherical grip power, and the subjective level of satisfaction showed significantly more improvement in the experimental group than in the control group ($p < 0.05$) (Table 3).

Table 3. Effect of taping on all measurements between groups

	Exp. Group	Cont. group	t	p
Resting pain (score)	2.87±1.36	1.42±1.94	2.35	0.02
Pain during flexion (score)	3.13±0.96	1.75±1.29	3.24	0.00
Tenderness (score)	2.50±0.97	1.33±1.07	3.01	0.00
Active ROM (score)	25.38±11.24	7.50±8.66	4.57	0.00
Pinch grip (lb)	15.63±5.44	9.58±8.65	2.26	0.03
Spherical grip (lb)	25.94±10.04	15.00±11.08	2.73	0.01
Satisfaction level (score)	7.00±0.73	6.08±1.00	2.81	0.00

All values were expressed by Mean±SD
Exp: Experimental group, Cont: Control group

IV. Discussion

Opposition of the thumb is a remarkable and important component of the human hand function, and occurs as a result of combined movements in flexion, abduction and axial rotation at the carpometacarpal, MCP and interphalangeal joints.¹⁸ Coordinated movements in these joints are interrupted by an injury to the non contractible tissue from direct trauma or an injury to the muscle and nerve from pressure or trauma.⁷

Conservative treatment with a splint may be used in a ligament sprain. However, surgical repair should be used to treat a complete rupture of the ligament or avulsion fracture and for instability over 30 degree in the ulnar collateral ligament of the MCP joint.^{8,9}

Fairhurst and Hansen² reported that 22 painful sides of the ulnar collateral ligament of the MCP joint of the thumb in 21 patients from January 1994 to June 1997 were repaired by alignment reconstruction and the patients were reviewed from 6 months to 3 years after surgery. The result of their study showed that functional stability had been restored in all patients but two thumbs suffered ongoing MCP joint pain. All but one patient returned to their original employment.

Surgical repair of acute or complete ligament injuries at the MCP joint of the thumb is still controversial.² Sawant et al⁵ reported that between 1996 and 2003, 9 injured fingers in 7 patients with avulsion fractures of the MCP joint and fracture fragment sizes between 10% and 25% of the width of the articular surface on the radiograph were managed non-surgically by early active mobilization using neighbor strapping for 4~6 weeks. After a follow up of 57 months, there was a significant improvement in the mean VAS and DASH (Disability of Arm Shoulder and Hand) score. They suggested that even avulsion fractures in cases with up to 25% involvement of the articular surface can be treated successfully without surgery.

Sollerman et al⁶ treated 63 consecutive injured thumbs of the ulnar collateral ligament of the MCP joint with a plaster cast or a functional splint, which allowed flexion and extension of the MCP joint with a restraint of the ulnar and radial deviation of the thumb. At the follow-up examination performed after 15(11~41) months, there were no differences in stability, range of motion, strength of the injured thumb and length of sick leave between the plaster cast and functional splint groups. However, the patients preferred the splint over plaster cast immobilization. Therefore, they reported that the functional results of this splint were equal to plaster cast immobilization after both

surgical and nonsurgical treatment, and the splint and plaster cast were effective conservative treatments.

This study examined the effect of taping on the treatment of thumb disorders with pain in flexion in patients who visited a rehabilitation clinic with no complete ligament rupture and fracture on the radiograph. The experimental groups showed significant improvement in the resting pain, pain in flexion of the thumb, tenderness, active flexion ROM, and pinch grip and spherical grip power after the 2 week treatment.

The principle for the effects of taping is unclear. However, there are several possible mechanisms. First is Gate control theory. If tape is applied to the injured side, the tactile input by the taping stimulates the activity of the large primary afferents fibers, which enhance the interneuron activity of substantia gelatinosa (SG) as a gate of pain and transmission cells (T) in the spinal cord. The SG interneurons reduce the membrane potential of the afferent terminals, which induce presynaptic inhibition because the small fibers for pain does not synapse with the CNS.¹⁵

Second, if the muscles are stiffened or injured, the afferent input of the pain signal is increased. Taping using an unstretched method, which is performed by stretching the muscles and joints maximally in the affected area, will produce convolutions in the skin when the skin and muscles contract back to their normal position. As the tonic tensile force in a muscle itself decreases and there is myofascia between the muscles and skin, there is less sensitization of the pain transmission afferent neurons, which are continuously irritated. Therefore, the afferent input of the pain signal is reduced and the pain is alleviated.

In this study, taping was applied along the pain area. Hence, it is believed that the tactile stimulus by Taping produced presynaptic inhibition. Secondly, the pain was believed to have decreased as a result of the diminished sensitization of the pain transmission afferent neurons due to the reduced tonic tensile force of muscles.

A review of previous studies into the effect of taping by Lee and Park¹¹ showed that post-treatment with Kinesio Taping in lateral epicondylitis patients had a larger effect on the pain and grip power than the pre-treatment. In addition, Cowan et al¹³ and Herrington¹⁴ reported that medial glide tape fixation, as corrective patellar taping, was effective in patellofemoral pain syndrome (PFPS) patients. Moreover, Ju and Lee¹⁶ reported that Kinesio Taping on hernia of intervertebral disc (HIVD) patients significantly decreased the level of pain and increased the strength of the erector spinae muscles. Park and Kim¹² and Son et al¹⁵ reported that Kinesio Taping for degenerative arthritis of the knee had a significant effect on the ROM and a pain.

Nevertheless, above mentioned studies were related to the gross muscles and large joints. Although applying the conclusions of preceding studies to this study is unreasonable due to the different joints treated in this study, it is believed that taping is effective in pain reduction and producing functional improvement, regardless of the treated regions.

The limitation of this study was that effects of nonsteroid anti inflammation drug or steroidal injection were not excluded. However, post-treatment with taping after 2 weeks showed significant pain reduction and functional improvement compared with pre-treatment without taping. This shows that taping therapy is effective. In addition, it is believed that taping therapy produces high subjective satisfaction levels as well as good treatment results.

As stated above, splinting and surgical intervention are effective treatments. However taping provides the mobility to give a free range of motion for muscles on account of its elasticity with similar fixation to a splint and strap. Therefore patients can move properly within the painless range of motion and carry out their daily activities. In addition the improved blood circulation by movements produces a quicker recovery. It is believed that taping is more effective than immobilization only.

Although various types of tape, including Kinesio Taping, have contributed to pain reduction, functional improvement and an increase of athletic ability in patients and athletes, there are no reports on the effect of taping on fingers. This is the first trial study on the effect of taping on pain in the MCP joint, particularly the thumb.

V. Conclusion

These study results were suggested that application of Taping in patients who complain of pain from a sprain and injury to the MCP joint of the thumb may decrease the level of pain, increase the ROM and grip power, and improve the level of satisfaction of patients.

Author Contributions

Research design: Lee SY

Acquisition of data: Lee MH

Analysis and interpretation of data: Park RJ

Drafting of the manuscript: Kim EC, Lee MH

Administrative, technical, and material support: Park RJ, Lee SY

Research supervision: Lee SY

Reference

1. Jackson M, McQueen MM. Gamekeeper's thumb: a quantitative evaluation of acute surgical repair. *Injury*. 1994;25(1):21-3.
2. Fairhurst M, Hansen L. Treatment of "Gamekeeper's thumb" by reconstruction of the ulnar collateral ligament. *J Hand Surg Br*. 2002;27(6):542-5.
3. Davies MB, Wright JED, Edwards MSD. True skier's thumb in childhood. *Injury*. 2002;33(2):186-7.
4. Hart RG, Kleinert HE, Lyons K. A modified thumb spica splint for thumb injuries in the ED. *Am J Emerg Med*. 2005;23(6):777-81.
5. Sawant N, Kulikov Y, Giddins GE. Outcome following conservative treatment of metacarpophalangeal collateral ligament avulsion fractures of the finger. *J Hand Surg Eur Vol*. 2007;32(1):102-4.
6. Sollerman C, Abrahamsson SO, Lundborg G et al. Functional splinting versus plaster cast for ruptures of the ulnar collateral ligament of the thumb. A prospective randomized study of 63 cases. *Acta Orthop Scand*. 1991;62(6):524-6.
7. Arranz López J, Alzaga F, Molina J. Acute ulnar collateral ligament injuries of the thumb metacarpophalangeal joint: an anatomical and clinical study. *Acta Orthop Bleg*. 1998;64(4):378-84.
8. Hastings H 2nd, Carroll C 4th. Treatment of closed articular fractures of the metacarpophalangeal and proximal interphalangeal joints. *Hand Clin*. 1988;4(3):503-27.
9. Henry M. Fractures and dislocation of the hand. In: Bucholz RW, Heckman JD, eds, *Rockwood and Green's Fractures in Adults*, Philadelphia, Lippincott Williams & Wilkins, 2001:701.
10. Kagel EM, Rayan GM. Thumb digital neuropathy caused by splinting. *J Okla State Med Assoc*. 2000;93(9):435-6.
11. Lee MH, Park RJ. The effects of ultra sound and taping treatment on the pain and grip strength in lateral epicondylitis. *J Kor Soc Phys Ther*. 2004;16(1):124-39.
12. Park YS, Kim HJ. Effects of a taping method on pain and ROM of the knee joint in the elderly. *J Korean Acad Nurs*. 2005;35(2):372-31.
13. Cowan SM, Bennell KL, Hodges PW. Therapeutic patellar taping changes the timing of vasti muscle activation in people with patellofemoral pain syndrome. *Clin J Sport Med*. 2002;12(6):339-47.
14. Herrington L. The effect of patellar taping on quadriceps peak torque and perceived pain: a preliminary study. *Physical Therapy in Sport*. 2001;2(1):23-8.
15. Son GS, Lee MH, Lee CR et al. The effects of kenesio taping on the pain and functional improvement in patients with degenerative arthritis. *Korean Journal of Sport Biomechanics*. 2008;18(1):45-52.
16. Ju SB, Lee WJ. The effects of kinesio taping and exercise therapy program on Lumbar extension muscle strength, visual analogue scale in operation patients of Lumbar disk herniation. *The Korean Journal of Physical Education*. 2006;45(3):537-46.
17. Lee MH, Ma SY, Lee HHE et al. Effects of kinesio taping therapy in patients with stenosing tenosynovitis. *J Kor Soc Phys Ther*. 2007;19(1):1-9.
18. Cooney WP 3rd, Lucca MJ, Chao EY et al. The kinesiology of the thumb trapeziometacarpal joint. *J Bone Joint Surg Am*. 1981;63(9):1371-81.