

Success and Failure of Surgical Endodontic Treatment in Molar Teeth

Yun-Seon Geum¹, Jang-Ryeol Lee², Hyeon-Cheol Kim¹,
Sang-Cheol Lee¹, Yeong-Uk Kim¹

1. Department of Oral and Maxillofacial Surgery, Livingwell Dental Hospital, Gyeonggi-do, Korea
2. Department of Oral and Maxillofacial Radiology, Livingwell Dental Hospital, Gyeonggi-do, Korea

Corresponding Author

Yun-Seon Geum, DDS

Livingwell Dental Hospital, 4F Hyowon Bldg., 110 Juyeop-dong, Ilsan Seo-gu, Goyang-si, Gyeonggi-do, Korea

TEL: +82-31-916-8020 FAX: +82-31-916-8029 E-mail: cake3131@nate.com

Received for publication Nov 4, 2010; returned after revision Nov 20, 2010;
Accepted for publication Nov 29, 2010

• Abstract

Despite the latest advancement made in its techniques and devices/apparatuses and the resulting rising expectation in the field of dental surgery, apicoectomy performed in the molar teeth remains a technical challenge and lacks evidence substantiated by long-term follow-up studies. This study sought to investigate the treatment outcomes and post-operative success rate in the root-end resected molar teeth accompanied by a high level of surgical risks due to their close proximity to the mandibular canal and maxillary sinus. A total of 68 patients who received treatment at Livingwell Dental Hospital between 2004 and 2010 and underwent apical surgery in the maxillary or mandibular molar area were enrolled in this study. A total of 160 roots collected from 75 molar teeth were subjected to surgical endodontic treatment and subsequently evaluated clinically as well as radiographically. Based on the results of the study, the clinical success rate was found to be 78.8% in cases involving radiological healing. Likewise, 90.7% of the roots recorded a robust clinical survival rate, but with incomplete healing as shown by radiography. The results indicate that the apical procedure involving molar teeth is a prognosis-friendly method that promises positive outcomes and higher success rate based on long-term follow-up observations.

• Key word : periapical surgery, molar tooth, maxillary sinus, inferior alveolar canal, cone-beam CT, prognosis

• J Kor Dent Sci. 2010; 3(2) : 12 – 19

Introduction

In clinical cases with apical lesion(s) that is(are) untreatable using the endodontic procedure, surgeons turn to periapical surgery as their last resort¹⁾.

Apicoectomy has been the subject of numerous long-term follow-up studies examining the outcomes of the treatment²⁻⁷⁾. Some of them reported a success rate of as low as 50% or even lower^{5,7)}, with others claiming an astonishing 90% success rate²⁾. The vastness of the

gap in the reported success rate is considered attributable to factors such as post-operative pathological findings and evaluation criteria^{6,8)}, observation period^{3,4)}, and surgical method^{6,7)}. So far the most frequently addressed theme of studies on apicoectomy has been the anterior teeth^{2,3,6,7)}.

The latest development in the methods of apicoectomy as well as in microsurgery, surgical instruments, and materials has allowed surgeons to expect even greater advancement in the field⁹⁻¹²⁾, yet apical surgery in the molar area remains a challenge. Limitations of the periapical operation done in the maxillary or mandibular molar area include: (a) close proximity to major anatomical structures such as the apical constriction, maxillary sinus, and mandibular canal; (b) difficulties in exposing and securing access to the molar teeth located farthest in the back, and; (c) relationships between the teeth and cortical bone thickness and bone quality¹³⁻²⁰⁾. In fact, the locational relationship between the mandibular canal and the lesion is a consideration that needs to be taken seriously. According to Wesson and Gale²¹⁾, about 20~21% of the patients who had received surgery in the lower molar area complained of post-operative sensory abnormalities in their lower lip during a period of time that varied greatly. Von Arx, et al¹⁸⁾ evaluated the outcome of apicoectomy performed in the molar area 1 year after the surgery, reporting an 88% success rate in the 25 teeth treated with super-EBA cement-based retrograde filling. Persson¹⁶⁾ reported a case wherein 31 periapical surgeries were performed on 18 maxillary molars. In the follow-up evaluation 1 year after the surgeries, a 78% radiological healing was reported. Friedman, et al²²⁾ reported a 50% clinical success rate in a periapical procedure performed on 12 upper molars followed by a post-operative progress follow-up that lasted between 6 months and 8 years. Similar success rates were found in a case by Loannides and Borstlap²³⁾ wherein 70 apical surgeries were done in the molar area and in a case by Franz, et al²⁴⁾ wherein 150 molar apicoectomy surgeries were performed.

Despite a number of previous studies on periapical surgery performed on molar teeth, there is insufficient information available on the therapeutic outcomes of such surgery as reported via longer-term follow-up monitoring. Therefore, this study sought to investigate the treatment outcomes of apicoectomy in the molar area, which poses higher risks during surgery owing to the area's close proximity to the mandibular canal and the maxillary sinus, as well as the success rate associated with the surgical outcomes.

2. Subjects and Methods

Study sample & data collection

This study enrolled 68 patients who visited Livingwell Dental Hospital between 2004 and 2010 and received apicoectomy on their maxillary or mandibular first and/or second molar. Out of a total of 75 teeth, 160 roots were treated with surgical endodontic regimen and subsequently evaluated clinically as well as radiographically. For the gender ratio, 35 patients were male and 33 were female. The patients represented various age cohorts that ranged between 16 and 72 (mean age of 40 yrs.), and they were monitored for a varying period of time from less than 6 months to longer than 60 months. In most cases, post-surgical pathological findings included clinical symptoms including post-treatment pain that persisted or abscess. Less frequent than these complaints but constituting the majority were the symptom-free apical lesions situated in close proximity to the anatomical structures as revealed by the radiological examinations²⁵⁾.

Treatment outcomes were categorized via clinical and radiological tests. In particular, three classifications were adopted as summarized below based on various literature reviews^{26,27)}.

- a) Success: Radiographic tests reveal bone healing taking place around the lesion(s) and no adverse clinical symptoms or indications (Fig. 1).
- b) Doubtful: The tests show no adverse clinical symptoms but reveal bone healing that appears radiographically incomplete or dubious, or percussion and/or palpation reveals clinical symptoms such as the patient's response to such examinations despite a certain extent of healing occurring as shown radiographically (Fig. 2).
- c) Failure: Radiographic tests show that the lesion(s) has(have) not healed but has(have) even increased. In addition, clinical symptoms are noted, such as response to percussion/palpation, swelling, fistula, and dental mobility, thereby necessitating tooth extraction (Fig. 3).

Post-surgical clinical symptoms were defined as a group of symptoms including pain sensations felt by the patient following dental palpation and/or palpation of the gingiva or the vestibular area, swelling in the operated site, presence of fistula, and other symptoms experienced by the patient. With a multi-rooted tooth, any and all clinical symptoms reported by the patient were recorded as affecting all of the

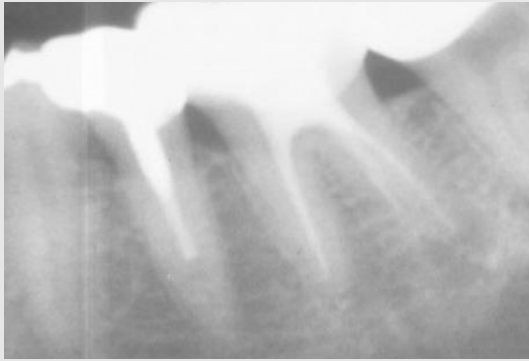


Fig. 1-1. Success case: pre-op periapical view.

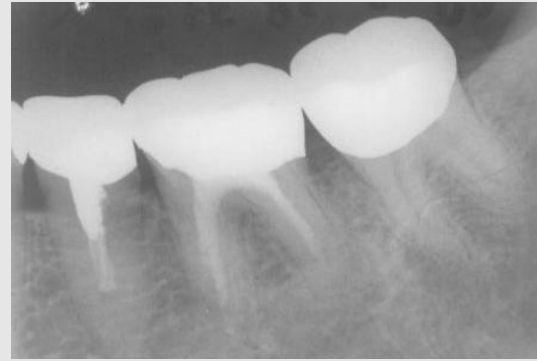

Fig. 1-2. Success case: post-op periapical view.

Yun-Seon Geum et al : Success and Failure of Surgical Endodontic Treatment in Molar Teeth . J Kor Dent Sci 2010.

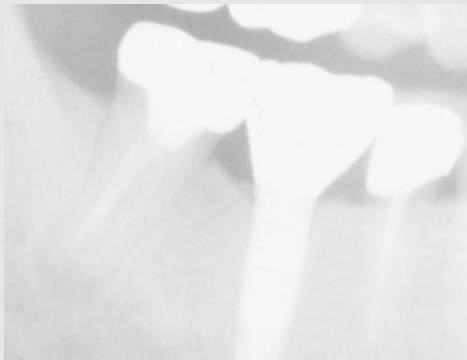


Fig. 2-1. Doubtful case: pre-op periapical view.

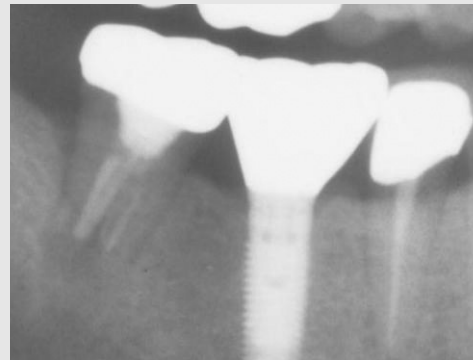


Fig. 2-2. Doubtful case: post-op periapical view.

Yun-Seon Geum et al : Success and Failure of Surgical Endodontic Treatment in Molar Teeth . J Kor Dent Sci 2010.

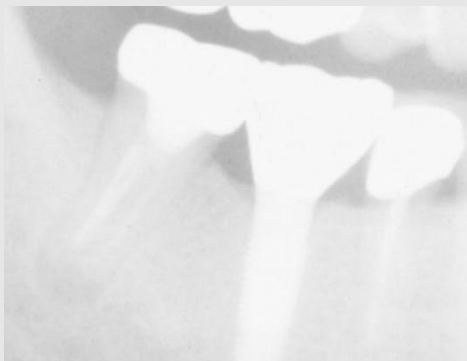


Fig. 3-1. Failure case: pre-op periapical view.

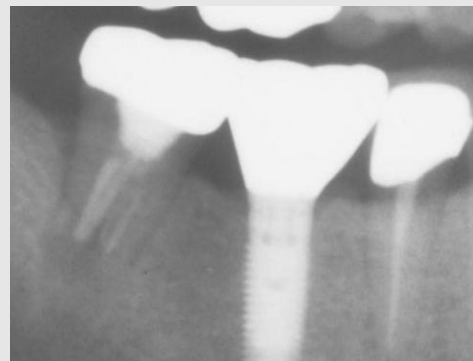


Fig. 3-2. Failure case: post-op periapical view.

Yun-Seon Geum et al : Success and Failure of Surgical Endodontic Treatment in Molar Teeth . J Kor Dent Sci 2010.

roots of the tooth concerned. Radiographic tests were carried out prior to the surgery, on the day immediately following the day of the surgery, and 6 months after the surgery as well as routinely throughout the monitoring

period. Radiography was routinely used for periapical examinations within the oral cavity. Orthopantomography and pre-operative CT scanning were also utilized for the examinations.

Surgical procedure

All surgeries were performed by a single surgeon and under local anesthesia using lidocaine 2% with epinephrine 1:100,000. Gingival incision in most cases was performed as semilunar incision. Open flap debridement was also carried out, followed by osseous resection and root-end amputation done under saline solution injection and using low-speed handpieces or piezoelectric surgical kit, round bur, or Er:YAG lasers. Retrograde filling was not performed unless judged to be absolutely necessary for incomplete endodontic treatment cases. When filling was actually performed, IRM was used as filling material. In cases wherein the patients' radicular cyst was too big and the resulting bone loss is severe, autogenous bone grafting was performed using grafts harvested from the mandibular ramus. Following the surgery, all patients were given Amoxicillin (250 mg every 8 hours) and Talmiflumate (370 mg every 8 hours) orally for 3 days. In addition, the patients were post-surgically instructed to maintain good oral hygiene and to avoid drinking and smoking.

3. Results

Out of the 160 roots treated, 126 (78.8%) were found to be successful, 19 (11.9%), doubtful, and 15 (9.3%), failure.

Tables 1 ~ 4 compared the success rates across factors such as patients' gender and age, monitoring period, and dental formula. An equal number of roots were treated in male vs. female patients, with the success rates of 77.5% in males and 80% in females showing no significant differences (Table 1). Age-based classification revealed no statistically significant success rates across the cohorts, either. The rate was found to be highest in the cohort in their 40s (89.2%) and the lowest among patients in their 50s or older (72%) (Table 2). Regarding the classification based on tooth type, the maxillary first molar showed an undeniably high success rate of 92.7%, with no cases of "failure." In contrast, the maxillary second molar had a success rate of 70% - the lowest among the 4 tooth types - and a failure rate of 20% as the highest among the tooth types. On the other hand, the mandibular first molar exhibited a slightly lower success rate than the mandibular second molar, but the difference

Table 1. Success rates by patient gender

Gender	Number of roots	Fail (%)	Doubtful (%)	Success (%)
Male	80	7.5	15	77.5
Female	80	11.25	8.75	80

Yun-Seon Geum et al : Success and Failure of Surgical Endodontic Treatment in Molar Teeth . J Kor Dent Sci 2010.

Table 2. Success rates by patient age

Age	Number of roots	Fail (%)	Doubtful (%)	Success (%)
13<y<30	37	13.5	8.1	78.4
30<y<40	48	10.4	16.7	72.9
40<y<50	37	0	10.8	89.2
50<y	36	13.9	11.1	75

Yun-Seon Geum et al : Success and Failure of Surgical Endodontic Treatment in Molar Teeth . J Kor Dent Sci 2010.

Table 3. Success rates by tooth type

Tooth	Number of roots	Fail (%)	Doubtful (%)	Success (%)
Upper 1st molar	41	0	7.3	92.7
Upper 2nd molar	30	20	10	70
Lower 1st molar	50	14	14	72
Lower 2nd molar	39	5.1	15.4	79.5

Yun-Seon Geum et al : Success and Failure of Surgical Endodontic Treatment in Molar Teeth . J Kor Dent Sci 2010.

Table 4. Success rates by monitoring period

Period of observation (month)	Number of roots	Fail (%)	Doubtful (%)	Success (%)
P<6	11	27.3	0	72.7
6<P<12	51	3.9	19.6	76.5
12<P<24	39	10.3	0	89.7
24<P<36	41	14.6	2.4	82.9
36<P<48	11	0	36.4	63.6
48<P<60	23	0	17.4	82.6
60<P	3	0	0	100

Yun-Seon Geum et al : Success and Failure of Surgical Endodontic Treatment in Molar Teeth . J Kor Dent Sci 2010.

was not statistically significant (Table 3). As for the monitoring period, the failure rate was found to be highest in the cohort observed for less than 6 months, possibly due to the recurrence of the problem in the operated site, post-operative wound infection, and insufficient healing. In terms of the success rate, the cohorts exhibited no significant inter-group differences. Lastly, the failure rate showed a tendency to decrease over time, with no case of failure identified in 3 years as shown in the statistics (Table 4).

4. Discussion

A few recent studies have conducted observation of the progress after the apicoectomy performed in the maxillary or mandibular molar area and have reported the success rate thereafter. With maxillary molars, Gay, et al²⁸⁾ reported a case study wherein 72 molar teeth (including 24 maxillary molars) were subjected to periapical surgery and a year-long follow-up observation during which 77.8% of the teeth showed complete healing. Testori, et al²⁹⁾ reported a mean of 4.6 years follow-up study conducted on 62 maxillary tooth roots. During the monitoring period, 69% of the roots exhibited complete healing as verified via radiography. In addition, Zuolo, et al³⁰⁾ examined 20 upper molars for a one-year period and reported complete recovery in 85% of the teeth. According to von Arx, et al¹⁸⁾, 15 maxillary apical lesions (9 molars) were treated with apicoectomy and monitored for 1 year. The success rate was found to be 88%, showing radiographically complete healing and no clinical indications or symptoms. Likewise, in their study of 50 upper molars, Peñarrocha, et al¹¹⁾ reported 46 teeth that showed recovery as substantiated by radiography and 4 teeth that showed no recovery.

Root-end resection performed in the mandibular molar area

is carried out as a common surgical procedure under specific prevention measures and conditions. Rud, et al³¹⁾ conducted apical surgery on 834 mandibular roots and monitored the progress for 6 months ~ 12.5 years into post-operative recovery. Complete healing was reported in 92% of the 834 roots, uncertain healing, in 1% of the roots, and failure, in 7% of the roots. Likewise, von Arx, et al¹⁸⁾ evaluated 16 lower molars and recorded a success rate of 94%. Peñarrocha, et al¹¹⁾ reported a case wherein apicoectomy was performed in the lower molar area, with 54.8% of the teeth treated showing radiographically confirmed healing and 90.45% tooth survival found clinically.

According to related research findings both old and new, microapical surgery using a microscope has helped increase the success rate of apical procedure. However, the technique is being used in limited capacity only due to difficulties in securing access to molar teeth and in implementing the technique in actual clinical settings. Thus, the more conventional surgical endodontic procedure is still in use at many dental clinics/hospitals. Similarly, resorting to this conventional technique, this study examined apical surgery performed on the upper molar and the resulting clinical success rate of 78.8% with healing substantiated radiographically. Although the radiographic tests failed to show the indications of complete healing in the molar area, the mean clinical survival rate of the teeth was an encouraging 90.7%.

The related studies summarized above are characterized by a vast degree of varying success rates deemed to have resulted from the differences in the surgical process, diversity in the patients' lesions, and varying criteria for defining what "success" constitutes. Mikkonen, et al⁴⁾ categorized and used the criteria for defining post-apical operative healing as follows: (a) clinical success, which refers to painless and swelling-and-fistula-free state; (b)

uncertain healing, a state that includes radiographic observations of bone loss but no clinical symptoms, and; (c) failure as a state accompanying root resorption or bone loss as well as other clinical symptoms. Rud and Andreasen³²⁾ proposed a radiographic criterion that defines the lesion based on three different classifications. Von Arx and Kurt²⁷⁾ came up with their own criteria to evaluate the overall extent of healing and treatment success. The criteria they used in evaluating the surgical outcomes consist of the following: (a) success, which shows a minimum of 90% bone regeneration and the patient-rated pain rating of “0”; (b) improvement, with bone generation of 50% ~ 90% and pain rating of “0,” and; (c) failure wherein bone generation is measured at or under 50% and pain rating is “1” or higher. What these researchers had in common was their approach to establishing clinical criteria by allowing the rating to increase according to the number of repeated pain and swelling occurrences. In this study, the researchers reviewed and combined various evaluation methods reported in literature and came up with the success rate-defining criteria based on clinical and radiographic examinations: success, doubtful, and fail.

In examining and determining the treatment success of periapical surgery, the period of follow-up study - which could affect the success rate - appears to vary widely in previous studies. According to the 2005 report by Friedman³³⁾, a year-long post-operative monitoring period was found to suffice in most cases for determining the success-failure status of the treatment except for a few cases wherein healing was continuing in the damaged area. Considering Friedman’s finding, this study recorded a success rate of 74.3% based on a monitoring period of less than 1 year. The rate is somewhat low compared to the overall success rate, indicating that the failure rate of the surgery will most likely be determined - at least to a certain degree - within a 1-year period following surgery. In addition, some researchers confirmed the previous finding of complete bone regeneration as verified via radiography harder to expect with bigger apical lesions. This is self-explanatory since larger lesions per se will naturally take more time to heal. The finding was reconfirmed by von Arx, et al³⁴⁾, who reported that the smaller the lesion is, the better the prognosis.

One of the most common reasons apicoectomy in the molar area has been considered to be limited clinically is the tooth’s close proximity to some of the critical anatomical

structures in the oral cavity and the resulting risks during surgery. The problem has driven many researchers to examine and investigate the relationship between the maxillary molar and the maxillary sinus and that between the mandibular molar and the mandibular canal as well as the post-surgical success rate in relation to the proximity. Garcia, et al³⁵⁾ reported that the post-operative recurrence rate was found to be lower in the cohort that had closer proximity to the maxillary sinus. Although the rate showed no statistically significant difference, better prognosis was noted. Their finding indicates that a case wherein the maxillary sinus and apical constriction are located closely to each other does not qualify for the contraindications in apical surgery done on the upper molar area. Furthermore, Marti, et al³⁶⁾ reported that close proximity between the mandibular canal and the lesion in apical surgery involving the lower molar did not affect post-operative symptoms or prognosis in any significant manner. Thus, the proximity issue, as they argued, did not constitute an absolutely necessary consideration to be made during implant adjustment.

More recently, CT scans have been found to be of tremendous help in dental surgeons’ precision diagnosis and surgical treatment involving molar teeth. Cotti, et al³⁷⁾ mentioned the usefulness of computed tomography (CT) in establishing treatment plans and implementing differential diagnosis aimed at monitoring the progress of apical lesions. In this study, pre-operative CT scanning was carried out to ensure accurate diagnostic tests of the locational relationship between the molar and its surrounding anatomical structures, size and location of the apical lesion, and root resorption. In addition, easier access to the surgical site and minimum osseous resection were ensured during the surgery. Velvart, et al³⁸⁾ published the results of their comparison of conventional intra-oral apical radiographic images and CT scans of the apical lesions that were monitored after the root-end resection procedure performed on the lower molar of 50 patients. All of the previously diagnosed 78 lesions were verified via CT scanning, with only 61 lesions shown clearly on the intra-oral radiographic images. Moreover, in all of the 78 cases, CT examinations delivered clear images of the mandibular canal, whereas the radiography showed such images in 31 cases only. All of the teeth examined in this study were subjected to treatment plans that included pre-surgical CT scanning. Likewise, no sensory abnormalities

were reported in the lower lip following the surgery in this study, which was cited by Wesson and Gale as a possible adverse event.

5. Conclusions

Root-end resection has been used by dental clinicians for quite some time. Despite its long history, however, the procedure has been reported relatively rarely in applications involving the molar teeth owing to a number of limitations found in the technique. Such has been the case so far in clinical settings as well as in research endeavors. Nowadays, however, the limitations are being overcome via various

newer diagnostic and treatment methods and advanced surgical instruments and apparatuses. According to the results of this study and other latest research findings, the apical procedure done in the molar area is considered a prognosis-friendly technique producing positive outcomes in terms of prognosis and success rate as evidenced by long-term follow-up observations. Apical surgery can be a particularly effective, stable treatment method when used for cases wherein apical lesion(s) is(are) present in the molar area, causing clinical symptoms and/or progressive radicular cyst. In such cases, surgeons are advised to perform apicoectomy first before extracting the tooth to ensure greater treatment effects.

References

1. Freedman A, Horowitz I. Complications after apicoectomy in maxillary premolar and molar teeth. *Int J Oral Maxillofac Surg.* 1999;28:192.
2. Harry FJ, Parkins BJ, Wengraf AM. The success rate of apicectomy: a retrospective study of 1,016 cases. *Br Dent J.* 1970;129:407-13.
3. Rud J, Andreasen JO, Jensen JEM. A follow-up study of 1,000 cases treated by endodontic surgery. *Int J Oral Surg.* 1972;1:215-28.
4. Mikkonen M, Kullaa-Mikkonen A, Kotilainen R. Clinical and radiologic reexamination of apicoectomized teeth. *Oral Surg.* 1983;55:302-6.
5. Persson G, Lennartson B, Lundstrom I. Results of retrograde root-filling with special reference to amalgam and cavit as root-filling materials. *Svensk. Tandlak Tidsskr.* 1974;68:123-33.
6. Nordenram A, Svardstrom G. Results of apicectomy: a clinical-radiological examination. *Svensk. Tandlak Tidsskr.* 1970;63:593-604.
7. Hirsch JM, Ahlstrom U, Henrikson PA, Heyden G, Peterson, LE. Periapical surgery. *Int J Oral Surg.* 1979;8:173-85.
8. Mattila K, Altonen M. A clinical and roentgenological study of apicoectomized teeth. *Odontol. Tidsskr.* 1968;76:389-407.
9. von Arx T. Frequency and type of canal isthmuses in first molars detected by endoscopic inspection during periradicular surgery. *Int Endod J.* 2005;38:160.
10. von Arx T, Walker W. Microsurgical instruments for root-end cavity preparation following apicoectomy: a literature review. *Endod Dent Traumatol.* 2000;16:47-62.
11. Peñarrocha M, Sanchis JM, Gay C. Cirugía periapical con técnica de ultrasonidos y relleno con amalgama de plata: a propósito de 122 casos. *Rev Eur Odont Estomatol.* 2001;13:181-8.
12. Peñarrocha M, Sanchis JM, Gay C. Periapical surgery of 31 lower molars based on the ultrasound technique and retrograde filling with silver amalgam. *Med Oral* 2001;6:376-82.
13. Littner MM, Kaffe I, Tamse A, et al. Relationship between the apices of the lower molars and mandibular canal – a radiographic study. *Oral Surg Oral Med Oral Pathol.* 1986;62:595.
14. Rud J, Rud V, Munksgaard EC. Periapical healing of mandibular molars after root-end sealing with dentine-bonded composite. *Int Endod J.* 2001;34:285.
15. Altonen M. Transantral subperiosteal resection of the palatal root of maxillary molars. *Int J Oral Surg.* 1975;4:277.
16. Persson G. Periapical surgery of molars. *Int J Oral Surg.* 1982;11:96.
17. Wallace JA. Transantral endodontic surgery. *Oral Surg Oral Med Oral Pathol.* 1996;82:80.
18. von Arx T, Gerber C, Hardt N. Periradicular surgery of molars: a prospective clinical study with a one-year follow-up. *Int J Endod.* 2001;34:520.
19. Garcia B, Martorell L, Marti E, et al. Periapical surgery of maxillary posterior teeth: a review of the literature. *Med Oral Pathol Oral Cir Buccal.* 2006;11:E146.
20. Oberli K, Bornstein MM, von Arx T. Periapical surgery and the maxillary sinus: radiographic parameters for clinical outcome. *Oral Surg. Oral Med Oral Pathol Oral Radiol Endod.* 2007;103:848.
21. Wesson CM, Gale TM. Molar apicectomy with amalgam rootend filling: results of a prospective study in two district general hospitals. *Br Dent J.* 2003;195:707.
22. Friedman S, Lustmann J, Shaharabany V. Treatment results of apical surgery in premolar and molar teeth. *J Endod.* 1991;17:30.
23. Ioannides C, Borstlap WA. Apicoectomy on molars: a clinical and radiographical study. *Int J Oral Surg.* 1983;12:73-9.
24. Franz M, Bethke K, Bier J. Wurzelspitzenamputation an 150 molaren des oberund unterkiefers. *Dtsch Zahnarztl Z.* 1987;42:287-9.
25. Peñarrocha M. Protocolo en cirugía endodóntica. *Sociedad Española de Cirugía Bucal.* 2004;61.

References

26. Rud J, Andreasen JO, Jensen JEM. Radiographic criteria for the assessment of healing after endodontic surgery. *Int J Oral Surg.* 1972;1:195-214.
27. von Arx T, Kurt B. Root-end cavity preparation after apicoectomy using a new type of sonic and diamond-surfaced retrotip: a 1-year follow-up study. *J Oral Maxillofac Surg.* 1999;57:656.
28. Gay C, Paredes J, Berini L. La cirugía periapical en los molares. *Rev Eur Odont Estomatol.* 1993;2:95-102.
29. Testori T, Capelli M, Milani S, et al. Success and failure in periradicular surgery: a longitudinal retrospective analysis. *Oral Surg Oral Med Oral Pathol.* 1999;87:493.
30. Zuolo M, Ferreira M, Gutmann J. Prognosis in periradicular surgery: a clinical prospective study. *Int Endod J.* 2000;33:91.
31. Rud J, Rud V, Munksgaard EC. Periapical healing of mandibular molars after root-end sealing with dentine-bonded composite. *Int Endod J.* 2001;34:285.
32. Rud J, Andreasen JO. A study of failures after endodontic surgery by radiographic, histological, and stereomicroscopic methods. *Int J Oral Surg.* 1972;1:311-28.
33. Friedman S. The prognosis and expected outcome of apical surgery. *Endod Topics.* 2005;11:219.
34. von Arx T, Jensen SS, Hanni S. Clinical and radiographic assessment of various predictors for healing outcome 1 year after periapical surgery. *J Endod.* 2007;33:123.
35. Garcia, et al. Periapical surgery in maxillary premolars and molars. *J Oral Maxillofac Surg.* 2008;66(6):1212-7.
36. Marti E, et al. Distance between periapical lesion and mandibular canal as a factor in periapical surgery in mandibular molars. *J Oral Maxillofac Surg.* 2008;66(12):241-6.
37. Cotti E, Vargiu P, Dettori C, Mallarini G. Computed tomography in the management and follow-up of extensive periapical lesion. *Endod. Dent. Traumatol.* 1999;15:186-9.
38. Velvart P, Hecker H, Tillinger G. Detection of the apical lesion and the mandibular canal in conventional radiography and computed tomography. *Oral Surg Oral Med Oral Pathol.* 2001;92:682-8.