

## Clinical Article

# Comparison of the Results of Balloon Kyphoplasty Performed at Different Times after Injury

Gun Soek Oh, M.D.,<sup>1</sup> Hyeun Sung Kim, M.D., Ph.D.,<sup>2</sup> Chang IL Ju, M.D.,<sup>1</sup> Seok Won Kim, M.D., Ph.D.,<sup>1</sup> Seung Myung Lee, M.D., Ph.D.,<sup>1</sup> Ho Shin, M.D., Ph.D.<sup>1</sup>

Department of Neurosurgery,<sup>1</sup> College of Medicine, Chosun University, Gwangju, Korea

Department of Neurosurgery,<sup>2</sup> Heori Sarang Hospital, Daejeon, Korea

**Objective** : Balloon kyphoplasty is a minimally invasive procedure that is mainly performed for refractory pain due to osteoporotic compression fractures. The purpose of this study was to evaluate the results of balloon kyphoplasty performed at different times after an injury.

**Methods** : In this retrospective study, the records of 99 patients who underwent one level of balloon kyphoplasty between January 2005 and December 2007 were reviewed. The patients were divided into three groups : 21 patients treated within 3 weeks of an injury (the acute group), 49 treated within 3 weeks to 2 months of an injury (the subacute group), and 29 patients treated at more than 2 months after an injury (the chronic group). Clinical outcomes were assessed using a visual analogue scale (VAS). In addition, modified MacNab's grading criteria was used to assess the subjective patient outcome. The radiology findings, including vertebral height restoration and procedure related complications, were analyzed based on the different time intervals after the injury.

**Results** : Patients in all three groups achieved marked pain relief in terms of the VAS within 7 days of the procedure. Good or excellent results were achieved by most patients in all three groups. However, the height restoration, the main advantage to performing a balloon kyphoplasty, was not achieved in the chronic group. Moreover, evidence of complications including cement leakage was observed significantly less frequently in the subacute group compared to the other two groups.

**Conclusion** : Although balloon kyphoplasty is an effective treatment for osteoporotic compression fractures, with regard to pain relief, the subacute stage appears to be optimal for treating patients with a balloon kyphoplasty in terms of achieving the best outcomes with minimal complications.

**KEY WORDS** : Balloon kyphoplasty · Osteoporosis · Compression fracture.

## INTRODUCTION

Compression fractures due to osteoporosis are common in the elderly and are a common problem encountered by spine surgeons<sup>1)</sup>. Percutaneous vertebroplasty and balloon kyphoplasty have been widely used to treat painful osteoporosis associated compression fractures for many years, and various means of reducing complications have been discussed<sup>4,7)</sup>. Furthermore, balloon kyphoplasty is now being touted as a technique that allows for the reduction of sagittal alignment of the spine with the use of inflatable

percutaneous balloon tamps. Height restoration and reduced cement leakage are important features of the balloon kyphoplasty and differentiate this technique from the percutaneous vertebroplasty. Despite the advantages of balloon kyphoplasty, there are procedure related complications including extravasation of bone cement, pulmonary embolism and adjacent compression fractures that are a concern to the surgeon. The optimal timing for performing a balloon kyphoplasty has not been adequately studied. Accordingly, the purpose of this study was to compare the clinical outcome of balloon kyphoplasty done at different time intervals after an injury and the frequency of postoperative complications.

## MATERIALS AND METHODS

From January 2005 to December 2007, 99 patients with a single level osteoporotic compression fracture who under-

• Received : December 22, 2009 • Revised : February 9, 2010  
 • Accepted : February 25, 2010  
 • Address for reprints : Seok Won Kim, M.D., Ph.D.  
 Department of Neurosurgery, College of Medicine, Chosun University,  
 588 Seoseok-dong, Dong-gu, Gwangju 501-717, Korea  
 Tel : +82-62-220-3126, Fax : +82-62-227-4575  
 E-mail : ns64902@hanmail.net

went balloon kyphoplasty at our institution were included in this study. Indications for the balloon kyphoplasty were local pain, major vertebral body deformity, or increasing deformity by radiographs with radiologic signs of osteoporosis, and current fracture activity identified by magnetic resonance imaging. The following patients were excluded : those with multiple level compression fractures, absence of an obvious traumatic event, suspected of having spinal metastasis, with a neurological compression syndrome due to the dislocation of bony fragments, and those who could not be monitored. The 99 patients were divided into three groups by the time interval between injury and the date of the balloon kyphoplasty : in the acute-stage group (n = 21), patients were treated within 3 weeks of an injury; in the subacute stage group (n = 49), treatment was provided 3 weeks to 2 months after injury, and in the chronic-stage group (n = 29), patients received treatment more than 2 months after the injury.

All enrolled patients had dual-energy X-ray absorptiometry (DEXA) bone mineral density testing and magnetic resonance imaging. All had severe osteoporosis, a T-score < -3.0, and a single level osteoporotic compression fracture. All procedures were performed by the same surgeon. The mean follow-up period was 13 months (range 8-15 months). Clinical outcomes were assessed using a visual analogue scale (VAS). The effects of the procedure were analyzed preoperatively, 7 days postoperatively, and at the final follow-up. In addition, modified MacNab's criteria were used to assess the surgical outcome at the last follow-up. Radiological findings including height restoration, bone cement extravasation and other systemic complications were analyzed by the time interval between the injury and the date of intervention. The extent of vertebral body collapse was determined using the vertebral heights at the point of maxi-

mal collapse on lateral radiographs or on midsagittal magnetic resonance (MR) images. The vertebral heights were reported as fractions of the referenced height. Computed tomographic scans were obtained at the treatment level, using a 1.25 mm section thickness and 0.6 mm overlap to evaluate cement leakage after the procedure. The characteristics of the patients are summarized in Table 1. The three groups were compared for age, gender, mean T-score, affected vertebral body level, preoperative degree of pain, and vertebral height. All data presented in the tables are median values. The preoperative group differences were evaluated using the Student's t-test for unpaired data. Intra-group changes associated with the procedure were evaluated using the Student's t-test for paired data. *p* values of < 0.05 were considered significant.

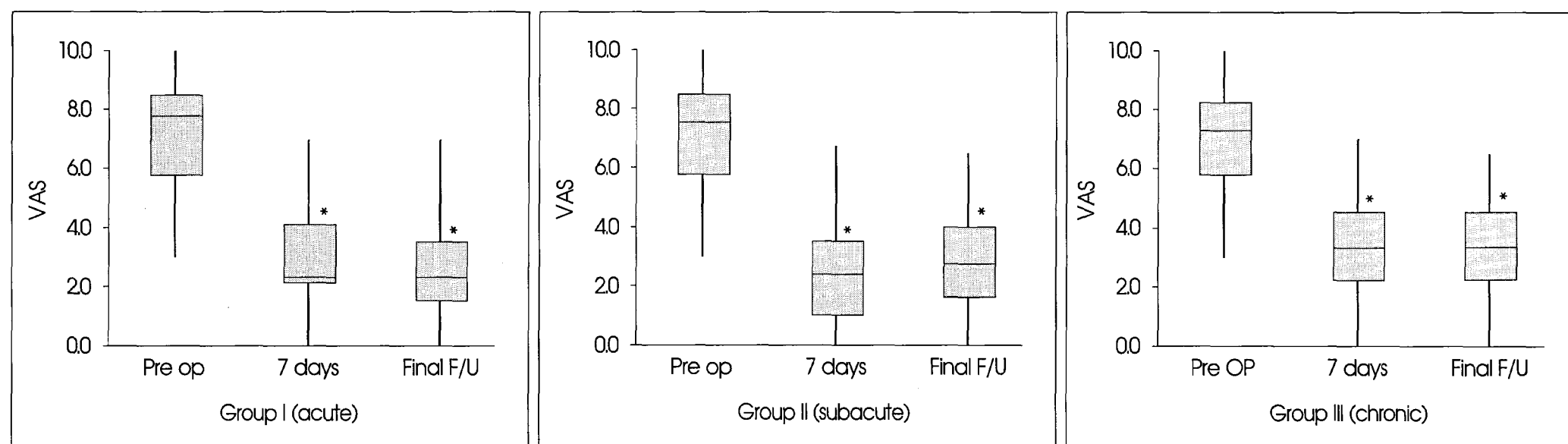
## RESULTS

The bipedicular approach under local anesthesia was used in all patients. The patient demographics, including age, gender (female predominance), pain, vertebral height, mean T-score, and fracture level were not significantly different (Table 1). Significant pain relief was achieved in all three groups (*p* < 0.01). For the acute stage group, the mean VAS scores were 7.8 before surgery, 2.5 on the 7th day after surgery, and 2.3 at the last follow-up visit. For the subacute stage group, the mean VAS was 7.6 before surgery, 2.7 on

**Table 1.** Basic characteristics of patients before balloon kyphoplasty

	Group I (acute), n = 21	Group II (subacute), n = 49	Group III (chronic), n = 29	Significance
Mean age (years)	62.3	65.4	66.9	NS
Male : Female	8 : 13	10 : 39	7 : 22	NS
Mean T-score on BMD	-3.49	-3.67	-3.80	NS
Fractured level (T11-L2) (thoraco-lumbar region)	17 (80%)	39 (79%)	22 (76%)	NS
Visual analogue scale	7.8 (5.0-8.8)	7.6 (5.6-8.2)	7.1 (4.5-8.2)	NS
Vertebral height (%)	69 (62-75)	66 (50-80)	65 (50-72)	NS

Evaluation of differences shows similar epidemiologic data. NS : non-specific



**Fig. 1.** Visual analogue scale (VAS) after balloon kyphoplasty according to time. \**p* < 0.01 compared to preoperative VAS.

the 7th day after surgery, and 2.8 at the final follow-up visit, and in the chronic stage group, the mean VAS was 7.1 before surgery, 3.0 on the 7th day after surgery, and 3.0 at the final follow-up visit (Fig. 1). Most patients achieved favorable outcomes (good or excellent) in all three groups according to Macnab's criteria (Table 2). However, the subacute-stage patients showed lower complication rates after the procedure than the acute and chronic stage patients (Table 3). The inter-group pairwise comparison of the complications revealed no significant difference between the acute and chronic stage groups ( $p = 0.079$ ); however, there was a significant difference between the subacute and the acute/chronic groups ( $p = 0.012$ ). The radiology complications included cement leakage into the adjacent disc, paravertebral soft tissue, and epidural extravasation. After the balloon kyphoplasty, the vertebral height increased significantly in the acute and subacute groups; however, the chronic stage group showed no significant vertebral height restoration (Table 4). In the acute group, one female patient developed a symptomatic cement extravasation into the posterior spinal canal that was treated by posterior decompression and cement removal. One female patient in the chronic group had a serious pyogenic spondylitis 4 weeks after the procedure; this patient underwent a posterior fusion to relieve intolerable pain due to an aggravated kyphosis after the infection resolved. Within the first 6 months after surgery, another fracture occurred at 7 adjacent levels (acute group 2, subacute group 3, and chronic group 2<sup>3</sup>). These fractures were also treated by cement augmentation with a vertebroplasty or kyphoplasty. However, no major complications, such as respiratory complications related to pulmonary embolism, or fat embolism, were encountered in any of the groups.

**Table 2.** Satisfactory results after balloon kyphoplasty by injury stage

	Patients no.	Good and excellent results	
		7 days Postop	Final follow up
		no. (%)	no. (%)
Acute	21	18 (86)	20 (95)
Subacute	49	43 (88)	47 (96)
Chronic	29	23 (80)	24 (83)
Total	99	84 (85)	91 (92)

**Table 3.** Evaluation of complications by injury stage

	Patients (n = 99)	Cement leakage			Adjacent vertebral fracture	Infection	Total (%)
		Paraspinal	Endplate (adjacent disc)	posterior spinal canal			
		Acute	21	5			
Subacute	49	2	2	0	3	0	7 (14)*
Chronic	29	3	3	0	2	1	9 (31)

\*Significant difference between the subacute and the acute/chronic groups ( $p = 0.012$ )

## DISCUSSION

Osteoporotic vertebral compression fractures often occur after low-velocity trauma, weight lifting, or even in the absence of a significant traumatic event. Balloon kyphoplasty has been widely used to treat osteoporotic compression fractures, and provides rapid pain relief in the majority of patients. The use of inflatable bone tamps (IBT) has aided kyphoplasty procedures in restoring the vertebral height and reducing cement extravasation rates<sup>3,10</sup>. Although the procedure is a minimally-invasive, percutaneous technique, the cement augmentation procedure itself is associated with intra- and postoperative complications<sup>2,11</sup>. The optimal timing of balloon kyphoplasty with regard to an injury has not been determined. In patients with relatively minor degrees of acute vertebral collapse, we provide conservative treatment initially and obtain serial radiographs. If progressive collapse of the vertebral body is evident, balloon kyphoplasty is recommended. However, if the patient presents with advanced kyphosis after a compression fracture, immediate kyphoplasty is considered to improve the sagittal alignment. We have observed that thoracolumbar junction fractures (rather than fractures in thoracic or lumbar regions) and fractures that occur in the vertebra with extremely low bone mineral density are predisposed to progressive collapse and deformity, and thus, earlier kyphoplasty may be warranted in such cases. With regard to pain, the findings of this study demonstrate that balloon kyphoplasty for painful acute osteoporotic compression fractures can effectively treat the pain regardless of the time interval after an injury. Pain reduction was observed within 7 days of the procedure in all groups. This prompt relief of pain was associated with vertebral body stabilization, and was maintained at the final

follow-up visit. Furthermore, the long-lasting effects of balloon kyphoplasty on pain might be attributed to an improved sagittal profile of the spine, which reduces the compensatory activities of muscles, and promotes natural fracture healing<sup>6</sup>.

The main advantage of balloon

**Table 4.** Changes of vertebral height by injury stage

	Preoperative	Final follow-up	Significance
Acute	0.70 ± 0.06	0.86 ± 0.05	p = 0.012*
Subacute	0.66 ± 0.14	0.85 ± 0.05	p = 0.007*
Chronic	0.65 ± 0.07	0.68 ± 0.08	p = 0.102

\*p values are given for significant changes with preoperative values

kyphoplasty is that it reduces cement extravasation because of the space created by the balloon tamps. In our study, the rate of cement leakage was lower in the subacute group. This difference may indicate that fracture sites may be more susceptible to cement leakage during the acute stage after an injury. During the acute stage, even with the balloon tamps, cracks in the cortex increased the risk of cement leakage. Therefore, when the procedure is performed during the acute stage, cracks in the cortex are more likely to cause cement leakage. Whereas partial or fibrous unions might be indicated and become more evident during the subacute stage, as demonstrated by MRI, healing has commenced, which makes this stage more suitable for injecting bone cement in terms of reducing leakage. On the other hand, when balloon kyphoplasty is performed during the chronic stage, the restoration of vertebral body height is difficult to achieve by bone tamp inflation because the healing process has progressed to bone union and it was difficult to inject bone cement by low pressure at this stage. Some articles have reported on venography before bone cement injection, during vertebroplasty or kyphoplasty; many spine surgeons think that these findings cannot be used to predict cement leakage accurately because the density of the dye differs from that of the cement<sup>3</sup>). We terminate the procedure as soon as leakage is observed into the disc, paravertebral tissue, or epidural space.

In the present study, adjacent level fractures occurred in 7 levels. These fractures were thought to be attributable to osteoporotic progression and the enhanced stiffness of the stabilized vertebral body<sup>8,9</sup>). The present study was undertaken to determine the optimal timing of balloon kyphoplasty. Patients in all three study groups achieved significant pain relief. However, the findings show that the procedure is best performed during the subacute stage because it allows height restoration and causes fewer complications.

## CONCLUSION

Although balloon kyphoplasty was an effective treatment for osteoporotic compression fractures at all stages after injury, the subacute stage appears to be the optimal time for balloon kyphoplasty with regard to achieving the best outcomes and fewer complications.

### • Acknowledgements

This work was supported by research grant from the Chosun University Hospital in 2008.

### References

1. Amar AP, Larsen DW, Esnaashari N, Albuquerque FC, Lavine SD, Teitelbaum GP : Percutaneous transpedicular polymethylmethacrylate vertebroplasty for the treatment of spinal compression fractures. *Neurosurgery* 49 : 1105-1114, 2001
2. Becker S, Meissner J, Tuschel A, Chavanne A, Ogon M : Cement leakage into the posterior spinal canal during balloon kyphoplasty: a case report. *J Orthop Surg (Hong Kong)* 15 : 222-225, 2007
3. Gailloud P, Vasconelos C, Martin J : Percutaneous vertebroplasty for osteoporotic compression fractures without pretreatment venogram : evaluation of 112 consecutive cases. *Am J Neurodiol* 278 : 23-27, 2001
4. Garfin SR, Yuan HA, Reiley MA : New technologies in spine : kyphoplasty and vertebroplasty for the treatment of painful osteoporotic compression fractures. *Spine (Phila Pa 1976)* 26 : 1511-1515, 2001
5. Ledlie JT, Renfro M : Balloon kyphoplasty : one-year outcomes in vertebral body height restoration, chronic pain, and activity levels. *J Neurosurg (1 Suppl)* 98 : 36-42, 2003
6. Lee JH, Kwon JK, Kim YB, Suk JS : Segmental deformity correction after balloon kyphoplasty in the osteoporotic vertebral compression fracture. *J Korean Neurosurg Soc* 42 : 371-376, 2007
7. Lieberman IH, Dudeney S, Reinhardt MK, Bell G : Initial outcome and efficacy of "kyphoplasty" in the treatment of painful osteoporotic vertebral compression fractures. *Spine (Phila Pa 1976)* 26 : 1631-1638, 2001
8. Melton LJ 3rd, Atkinson EJ, Cooper C, O'Fallon WM, Riggs BL : Vertebral fractures predict subsequent fractures. *Osteoporos Int* 10 : 214-221, 1999
9. Uppin AA, Hirsch JA, Centenera LV, Pfeifer BA, Pazianos AG, Choi IS : Occurrence of new vertebral body fracture after percutaneous vertebroplasty in patients with osteoporosis. *Radiology* 226 : 119-124, 2003
10. Voggenteiter G : Balloon kyphoplasty is effective in deformity correction of osteoporotic vertebral compression fractures. *Spine (Phila Pa 1976)* 30 : 2806-2812, 2005
11. Wang HS, Kim HS, Ju CI, Kim SW : Delayed bone cement displacement following balloon kyphoplasty. *J Korean Neurosurg Soc* 43 : 212-214, 2008