

Clinical Article

Clinically Correlated Anatomical Basis of Cricothyrotomy and Tracheostomy

Salih Gulsen, M.D.,¹ Melih Unal, M.D.,² Ahmet Hakan Dinc, M.D.,² Nur Altinors, M.D.¹

Department of Neurosurgery,¹ Faculty of Medicine, Baskent University Medical Faculty, Ankara, Turkey

State Institute of Forensic Medicine,² Ministry of Justice, Morque Department, Ankara, Turkey

Objective : Cricothyrotomy and tracheostomy are performed by physicians in various disciplines. It is important to know the comprehensive anatomy of the laryngotracheal region. Hemorrhage, esophageal injury, recurrent laryngeal nerve injury, pneumothorax, hemothorax, false passage of the tube and tracheal stenosis after decannulation are well known complications of the cricothyrotomy and tracheostomy. Cricothyrotomy and tracheostomy should be performed without complications and as quickly as possible with regards the patients' clinical condition.

Methods : A total of 40 cadaver necks were dissected in this study. The trachea and larynx and the relationship between the trachea and larynx and the surrounding structures was investigated. The tracheal cartilages and annular ligaments were counted and the relationship between tracheal cartilages and the thyroid gland and vascular structures was investigated. We performed cricothyrotomy and tracheostomy in eleven cadavers while simulating intensive care unit conditions to determine the duration of those procedures.

Results : There were 11 tracheal cartilages and 10 annular ligaments between the cricoid cartilage and sternal notch. The average length of trachea between the cricoid cartilage and the suprasternal notch was 6.9 to 8.2 cm. The cricothyroid muscle and cricothyroid ligament were observed and dissected and no vital anatomic structure detected. The average length and width of the cricothyroid ligament was 8 to 12 mm and 8 to 10 mm, respectively. There was a statistically significant difference between the surgical time required for cricothyrotomy and tracheostomy ($p < 0.0001$).

Conclusion : Tracheostomy and cricothyrotomy have a low complication rate if the person performing the procedure has thorough knowledge of the neck anatomy. The choice of tracheostomy or cricothyrotomy to establish an airway depends on the patients' clinical condition, for instance; cricothyrotomy should be preferred in patients with cervicothoracic injury or dislocation who suffer from respiratory dysfunction. Furthermore; if a patient is under risk of hypoxia or anoxia due to a difficult airway, cricothyrotomy should be preferred rather than tracheostomy.

KEY WORDS : Anatomy · Cricothyrotomy · Tracheostomy.

INTRODUCTION

Although they are among the most commonly performed operations in critical patients, cricothyrotomy and tracheostomy are often considered relatively safe procedures⁴. However, performing cricothyrotomy or tracheostomy is not without risk and major or minor complications and operative mortality may occur because of the poor clinical condition of the patient^{7,20}. The mortality rate of tracheostomy is reported as 2%¹¹. Complications associated with

the tracheostomy include arterial injury, esophageal injury, recurrent laryngeal nerve injury, pneumothorax, hemothorax, hemorrhage, brachial plexus injury, false passage of the tube, infection, tracheoesophageal fistula, subglottic stenosis and tracheal stenosis after the decannulation^{15,20,23}. The complications of tracheostomy and cricothyrotomy can be prevented with thorough knowledge of the anatomy of the neck region.

The aim of the present study was to analyze the anatomical features of the larynx and trachea and to show the relationship between the laryngotracheal region and the surrounding structures, and to demonstrate the safe region for cricothyrotomy and tracheostomy.

MATERIALS AND METHODS

A total of 40 fresh neck cadavers were evaluated between

• Received : November 4, 2008 • Revised : February 19, 2009
 • Accepted : January 31, 2010
 • Address for reprints : Salih Gulsen, M.D.
 Department of Neurosurgery, Faculty of Medicine Baskent University,
 Fevzi Cakmak Caddesi 10. Sokak no : 45, Cankaya, Bahcelievler,
 Ankara, Turkey 06490
 Tel : +0090 312 212 68 68/1362, Fax : +0090 312 223 73 33
 E-mail : salihgulsen07@gmail.com

April 2008 to October 2008 to understand the exact anatomy of the trachea and larynx. Any cadaver that had suffered neck damage was excluded from the study. The average age of the cadavers was 42 and 29 male and 11 female cadavers were eligible for our study. External skin markers indicating the borders of the larynx and trachea at the neck region were determined (Fig. 1). The skin of the anterior part of the neck was opened from the suprasternal notch to the lower part of the mandible at the midline. After the skin incision, the platysma muscle was dissected and the sternocleidomastoid muscles and strap muscles around the trachea were observed (Fig. 1, 2, 3). The neck midline was opened and the muscles around the trachea and larynx dissected. The relationship between the larynx and the trachea and the structures located just around the laryngotracheal region were investigated (Fig. 2, 3, 4). The neck of the all cadavers was in an extended position for tracheostomy and in the neutral position with the mandibula pulled toward the maxilla for cricothyrotomy. Extending the neck position was provided with an infrascapular, horizontally placed surgical pad while the surgical pad was removed for a neutral position of the neck. We performed cricothyrotomy and tracheostomy in eleven cadavers while

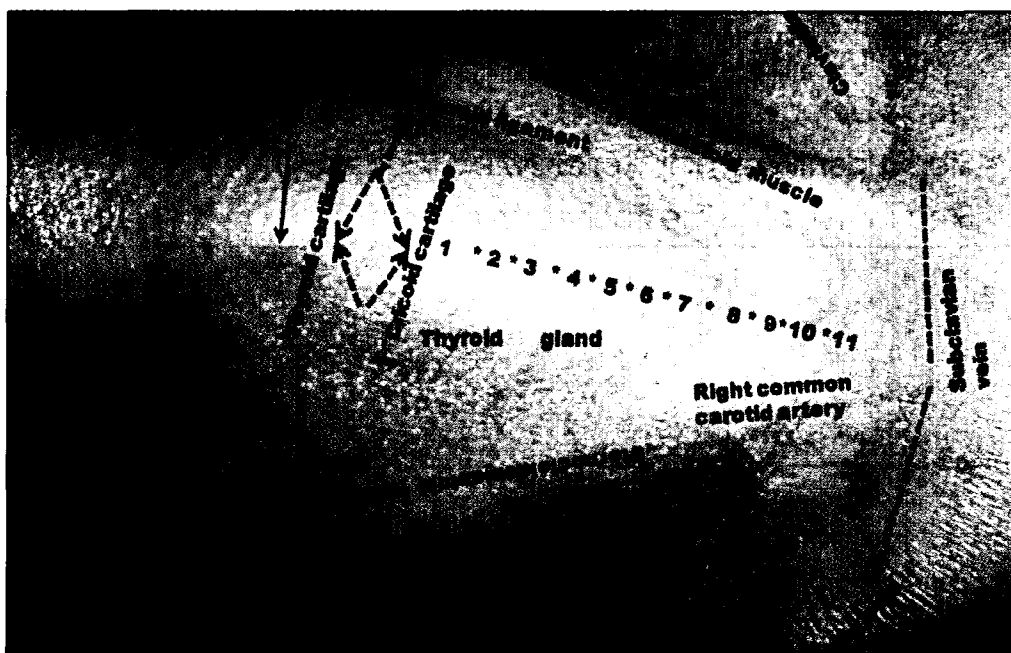


Fig. 1. Anterior part of the neck showing important external landmarks on the skin.

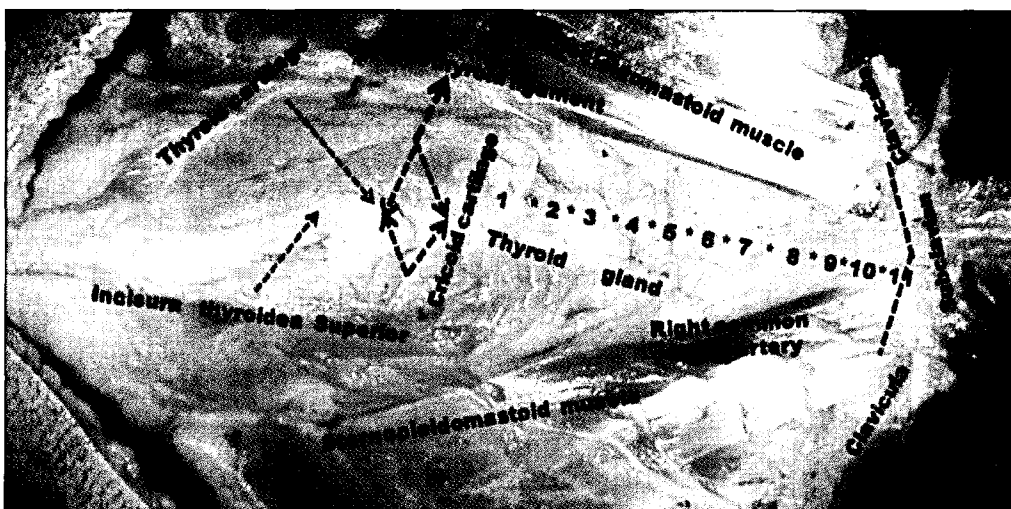


Fig. 2. Anterior part of the neck, after the vertical midline incision extended from the sternal notch to the inferior surface of the mandibula. The skin tissue and platysma muscle were undermined and dissected for showing the anatomy corresponding to the external markers of the skin, and this picture showing only muscular structures around the laryngotracheal region.

simulating intensive care unit conditions to determine the duration of those procedures. We selected 8 male and 3 female cadavers from the total of 40 cadavers. The average age of the cadavers was 37 years. The complete procedure and the duration of each step are shown in Table 1 and 2. The region of the trachea and larynx considered to be a relatively safe place for tracheostomy and cricothyrotomy was determined with corresponding external markers. Recurrent laryngeal nerves were not observed within the surgical borders of the cricothyrotomy and tracheostomy in any case. The student t-test was performed to analyze statistical significance regarding the surgical duration for cricothyrotomy and tracheostomy. Photographs were taken with a Sony camera (Model No : DSC- W 200, SDPW, Sony CORP).

RESULTS

Forty cases were analyzed. There were 11 tracheal cartilages and 10 annular ligaments between the cricoid cartilage and sternal notch (Fig. 4). The average length of trachea between the cricoid cartilage and the suprasternal notch was 6.9 to 8.2 cm. The cricothyroid muscle and cricothyroid ligament were observed and dissected and no vital anatomic structure detected. The average length and width of the cricothyroid ligament was 8 to 12 mm and 8 to 10 mm, respectively (Fig.

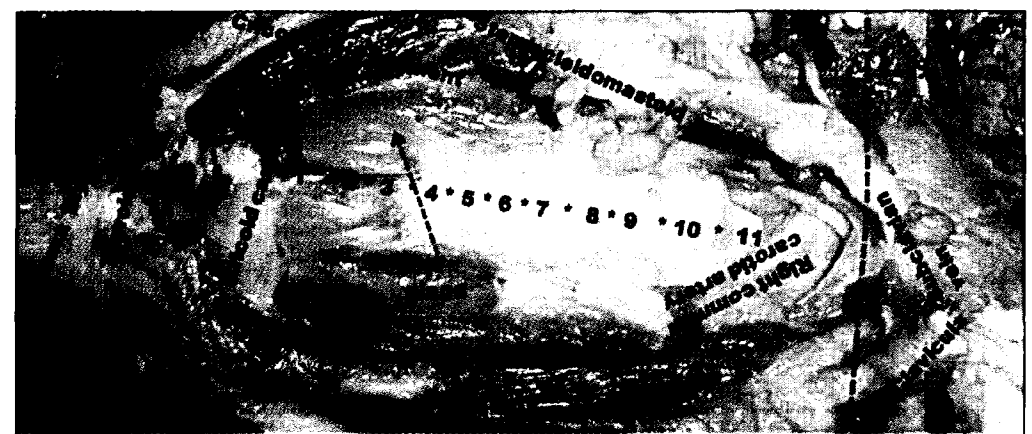


Fig. 3. Anterior part of the neck. This picture showing thyroid cartilage, cricoid cartilage, tracheal cartilages, vascular structures. Thyroid gland was completely dissected from the anterior part of the trachea for showing the tracheal cartilages. *Stars showing the annular ligament of the trachea (numbers) : the numbers showing the array of the tracheal cartilages.

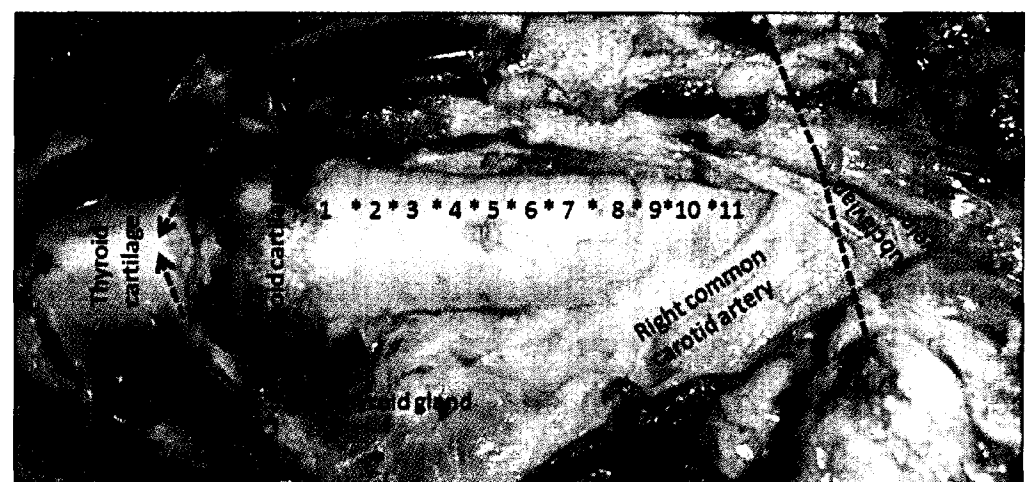

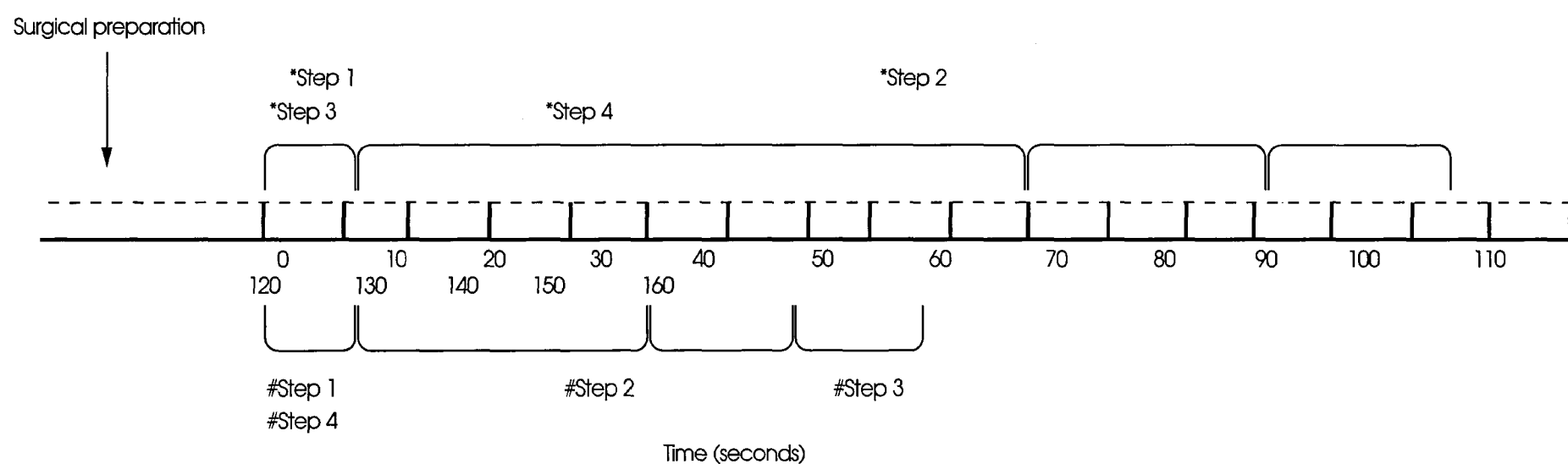
Fig. 4. Anterior part of the neck. This picture showing thyroid cartilage, cricoid cartilage, thyroid gland and also borders of the cricothyroid ligament. *Stars showing the annular ligament of the trachea (numbers) : the numbers showing the array of the tracheal cartilages.

Table 1. Showing the surgical steps for tracheostomy and cricothyrotomy

Tracheostomy	Cricothyrotomy
Instruments Scalpel with no. 15 and 11 blades, tissue scissors, tracheal retractor, wound retractor, tissue forceps, Cuffed Blue Line Ultra® Tracheostomy Tubes no. 6, 7, 8	Instruments Scalpel with no. 15 and 11 blades, dissecting forceps, tissue forceps, tissue scissors, wound retractor, Cuffed Blue Line Ultra® Tracheostomy Tubes no. 6, 7, 8
Position of the patient The neck in the extension position	Position of the patient Mandibula should be pulled toward head and the neck in the neutral position or very mild extending position because of pulling of the mandibule toward the head
Position Standing on the patient's right side	Position Standing on the patient's right side
Steps 1-Midline vertical incision should be started 5 mm above the suprasternal notch, 3 cm long (note : Suprasternal notch should be palpated) 2-Dissection of the deeper part of the incision line 3-Trying to feel the tracheal cartilage. After feeling of the tracheal cartilage, dissecting the tissues to identify the tracheal cartilages If it is necessary, dissect inferior part of the thyroid and pull it toward caudally with tacked surgical suture 4-Cut the one or two tracheal cartilage 6 mm × 6 mm as the square and insert the appropriate size of the tracheostomy tube	Steps 1-Midline vertical incision should be started region of the cricoid cartilage and incision line extending 8 mm above and below the cricoid cartilage (note : cricoid cartilage should be palpated) 2-Dissection of the deeper part of the incision line 3-Trying to feel the cricothyroid ligament. After feeling of the cricothyroid ligament, dissecting the tissues to identify to the cricothyroid ligament 4-Cut the cricothyroid ligament and insert the appropriate size of the tracheostomy tube

Table 2. The duration of the each surgical steps for tracheostomy and cricothyrotomy

Tracheostomy*	Cricothyrotomy
Step 1 Incision of the tracheostomy region	Step 1 Incision of the cricothyrotomy region
Step 2 Dissection of the deeper part of incision line	Step 2 Dissection of the deeper part of incision line
Step 3 Identifying of the tracheal cartilage	Step 3 Identifying of the cricothyroid ligament
Step 4 Insertion of the tracheostomy tube	Step 4 Insertion of the tracheostomy tube



5, 6). In 29 cases, the thyroid gland extended from the cricoid cartilage to the 2nd, 3rd, 4th or 5th tracheal cartilages. In 11 cases, the thyroid gland extended from the cricoid cartilage to the 8th, 9th, 10th tracheal cartilages. The average distance between the right common carotid artery and the midline was 0.9 cm to 1.2 cm. The average distance between the sternal notch and the right common carotid artery was 0.7 cm to 1.1 cm. The average distance between the left common carotid artery and the midline was 1.4 cm to 1.8 cm. The left common carotid artery was about the same level as the sternal notch. The aortic arch was just

below the sternal notch. The left brachiocephalic vein was just beneath the sternal notch and above the left common carotid artery. Truncus brachiocephalicus was 5 mm above the suprasternal notch in only one case (Fig. 7). The average time for performing cricothyrotomy and tracheostomy was 88 seconds and 155 seconds, respectively. There was a statistical significant difference between the surgical period required for cricothyrotomy and tracheostomy ($p < 0.0001$) (Fig. 8). The surgical steps, the duration of each step and a comparative graphic of the surgical time for cricothyrotomy and tracheostomy are shown in Table 1 and 2.

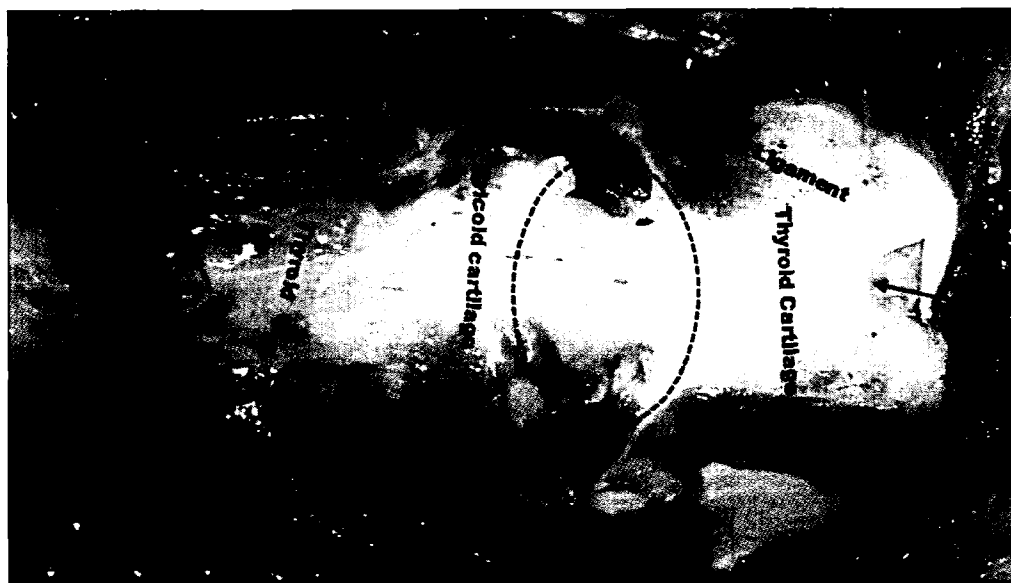

Fig. 5. Anterior part of the neck. After complete dissection of the tissues around the cricoid cartilage and cricothyroid Ligament. The dotted line showing the borders of the cricothyroid ligament.

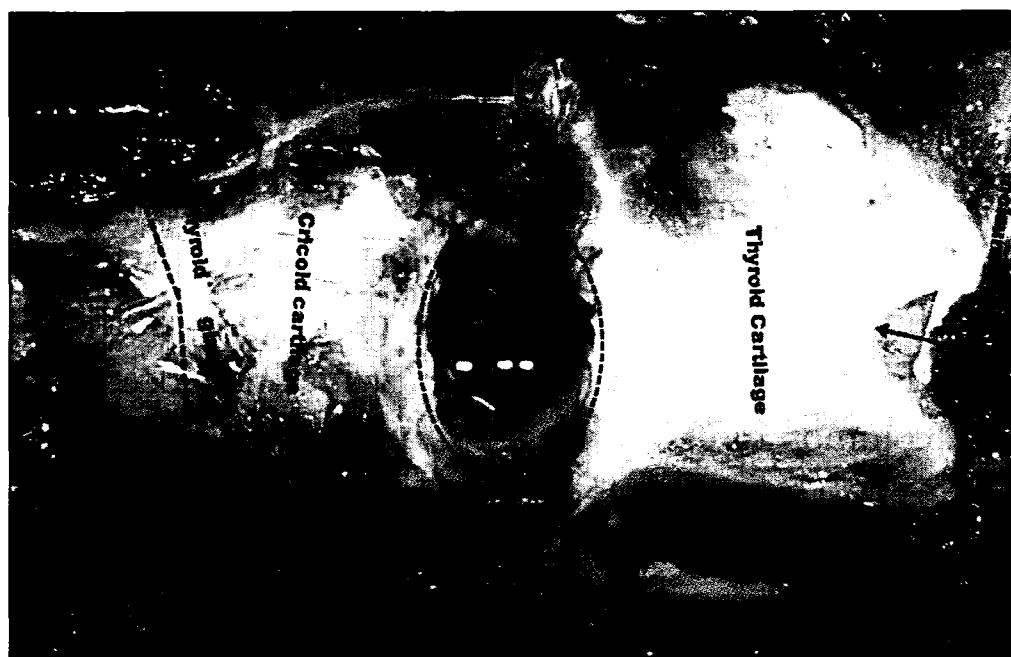

Fig. 6. Anterior part of the neck. After complete dissection of the tissues around the cricoid cartilage and cricothyroid ligament. Cricothyroid ligament was opened for demonstrating the borders of the cricothyroid ligament. The dotted line showing the borders of the cricothyroid ligament.

DISCUSSION

Cricothyrotomy and tracheostomy have been performed for many years^{9,11,16}. These surgical procedures are performed by otolaryngologists, general surgeons, thoracic surgeons and neurosurgeons. Cricothyrotomy and tracheostomy are essential intervention for patients in critical conditions or injured patients, such as following maxillofacial trauma, cranial trauma and multi-organ injury, and it provides improved care for patients in the trauma or critical care setting and reduced the hospital and patient costs^{10,14-16,19}. These procedures are also indicated in patients with difficult airway. The American Society of Anesthesiologists describes a difficult airway as “clinical situation in which a conventionally trained anesthesiologist experiences difficulty with face mask ventilation of the upper airway, difficulty with tracheal intubation, or both”. Endotracheal intubation can be performed in the prehospital environment with success rates as high as 98.2% and as low as 33%^{2,3,5,8} as increasing laryngoscopic attempts lead to increasing incidence of hypoxia^{7,8}. This hypoxia induces the risk of bradycardia and cardiac arrest and leads to secondary insult in traumatic




Fig. 7. Anterior part of the neck. Sternum was removed for demonstrating below the suprasternal notch. The line showing to the suprasternal notch. The relationship between vascular structures, thyroid gland and trachea. Truncus brachiocephalicus was seen higher than normal level and right thyroid lobe was bigger size than left thyroid lobe.

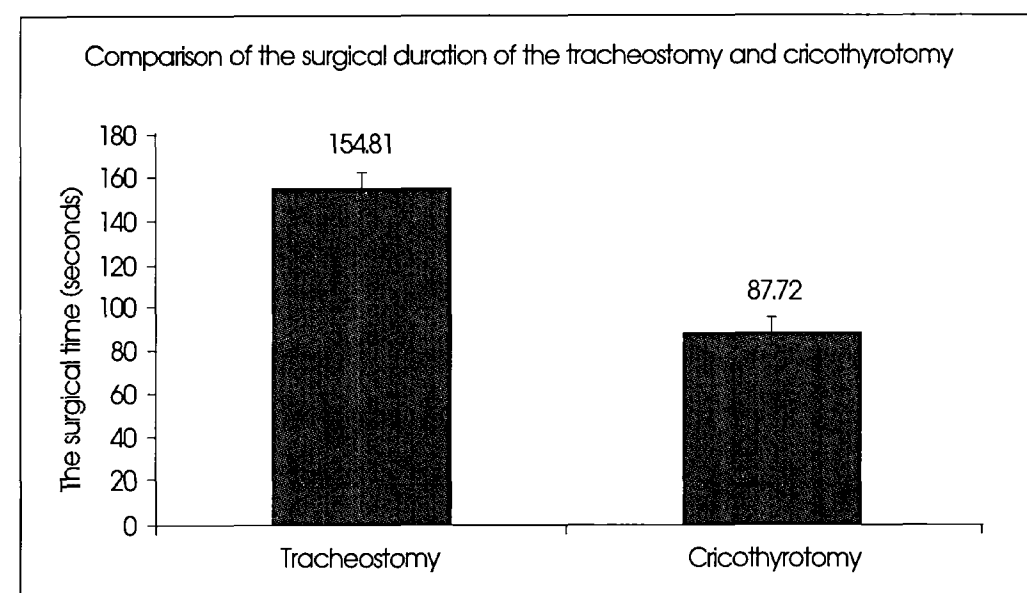


Fig. 8. This graphic showing the comparison of the performing duration of the the tracheostomy and cricothyrotomy.

brain injury^{13,18,19}. When oral endotracheal intubation is not successful, rescue ventilation with a bag valve mask must be swiftly employed to prevent hypoxia from developing. On the contrary, if the patient cannot be intubated and also cannot be adequately oxygenated or ventilated with bag valve mask ventilation, the situation may be rapidly lethal^{15-7,13,18,19,24}. As mentioned above, cricothyrotomy and tracheostomy are the methods of choice for patients in a critical condition and who have a difficult airway, and these procedures should therefore be performed swiftly and without any complication^{1,21}. Tracheostomy can cause many complications^{1,15}. We believe that methodical knowledge of neck region anatomy is the most important aspect of conventional cricothyrotomy and tracheostomy, and also for the application of new methods such as wire-guided cricothyrotomy and the Griggs technique for Tracheostomy^{1,4,15,16,18,21}. Scurry and McGinn²² reported that high-riding truncus brachiocephalicus (innominate artery) causes fatal hemorrhage risk during inferior dissection. Lateral dissection of the trachea can result in fatal hemorrhage due to distorted patient anatomy or morbid obesity. Different authors recommend Heffner's subthyroid tracheostomy

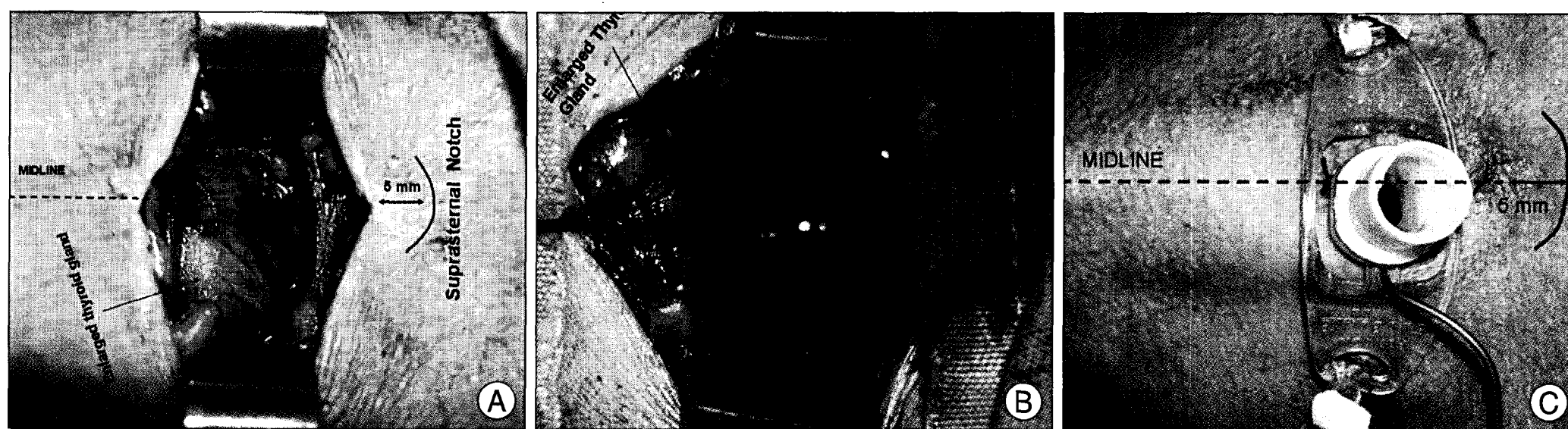

Fig. 9. A : This demonstrative case from our clinic showing goitre extending into jugulum. Goitre obviated to exposure to the trachea. B : Tackling of the thyroid gland with 4.0 surgical suture and pulling of the thyroid gland with surgical suture allowed us to perform tracheostomy. Stars showing the tracheostomy region. C : Tracheostomy was performed and the Cuffed Blue Line Ultra® Tracheostomy Tube No : 8 was placed.

while some authors believe that cautery division or suture ligation of the thyroid gland decreases the risk of tube dislodgement during swallowing and pressure of the tube on the anterior tracheal wall^{12,17}. We infer that subthyroid tracheostomy is safer than other tracheostomy techniques as our incision region as shown in Fig. 1 and 2 is far from critical structures as regards hemorrhage risk, such as truncus brachiocephalicus (innominate artery), the right common carotid artery and the thyroid gland. The position of the cadavers was also important in reaching the trachea and cricothyroid ligament. Regarding our study; supporting the interscapular region with the horizontally placed pad to extend the neck was the best position for the patients undergoing tracheostomy, as extension of the neck provides a shallow depth for reaching the trachea, but we did not think similarly regarding cricothyrotomy. The position of the mandibula is more important than neck extension in cricothyrotomy. The mandibula should be pulled toward the head and the patient's neck may be in the neutral position or mildly in extension position to provide a better position for cricothyrotomy. These positions are especially important in various clinical conditions such as spinal column injury and in multi-trauma patients. Cricothyrotomy can be performed safely in patients with cervicothoracic injury such as cervicothoracic dislocation or any cervical vertebra fracture, but tracheostomy would be disastrous in patients with cervicothoracic injury. Either tracheostomy or cricothyrotomy could be chosen for establishing an airway in cases other than cervical or cervicothoracic junction injury. Cricothyrotomy should be the first choice in any patient presenting with respiratory difficulty and in any suspicion of cervicothoracic injury. We did not encounter the recurrent laryngeal nerve on either side of the anterior part of the laryngotracheal region. The risk of injury to the recurrent laryngeal nerve is very low without penetrating or cutting the lateral edges of the laryngotracheal region. The major vascular structures such as truncus brachiocephalicus (inno-

minate artery), common carotid artery, vertebral artery, brachiocephalic vein and subclavian vein are of major importance during tracheostomy and cricothyrotomy, however cricothyrotomy is safer regarding vertebral artery, innominate artery and subclavian vein injury. The major concern regarding vascular structures while performing tracheostomy is to preserve the subclavian vein, brachiocephalic vein, common carotid artery and truncus brachiocephalicus (Fig. 4, 7). These arterial structures are located at the border of and just below to the sternal notch. We think that the sternal notch is one of the most important markers for determining the inferior border of the tracheostomy. We recommend that incision and dissection area should be started 5 mm away from the sternal notch and extended in the midline and vertically upwards 1-3 cm (Fig. 1-4, 7). This incision and dissection would provide some advantages; the first one is to preserve the vascular structures, the second one is to expose to the trachea from the lower border of the thyroid tissue without elevating and dissecting from the trachea and without cutting to the thyroid and risking damage to any thyroidal artery; however, we had to dissect and elevate the thyroid tissue from the trachea in one case with goitre. The final advantage of this approach is the prevention of tracheal stenosis after decannulation. We demonstrated that the chosen incision place on the skin corresponds to the 6th, 7th, 8th, 9th or 10th tracheal cartilages and cutting of one or two tracheal cartilages would not cause tracheal stenosis or subglottic stenosis, but prospective clinical studies should be performed to support our notion about tracheal stenosis regarding these levels of tracheostomy. Furthermore, cutting of one or two tracheal cartilages at the level of the 8th or 9th tracheal cartilages could be effective in cases with a goitre extending to the jugular fossa or further. We performed more than sixty tracheostomies in our clinic in the way described in this study, and we have not noticed tube dislodgement during swallowing or tracheal stenosis after decannulation or any

other complication. We have come across goitre during tracheostomy in our clinic, and we successfully managed it with the technique described in this study (Fig. 9) (unpublished data). Cricothyrotomy is performed in emergency situations in the prehospital period or in a hospital. Cricothyrotomy should be performed within three minutes to save a life and the consequences of a late cricothyrotomy may be disastrous for patients in critical condition^{15,21}. We believe that methodical knowledge of the anatomy, the relationship between skin markers and palpation findings can be helpful in determining the exact location of the cricoid cartilage and cricothyroid ligament (Fig. 1, 4, 7).

We performed cricothyrotomy and tracheostomy in ten cadavers while simulating bedside conditions in the autopsy room. We demonstrated that cricothyrotomy took less time than tracheostomy ($p < 0.0001$). The average duration for performing cricothyrotomy and tracheostomy was 88 seconds and 155 seconds, respectively. Cricothyrotomy is also a safer method than tracheostomy regarding vascular injury, recurrent laryngeal nerve injury, esophageal injury and thyroidal vascular bleeding in cases with goitre. Cricothyrotomy should also be preferred in patients with cervicothoracic injury as the surgeon can perform this procedure in the neutral neck position instead of extending the neck as for tracheostomy.

CONCLUSION

Our study showed that cricothyrotomy and tracheostomy are safe methods to establish an airway, but cricothyrotomy seems to be a safer and quicker method than tracheostomy. However, a surgeon knowing the comprehensive anatomy of the neck region can safely perform cricothyrotomy or tracheostomy. The tracheostomy incision line should be started 5 mm above the suprasternal notch at the midline and tracheal cartilages should be cut approximately at any level between the 6th, 7th, 8th, 9th and 10th tracheal cartilages to prevent tracheal stenosis after decannulation and an intervention to the thyroid or thyroidal artery. We emphasize that cricothyrotomy should be preferred in patients with cervicothoracic injury. Furthermore, cricothyrotomy should also be preferred to tracheostomy if a patient is under a risk of hypoxia or anoxia due to difficult airway.

References

- Ahmed N, Kuo YH : Early versus late tracheostomy in patients with severe traumatic head injury. *Surg Infect (Larchmt)* 8 : 343-347, 2007
- American Society of Anesthesiologists Task Force on Management of the Difficult Airway : Practice guidelines for management of the difficult airway : an updated report by the American Society of Anesthesiologists Task Force on Management of the Difficult Airway. *Anesthesiology* 98 : 1269-1277, 2003
- Bair AE, Filbin MR, Kulkarni RG, Walls RM : The failed intubation attempt in the emergency department : analysis of prevalence, rescue techniques, and personnel. *J Emerg Med* 23 : 131-140, 2002
- Bonanno FG : Techniques for emergency tracheostomy. *Injury* 39 : 375-378, 2008
- Bulger EM, Copass MK, Maier RV, Larsen J, Knowles J, Jurkovich GJ : An analysis of advanced prehospital airway management. *J Emerg Med* 23 : 183-189, 2002
- De Leyn P, Bedert L, Delcroix M, Depuydt P, Lauwers G, Sokolov Y, et al. : Tracheotomy : clinical review and guidelines. *Eur J Cardiothorac Surg* 32 : 412-421, 2007
- Dob DP, McLure HA, Soni N : Failed intubation and emergency percutaneous tracheostomy. *Anaesthesia* 53 : 72-74, 1998
- Dunford JV, Davis DP, Ochs M, Doney M, Hoyt DB : Incidence of transient hypoxia and pulse rate reactivity during paramedic rapid sequence intubation. *Ann Emerg Med* 42 : 721-728, 2003
- Ellis H : Applied anatomy of cricothyrotomy and tracheostomy. *Br J Hosp Med (Lond)* 67 : M168-M169, 2006
- Freeman BD : Is there a hidden benefit associated with early tracheostomy? *Crit Care Med* 36 : 2688-2689, 2008
- Goldenberg D, Ari EG, Golz A, Danino J, Netzer A, Joachims HZ : Tracheotomy complications : a retrospective study of 1130 cases. *Otolaryngol Head Neck Surg* 123 : 495-500, 2000
- Heffner JE, Miller KS, Sahn SA : Tracheostomy in the intensive care unit. Part 1 : Indications, technique, management. *Chest* 90 : 269-274, 1986
- Jaeger K, Ruschulte H, Osthaus A, Sheinichen D, Heine J : Tracheal injury as a sequence of multiple attempts of endotracheal intubation in the course of reclinical cardiopulmonary resuscitation. *Resuscitation* 43 : 147-150, 2000
- Kane TD, Rodriguez JL, Luchette FA : Early versus late tracheostomy in the trauma patient. *Respir Care Clin N Am* 3 : 1-20, 1997
- Lewis RJ : Tracheostomies. Indications, timing, and complications. *Clin Chest Med* 13 : 137-149, 1992
- Libert N, Leclerc T, De Rudnicki S : Cricothyroidotomy. *N Engl J Med* 359 : 1073-1074, 2008
- McWhorter AJ : Tracheotomy : timing and techniques. *Curr Opin Otolaryngol Head Neck Surg* 11 : 473-479, 2003
- Mort TC : Emergency tracheal intubation : complications associated with repeated laryngoscopic attempts. *Anesth Analg* 99 : 607-613, 2004
- Mort TC : The incidence and risk factors for cardiac arrest during emergency tracheal intubation : a justification for incorporating the ASA Guidelines in the remote location. *J Clin Anesth* 16 : 508-516, 2004
- Myers EN, Carrau RL : Early complications of tracheotomy. Incidence and management. *Clin Chest Med* 12 : 589-595, 1991
- Schlossmacher P, Martinet O, Testud R, Agesilas F, Benhamou L, Gauzère BA : Emergency percutaneous tracheostomy in a severely burned patient with upper airway obstruction and circulatory arrest. *Resuscitation* 68 : 301-305, 2006
- Scurry WC Jr, McGinn JD : Operative Techniques in Otolaryngology. *Tech Head Neck Surg* 18 : 85-89, 2007
- Stock MC, Woodward CG, Shapiro BA, Cane RD, Lewis V, Pecaro B : Perioperative complications of elective tracheostomy in critically ill patients. *Crit Care Med* 14 : 861-863, 1986
- Wang HE, Yealy DM : How many attempts are required to accomplish out-of-hospital endotracheal intubation? *Acad Emerg Med* 13 : 372-377, 2006