

A case of thanatophoric dysplasia type I with an R248C mutation in the *FGFR3* gene

Eun Jung Noe, M.D.¹, Han Wook Yoo, M.D.², Kwang Nam Kim, M.D.¹, and So Yeon Lee, M.D.¹

Department of Pediatrics¹, College of Medicine, Hallym University, Seoul,

Department of Pediatrics², Medical Genetics Clinic & Laboratory, Asan Medical Center, Seoul, Korea

Received: 16 April 2010, Revised: 19 August 2010

Accepted: 12 October 2010

Corresponding author: So Yeon Lee, M.D.

Department of Pediatrics Hallym University Medical Center 896, Pyeongchon-dong, Dongan-gu, Anyang, Gyeonggi-do 431-070, Korea

Tel: +82.31-380-3730, Fax: +82.31-380-3733

E-mail: imipenem@hanmail.net

Thanatophoric dysplasia (TD) is a short-limb neonatal dwarfism syndrome that is usually lethal in the perinatal period. It is characterized by shortening of the limbs, severely small thorax, large head with a prominent forehead, macrocephaly, curved femur, and flattened vertebral bodies. These malformations result from the mutation in fibroblast growth factor receptor 3 (*FGFR-3*) gene which is located on the short arm of chromosome 4. A definite diagnosis should be established by molecular genetic analysis to find out the abnormal mutations in the *FGFR3* gene. We confirmed by detection of a R248C mutation in the *FGFR3* gene in DNA analysis.

Key words: Thanatophoric dysplasia, Fibroblast growth factor receptor 3 (*FGFR3*) gene

Copyright © 2010 by The Korean Pediatric Society

This is an open-access article distributed under the terms of the Creative Commons Attribution Non-Commercial License (<http://creativecommons.org/licenses/by-nc/3.0/>) which permits unrestricted non-commercial use, distribution, and reproduction in any medium, provided the original work is properly cited.

Introduction

Thanatophoric dysplasia (TD) is a lethal chondrodysplasia caused by fibroblast growth factor receptor 3 (*FGFR3*) gene mutation which is located on the short arm of chromosome 4. The most frequent mutations (p.R248C, p.S249C, p.Y373C) create a cysteine residue within the extracellular domain. It was first described in 1967 by Maroteaux and Lamy¹⁾. It is the most common form of lethal congenital skeletal dysplasia, with an incidence of 1 in 20,000 to 40,000 live births²⁾. TD is divided into type I, characterized by micromelia with bowed femurs and type II, characterized by micromelia with straight femurs. Other features of type I and type II include: short limbs, large head with frontal bossing, depressed nasal bridge, narrow thoracic cage with severe respiratory insufficiency, flat vertebral body (platyspondyly), and

short pelvis. To our knowledge, there have only been about 20 cases of clinically diagnosed TD reported in Korea. Most of them were diagnosed by prenatal ultrasound and all these pregnancies were terminated. There were a few neonatal cases that were diagnosed clinically and radiologically, but none of the cases was confirmed by DNA analysis. We report a case of thanatophoric dysplasia type I which was diagnosed by the detection of the Arg248Cys mutation in DNA analysis.

Case report

A male baby was born by Cesarean delivery due to breech presentation and respiratory distress at the gestational age of 36 weeks and 2 days.

The baby's mother was a 19-year-old primigravida, single

mother and did not undergo any antenatal evaluation. She visited our hospital when her labor pains started. The prenatal two-dimensional ultrasound examination just before the delivery showed polyhydramnios and short-limbed dwarfism. She had no history of drug, alcohol, or tobacco abuse. The baby's parents were healthy, and there was no family history of congenital abnormalities. At birth, the baby's heart rate and body temperature were 52 beats/min and 36.7°C, respectively. His Apgar score was 1 and 1 at 1 and 5 minutes, respectively. General appearance was cyanotic blue colored. The findings of arterial blood gas analysis showed: pH 7.08, PaO₂ 44.7 mmHg, PaCO₂ 61.1 mmHg, HCO₃ 13.9 mmol/L and oxygen saturation was 75%, in spite of the oxygen therapy by face mask.

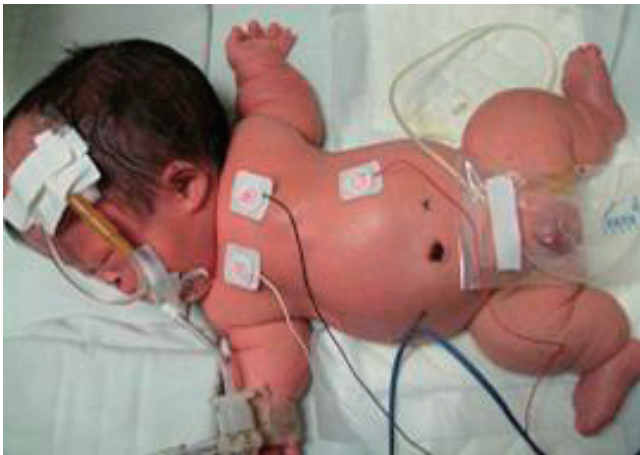

Fig. 1. Full-body photograph acquired on the 2nd day of life, showing large head, markedly short limbs, and narrow thorax.

He was intubated and resuscitated immediately and then transferred to the neonatal intensive care unit. The infantogram showed a small thoracic cage and consistent with respiratory distress syndrome, including both lung fields with inadequate inspiration of white out. The surfactant replacement therapy was performed with mechanical ventilation in the assist-control mode. After that, the baby's respiratory and hemodynamic status had been stabilized.

The laboratory findings on admission day were WBC 24,760/mm³ (neutrophils 47%, lymphocytes 38%), a hemoglobin level of 17.7 g/dL, hematocrit 54.8%, platelet 239,000/mm³, serum Na 135 mmol/L, K 4.5 mmol/L, AST/ALT 59/14 IU/L, BUN/Cr 11.6/0.7 mg/dL, and CRP was non-reactive.

The body weight at birth was 2,740 g (25-50th percentile) and height was 39 cm (<5th percentile). The head circumference was 39.5 cm (>90th percentile), the thoracic circumference was 27 cm and the abdominal circumference was 30 cm. He had a large head with prominent forehead and midfacial hypoplasia, narrow thorax, very short limbs with a short neck, and a protuberant abdomen (Fig. 1).

The radiographs showed a large calvaria with a small cranial base, marked thinning and flattening of the vertebral bodies, short ribs, hypoplasia of the pelvic bones, and small curved long bones so called telephone receiver femur (Fig. 2).

The baby was examined for R248C mutation by use of restriction digestion and direct sequencing. The results showed that the baby carried R248C mutation. In this case, nucleotide sequence analysis of cDNA revealed a C to T transition at nucleotide 742 (C742T) in one allele of the *FGFR3* gene. This heterozygous 742C → T

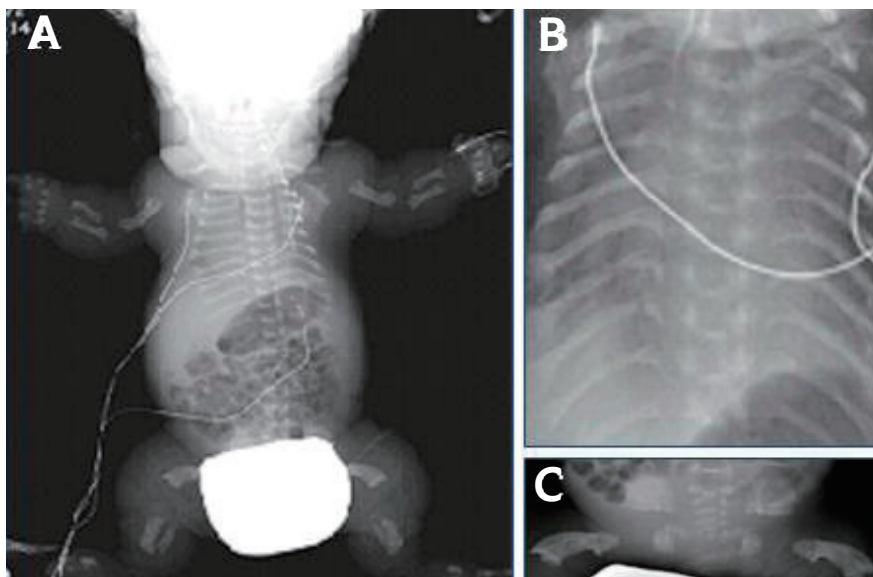


Fig. 2. Newborn infantogram demonstrating thanatophoric dysplasia type I (TD1) findings, including platyspondyly, a severely hypoplastic pelvis, long bone shortness (A), hypoplasia of the lungs and thorax (B), and femoral bowing ("telephone receiver" femur) (C).

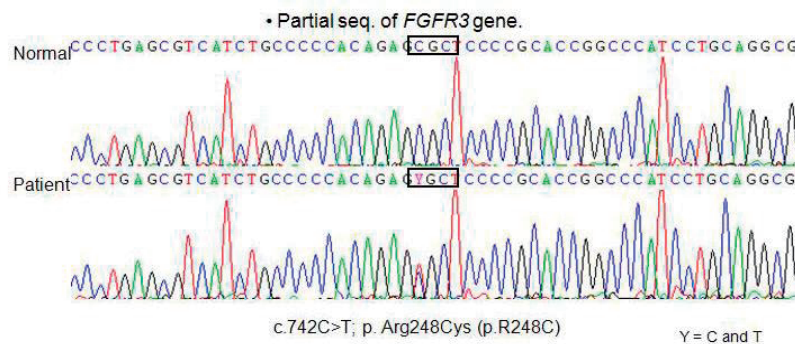


Fig. 3. DNA sequencing of the *FGFR3* gene showing Arg248Cys mutation in R248C.

(R248C) mutation in the *FGFR3* leading to an Arg248Cys (CGC → TGC) substitution (Fig. 3). This genetic condition causing type I thanatophoric dysplasia. Despite of the mechanical ventilation, the baby's oxygen saturation levels are decreased day by day. Finally the baby died of respiratory failure, due to narrow thorax with pulmonary hypoplasia at 4 months of age.

Discussion

The term thanatophoric dysplasia (TD) originates from a Greek term for "death bearing". TD is characterized by an abnormal head, face, thorax and skeleton. The head anomaly consists of megacephaly, occasionally with a cloverleaf-shaped skull known as kleeblattschödel. In the face, excess skin usually yields a "boxers' face" appearance, with frontal bossing and a depressed nasal bridge. A hypoplastic thorax is common, which is disproportionately small in relation to the abdomen. Classically, a bell-shaped thorax has the shape of a champagne bottle cork and results in pulmonary hypoplasia. Ribs are hypoplastic, and the long bones of the extremities are short and curved, resulting in telephone receiver-shaped femurs. Vertebrae are flattened with diminution of the intervertebral spaces³⁻⁵.

Based on bone deformity pattern, TD has been divided into two types. Type I is more common and is characterized by curved long bones (with a 'telephone receiver' appearance) and severe platyspondylia, usually without a cloverleaf skull. In type II, the long bones are relatively straight, the platyspondylia is less severe, and a cloverleaf skull is usually present⁶. Affected individuals generally die within minutes or days after birth, usually from respiratory failure.

TD is an autosomal dominant disorder caused by sporadic de novo mutations in the *FGFR3* gene mapped chromosome band 4p16.32). The *FGFR3* gene is a cell surface protein consisting of extracellular, transmembrane and intracellular domains. It is particularly abundant in the cartilage growth plates⁷. Mutations in

different domains of the *FGFR3* gene are responsible for a variety of chondrodysplasias ranging from very mild hypochondroplasia to lethal TD including chondrodysplasia and Crouzon syndrome⁸. Essentially, all TD patients examined so far have had mutations in the transmembrane domains of *FGFR3*. TD II cases have a single recurrent mutation (A to G) in the tyrosine kinase domain of *FGFR3*, but TD I cases have different mutations affecting either the extracellular or intracellular domains of *FGFR3*⁸. Although, a total of 12 distinct missense mutations have been described for TD I cases, the most common TD I mutation is a C to T transition (C742T) that leads to substitution of arginine by cysteine in 248 position of polypeptide (R248C) in the extracellular domain of *FGFR3*⁹.

Molecular analysis of the *FGFR3* gene using PCR-based methods is useful for the rapid screening of fetuses with sonographic findings suggestive of TD⁹. Early prenatal diagnosis of TD can be established by ultrasonography in the second trimester of gestation. However, it is not always possible to differentiate TD from other skeletal dysplasias by ultrasonography alone; thus, molecular genetic analysis of the fibroblast growth factor receptor 3 (*FGFR3*) gene is useful for the prenatal diagnosis of TD. Prenatal diagnosis can allow for elective abortion to be carried out, thereby avoiding possible complications such as later caesarean section, difficult vaginal delivery due to hydrocephalus, and malpresentation later in the pregnancy¹⁰.

The overall prognosis is poor. Most patients die of respiratory insufficiency due to reduced chest circumference and hypoplastic lung within 48 hours, although four to nine year survivals have been reported^{11,12}.

The first case of TD in Korea was reported in 1989¹³, and there have been about 20 cases described since then. Most of the cases have been reported by obstetricians because they were diagnosed by the prenatal ultrasound and subsequently terminated.

However, this was the case of a single mother who had never had any prenatal evaluation until just before the delivery. The baby

had typical TD I findings, such as a large head with a prominent forehead, a flat face, micromelia with telephone receiver femurs, and a narrow chest. Moreover, the Arg248Cys mutation in the extracellular region of the *FGFR3* gene was identified with molecular study.

This case is the first report of a TD type I confirmed both radiologically and genetically in Korea.

References

- 1) Maroteaux P, Lamy M, Robert JM. Thanatophoric dwarfism. *Presse Med* 1967;75:2519-24.
- 2) Orioli IM, Castilla EE, Barbosa-Neto JG. The birth prevalence rates for the skeletal dysplasias. *J Med Genet* 1986;23:328-32.
- 3) Chen CP, Chern SR, Shih JC, Wang W, Yeh LF, Chang TY, et al. Prenatal diagnosis and genetic analysis of type I and type II thanatophoric dysplasia. *Prenat Diagn* 2001;21:89-95.
- 4) Machado LE, Bonilla-Musoles F, Osborne NG. Thanatophoric dysplasia. *Ultrasound Obstet Gynecol* 2001;18:85-6.
- 5) Tsutsumi S, Sawai H, Nishimura G, Hayasaka K, Kurachi H. Prenatal diagnosis of thanatophoric dysplasia by 3-D helical computed tomography and genetic analysis. *Fetal Diagn Ther* 2008;24:420-4.
- 6) Langer LO Jr, Yang SS, Hall JG, Sommer A, Kottamasu SR, Golabi M, et al. Thanatophoric dysplasia and cloverleaf skull. *Am J Med Genet Suppl* 1987;3:167-79.
- 7) Peters K, Ornitz D, Werner S, Williams L. Unique expression pattern of the FGF receptor 3 gene during mouse organogenesis. *Dev Biol* 1993;155:423-30.
- 8) Bonaventure J, Rousseau F, Legeai-Mallet L, Le Merrer M, Munnich A, Maroteaux P. Common mutations in the gene encoding fibroblast growth factor receptor 3 account for achondroplasia, hypochondroplasia and thanatophoric dysplasia. *Acta Paediatr Suppl* 1996;417:33-8.
- 9) Li D, Liao C, Ma X. Prenatal diagnosis and molecular analysis of type I thanatophoric dysplasia. *Int J Gynaecol Obstet* 2005;91:268-70.
- 10) Loong EP. The importance of early prenatal diagnosis of thanatophoric dysplasia with respect to obstetric management. *Eur J Obstet Gynecol Reprod Biol* 1987;25:145-52.
- 11) Yang WK, Park WI, Ko DS, Kim SH, Kim EK, Lee HJ. Mutation at exon 10 of the fibroblast growth factor receptor 3 (FGFR3) in a fetus with thanatophoric dysplasia type I (TDI). *Korean J Obstet Gynecol* 1999;42:2214-20.
- 12) Baker KM, Olson DS, Harding CO, Pauli RM. Long-term survival in typical thanatophoric dysplasia type 1. *Am J Med Genet* 1997;70:427-36.
- 13) Kwon HJ, Won EK, Min JS, Choi CH. A case of thanatophoric dysplasia. *Korean J Pediatr Soc* 1989;32:1598-602.