

A family with Townes-Brocks syndrome with congenital hypothyroidism and a novel mutation of the *SALL1* gene

Won Ik Choi, M.D.¹, Ji Hye Kim, M.D.¹, Han Wook Yoo, M.D.², and Sung Hee Oh, M.D.¹

Department of Pediatrics¹, Hanyang University School of Medicine, Seoul

Medical Genetic Clinics and Laboratory², Asan Medical Center, University of Ulsan College of Medicine, Seoul, Korea

Received: 15 April 2010, Revised: 1 September 2010

Accepted: 10 October 2010

Corresponding author: Sung Hee Oh, M.D.

Division of Infectious Diseases, Department of Pediatrics, College of Medicine, Hanyang University, 17 Haengdang-dong, Seongdong-gu, Seoul 133-791, Korea

Tel: +82.2-2290-8388, Fax: +82.2-2297-2380

E-mail: sungheeo@hanyang.ac.kr

Copyright © 2010 by The Korean Pediatric Society

This is an open-access article distributed under the terms of the Creative Commons Attribution Non-Commercial License (<http://creativecommons.org/licenses/by-nc/3.0/>) which permits unrestricted non-commercial use, distribution, and reproduction in any medium, provided the original work is properly cited.

Introduction

Townes-Brocks syndrome (TBS) is a genetic condition that affects several parts of the body, including most commonly imperforate anus, abnormally shaped ears, and hand malformations that mostly affect the thumb. Other possible signs and symptoms of TBS consist of hearing loss, foot malformation, heart defects, genitourinary abnormalities, and rarely eye abnormalities¹. Intellectual disability, learning problems, and mental retardation have also been reported in about 10 percent of people with TBS²⁻³.

TBS is confirmatively diagnosed with a mutation in the *SALL1* gene, a part of SALL genes that provide instructions for making proteins in the formation of tissues and organs before birth⁴. The

Townes-Brocks syndrome (TBS) is a rare autosomal dominant congenital disorder caused by mutations in the *SALL1* gene. Its signs and symptoms overlap with other genetic syndromes, including VACTERL association, Pendred syndrome, Baller-Gerold syndrome, and cat eye syndrome. Structural vertebral abnormalities, hypoplasia of the thumb, and radial bone abnormalities, which are not usually associated with TBS, help in the differential diagnosis of these syndromes. We report the case of a family whose members were diagnosed with TBS with congenital hypothyroidism and had a novel *SALL1* gene mutation.

Key words: Townes-Brocks syndrome, *SALL1*, Congenital hypothyroidism

syndrome is inherited by an autosomal dominant pattern or by a sporadic mutation without familial inheritance. We, herein, report a family whose members were diagnosed of TBS with congenital hypothyroidism and had a novel *SALL1* gene mutation.

Case report

A 4-month-old male infant was born vaginally at 37th week of gestation with a birth weight of 2,600 g after an uneventful pregnancy. At birth, he was noted to have unusually shaped ears with preauricular tags on the right ear (Fig. 1), polydactyly in his right thumb (Fig. 2), overriding toes of both feet (Fig. 3), and imperforate anus (Fig. 4). External ear canals and tympanic

membranes were grossly normal. Cardiac echocardiography showed no abnormalities. Abdominal ultrasonography showed hydronephrotic right kidney with a dilated ureter. The imperforate anus was repaired. Analysis on 24-hour urine specimen showed urine output of 1.12 mL/kg/hr; protein 1.75 mg/m²/hr; and the calculated creatinine clearance 14.47 mL/min/1.73 m²/24hr. Temporal bone CT revealed bilateral dysplastic cochleae. Brainstem

auditory evoked potential (BAEP) showed bilateral sensorineural hearing loss. Ophthalmologic examination revealed aniridia of the right eye, but orbit computed tomography (CT) was unremarkable. Neonatal thyroid screening test revealed abnormal results (TSH 99.70 μ U/mL; T3 102 ng/mL; free T4 1.11 ng/dL), which resulted in thyroxine replacement therapy for congenital hypothyroidism. The thyroid scan showed normal results. Chromosome analysis was normal.

Family history taking revealed an older brother with imperforate anus, congenital heart defect, malformation of the ears with right sided preauricular tag, polydactyly of right thumb, and congenital hypothyroidism, who had expired at the age of 3 months from complications of cardiac surgery. The patient also had a 4-year-old sister with bilateral low set ears but no other abnormal features. His mother had a history of a mild anal atresia at birth, bilateral dysplastic ears, hypoparathyroidism, bilateral sensorineural hearing loss which was corrected with hearing aids, and a ventricular septal defect which had spontaneously closed. His maternal grandmother's younger brother had malformation of both ears, but no hearing defect.

Clinical findings of the patient and pertinent family history

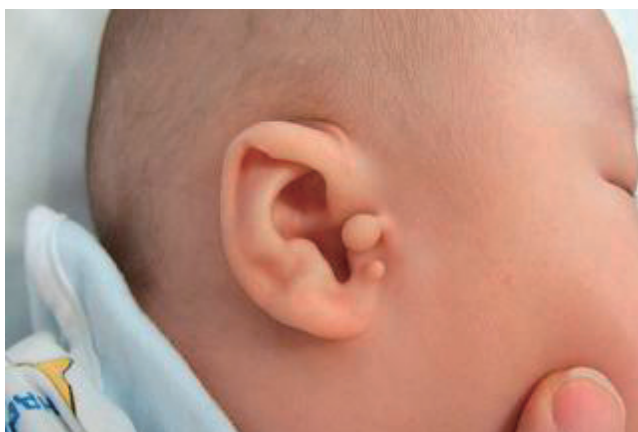

Fig. 1. The Townes-Brocks syndrome (TBS) patient shows dysplastic and low-set ear with preauricular tags.

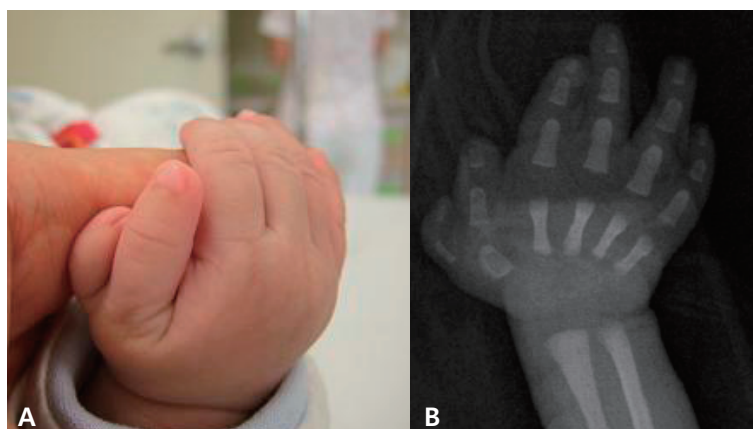


Fig. 2. The right thumb of the patient shows preaxial polydactyly with ulnar deviation.

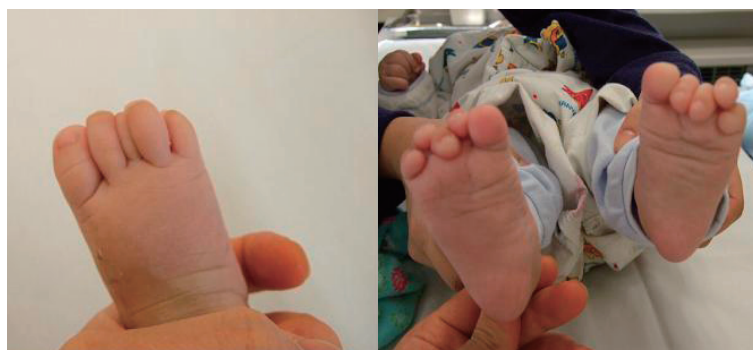

Fig. 3. The 2nd and 4th toes overlap the 3rd and 5th toe clinodactyly in the patient with Townes-Brocks syndrome (TBS).

suggested the possibility of TBS (Fig. 5). Mutation analysis of exons 1, 2, and 3 of *SALL1* gene in the 16q12.1 was performed on the patient and his mother, which showed a heterozygous single base pair deletion at nucleotide position 1470 (c.1470delG) in exon 2

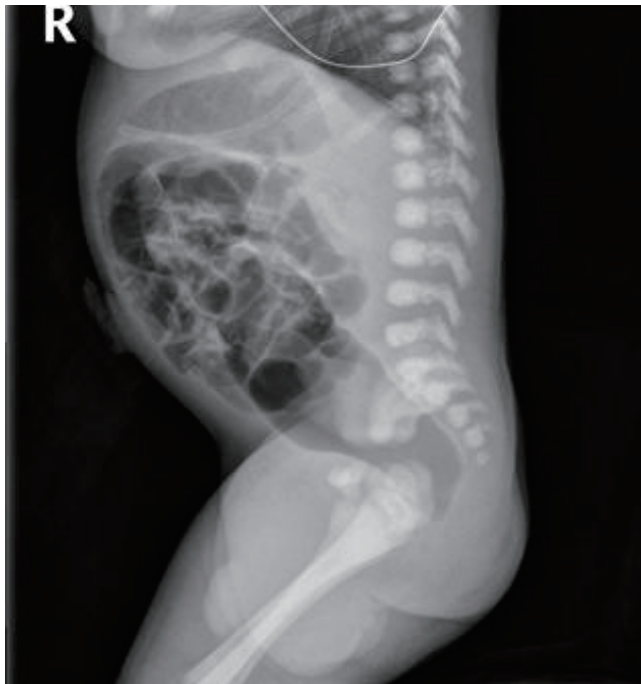

Fig. 4. Simple abdomen at birth shows dilation of the descending and rectosigmoid colon, but no gas is seen in the distal rectum.

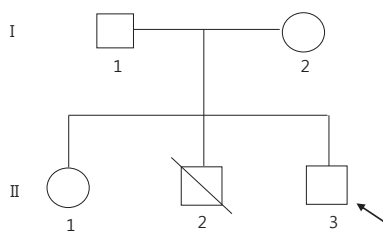


Fig. 5. Pedigree of the family shows vertical transmission of Townes-Brocks syndrome (TBS).

(Fig. 6) which represents a novel *SALL1* mutation. This deletion is predicted to cause a frameshift mutation, leading to a truncated *SALL1* protein. The parents were against mutation analysis for TBS on their 4-year-old daughter.

Discussion

Townes-Brocks syndrome (TBS) is a rare autosomal dominant multiple malformation syndrome with clinical variability within and between affected families. Characteristic features suggested for TBS include the following: anorectal abnormalities (imperforate anus), abnormalities of the hands (preaxial polydactyly, triphalangeal thumbs), abnormalities of the feet (syndactyly, club foot), deformities of the outer ear ("lop ears") and preauricular tags, and sensorineural hearing loss⁵. Other reported anomalies include congenital heart defects (VSD, TOF)^{6,7}, genitourinary abnormalities (impaired renal function or renal failure, hypoplastic or multicystic kidney, posterior urethral valve, vesicoureteral reflux), hypothyroidism, meatal stenosis^{8,9}, and rarely eye abnormalities (colobomata, aniridia) may be associated. Due to the involvement of multiple organ systems, early recognition of the disorder, appropriate medical management, and genetic counselling of the syndrome is critical. To the best of our knowledge, five cases of TBS have thus been reported to be associated with hypothyroidism^{5,10-13}. Although thyroid function test is included in the routine neonatal screening test, the result of the test should be reconfirmed in TBS patients.

As features of TBS frequently overlap those seen in other genetic syndromes, TBS may considerably have been misdiagnosed as other genetic disorders. TBS patients may have hand malformation or radial bone abnormalities, but no structural vertebral abnormalities or tracheo-esophageal fistula. VACTERL association may have vertebral abnormalities and tracheo-esophageal fistula, but no ear anomalies or deafness¹⁴⁻¹⁶. Baller-Gerold syndrome usually presents

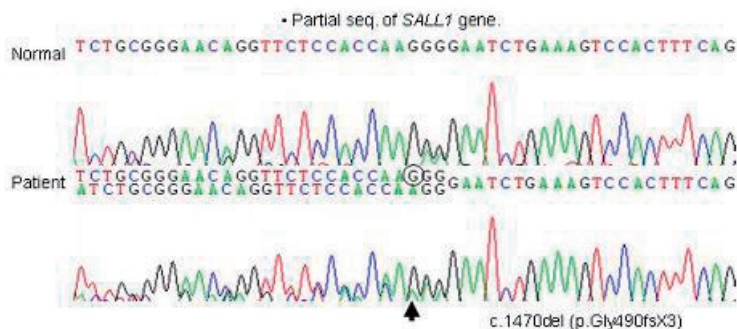


Fig. 6. Mutation analysis of the *SALL1* gene in the patient shows a single base pair deletion at nucleotide position 1470 (c.1470delG) in exon 2. The same type of mutation was found in his mother.

with craniosynostosis and thumb anomalies but no hypoplastic thumb¹⁷⁾. Cat eye syndrome has tracheo-esophageal fistula and vertebral anomalies but no thumb anomalies¹⁴⁾.

TBS is caused by a dominantly inherited defect in the gene encoding the *SALL1* putative transcription factor, a protein possibly required for urological, renal, limb, ear, brain, and liver development¹⁷⁾. *SALL1* gene is located on 16q12.1 and comprises three exons encoding a zinc finger protein thought to act as a transcriptional repressor. Mutations in *SALL1* result in prematurely terminated *SALL1* protein with loss of all double zinc-finger domains presumably essential for gene function. More than 56 mutations in the *SALL1* gene have been identified in patients with Townes-Brocks syndrome. *SALL1* mutations have been found in 64.3-83.3% of patients with typical signs of TBS, the majority of which are frame-shift mutations⁵⁾.

The patient with Townes-Brocks syndrome associated with congenital hypothyroidism in this report was confirmed to have a novel single base pair deletion at nucleotide position 1470 (c.1470delG) in exon 2 of *SALL1* gene, resulting in a frameshift mutation which was inherited from his mother.

Acknowledgment

Mutation analysis was supported by a grant of the Korea Healthcare Technology R&D Project, Ministry of Health, Welfare and Family Affairs, Korea (Grant No. A080588).

References

- 1) Aylsworth AS. Anus-hand-ear syndrome. In: Buyse ML, editor. Birth defects encyclopaedia. Dover: Blackwell Scientific Publications, 1990;155.
- 2) Cameron TH, Lachiewicz AM, Aylsworth AS. Townes-Brocks syndrome in two mentally retarded youngsters. *Am J Med Genet* 1991;41:1-4.
- 3) Ishikiriyama S, Kudoh F, Shimojo N, Iwai J, Inoue T. Townes-Brocks syndrome associated with mental retardation. *Am J Med Genet* 1996; 61:191-2.
- 4) Kohlhase J, Wischermann A, Reichenbach H, Froster U, Engel W. Mutations in the *SALL1* putative transcription factor gene cause Townes-Brocks syndrome. *Nat Genet* 1998;18:81-3.
- 5) Kohlhase J, Taschner PE, Burfeind P, Pasche B, Newman B, Blanck C, et al. Molecular analysis of *SALL1* mutations in Townes-Brocks syndrome. *Am J Hum Genet* 1999;64:435-45.
- 6) König R, Schick U, Fuchs S. Townes-Brocks syndrome. *Eur J Pediatr* 1990;150:100-3.
- 7) Parent P, Bensaïd M, Le Guern H, Colin A, Broussine L, Chabarot A, et al. Clinical heterogeneity of Townes-Brocks syndrome. *Arch Pediatr* 1995;2:551-4.
- 8) Kurnit DM, Steele MW, Pinsky L, Dibbins A. Autosomal dominant transmission of a syndrome of anal, ear, renal, and radial congenital malformations. *J Pediatr* 1978;93:270-3.
- 9) de Vries-Van der Weerd MA, Willems PJ, Mandema HM, ten Kate LP. A new family with the Townes-Brocks syndrome. *Clin Genet* 1988;34:195-200.
- 10) Yano S, Watanabe Y, Yoshino M. Townes-Brocks and Pendred syndrome in the same patient. *Am J Med Genet* 1998;77:330-1.
- 11) Botzenhart EM, Green A, Ilyina H, König R, Lowry RB, Lo IF, et al. *SALL1* mutation analysis in Townes-Brocks syndrome: twelve novel mutations and expansion of the phenotype. *Hum Mutat* 2005;26:282.
- 12) Goswami V, Dubey NK. Townes-Brocks syndrome with hypothyroidism. *Indian Pediatr* 2007;44:140-2.
- 13) Park SY, Lee WR. Townes-Brocks syndrome associated with hypothyroidism in a Korean newborn : a case report. *J Genet Med* 2008;5:136-8.
- 14) Say B, Gerald PS. A new polydactyly/imperforate-anus/vertebral-anomalies syndrome. *Lancet* 1968;2:688.
- 15) Powell CM, Chandra RS, Saal HM. PHAVER syndrome: an autosomal recessive syndrome of limb pterygia, congenital heart anomalies, vertebral defects, ear anomalies, and radial defects. *Am J Med Genet* 1993;47:807-11.
- 16) Jones KL. Smith's recognizable patterns of human malformation. 5th ed. Philadelphia, PA: WB Saunders Co, 1997;430.
- 17) Kohlhase J, Wischermann A, Reichenbach H, Froster U, Engel W. Mutations in the *SALL1* putative transcription factor gene cause Townes-Brocks syndrome. *Nat Genet* 1998;18:81-3.