

A case report of an esthetic prosthesis using zirconia restorations in combination with a ridge preservation procedure

Morihiro MIYAMAE, DDS^{1,2}, Takashi NAKAMURA, DDS, PhD²

¹Senri Perio Implant Center

²Department of Fixed Prosthodontics, Osaka University Graduate School of Dentistry

○ Introduction

All-ceramic restorations result in an excellent visual appearance, closely reproducing that of natural teeth. These restorations are free both clinician and patient from concerns about the occurrence of an allergic reaction, because they are made entirely of ceramic materials. These materials also provide such superb physical properties as biocompatibility, good color matching and translucency. Recently, all-ceramic restorations using crowns and fixed partial dentures with a zirconia frame have become widely used in clinical applications. Before the advent of zirconia, glass ceramics or alumina were used as all-ceramic restoration materials, but they could not be used for posterior fixed partial dentures, chiefly because of their poor mechanical strength. On the other hand, zirconia has more than twice as much mechanical strength and fracture toughness as alumina, and thus it has been proposed that this material can also be used for posterior fixed partial denture frames as well as anterior ones.¹ Actually, it has been reported that the clinical prognosis for zirconia fixed partial dentures includes almost no fracturing of the zirconia frame, although some veneered porcelains have caused fractures or chipping.^{2,3}

However, when engaged in improving the esthetics of dentition with crowns or fixed partial dentures, adjustment of the color and shape of the replacement teeth themselves using ceramics is insufficient. It is also necessary to consider the shape and color of the gingiva. In particular, if the alveolar ridge is not properly cared for after extraction of a tooth, bone absorption takes place. This impairs esthetics and makes satisfactory oral hygiene difficult after the placement of the fixed partial denture. Therefore, the clinician must be concerned with ridge preservation, or a procedure for preserving the post-extraction sockets to the extent possible.

In this case report, we describe the treatment of a person whose esthetics were restored with zirconia crowns and a fixed partial denture after extraction of a tooth, followed by a ridge preservation procedure.

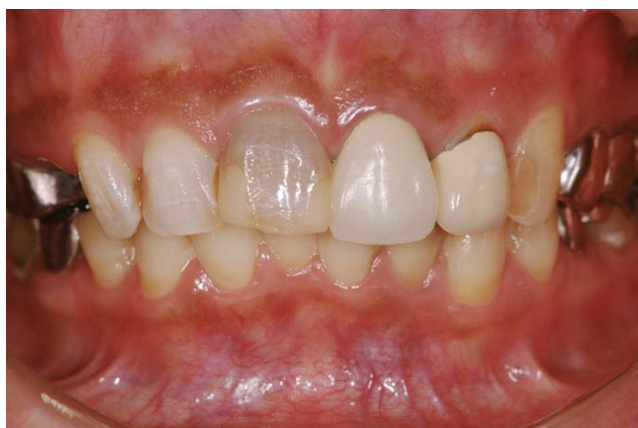

Fig. 1. Frontal view of the 39-year-old patient. Her chief complaint is discoloration of maxillary anterior teeth.

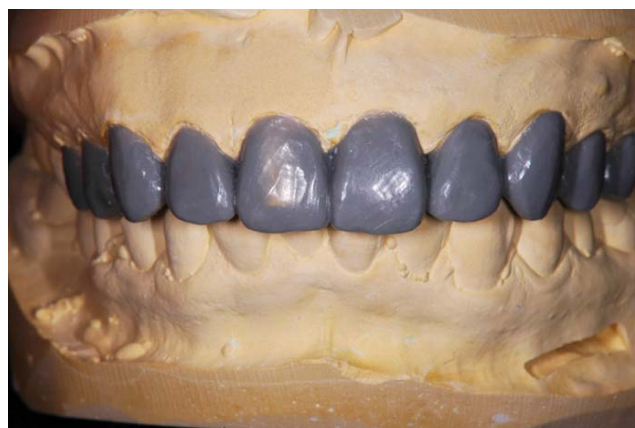

Fig. 2. A diagnostic wax-up is made. The shapes of teeth and gingival tissues were confirmed with the diagnostic wax-up.

Case report

The patient was a 39-year-old female. She visited us complaining of discoloration of her maxillary anterior teeth (Fig. 1). Her maxillary left central incisor and lateral incisor had improperly fitted crowns that were unnaturally whitish in color, and maxillary left premolars with metal crowns in place. The other maxillary anterior teeth were discolored. In addition, the maxillary right first premolar was root-fractured and thus needed to be extracted. Furthermore, she had a "gummy" smile and had various problems with her smile line, such as an uneven crown shape. Prior to starting the procedure, a diagnostic wax-up was prepared so we could consider the post-operative tooth shape (Fig. 2). This diagnostic wax-up confirmed that the implementation of prosthetic treatment of some anterior teeth and premolars would improve the smile and cervical lines.

As a treatment plan, it was decided to extract the maxillary right first premolar and treat that area with a 3-unit fixed partial denture, and to treat the other anterior teeth and premolar with crowns. It is desirable to use the same material, to facilitate matching the colors of the crowns and of the fixed partial denture. Therefore, we decided to use the zirconia system for both.

First, the improperly fitted anterior crown and left premolar metal crown were removed and then provisional crowns were put in place. The maxillary right first premolar was extracted and a ridge preservation procedure was performed by putting freeze-dried bone allograft (FDBA) in the post-extraction socket (Fig. 3). In addition, since the maxillary anterior teeth had pigmentation along the gingiva, this pigmentation was removed using phenol and ethanol (Figs. 4-6).

Four months after the initial treatment, abutment teeth were prepared and new provisional restorations were put in place (Figs. 7-9). Core buildup of the non-vital tooth was performed using a fiber post and composite resin. Since the cervical positions of the right and left central incisors were asymmetric, the excision of the cervical gingiva of the left central incisor using an electric cauter, or a gingivectomy, was performed.

After confirming the dentition contour using provisional restorations, the definitive zirconia crowns and a fixed partial denture were put in place (Figs. 10, 11). The color and shape of the anterior teeth were so improved that the patient was quite satisfied with her new smile line (Figs. 12-14). At present, more than one year has passed since the patient received the treatment. The prognosis is good, with no gingival recession observed.

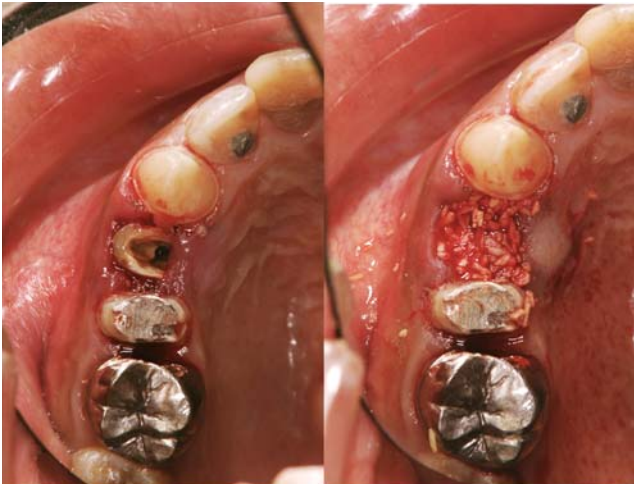

Fig. 3. After the extraction of the first premolar, a ridge preservation procedure was performed by putting FDDB in the post-extraction socket.

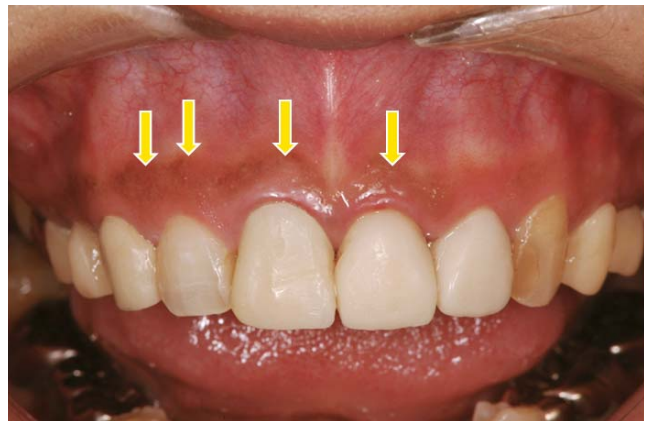


Fig. 4. Pigmentation (arrow) was observed in the anterior labial gingiva.

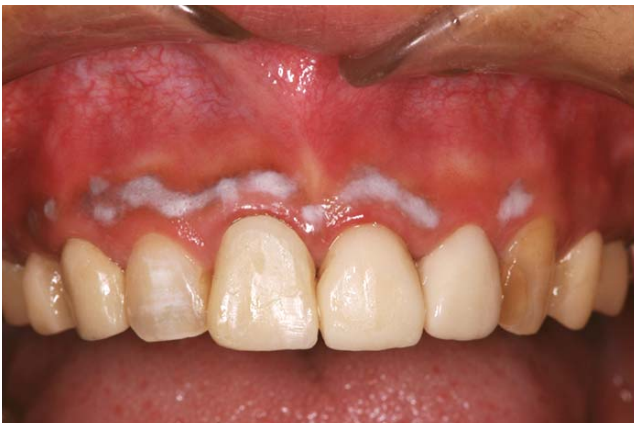

Fig. 5. Removal of pigmentation by using phenol and ethanol.

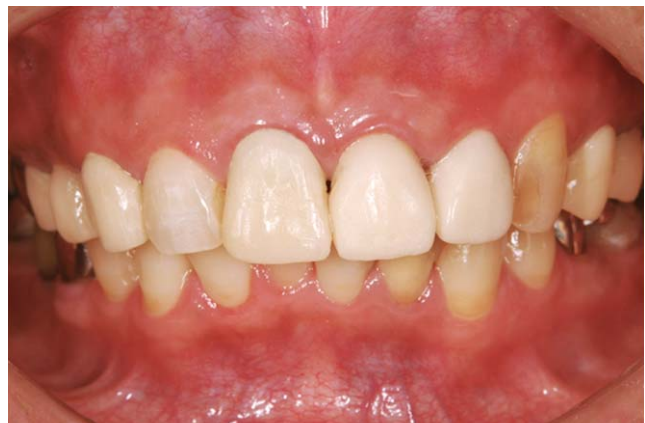

Fig. 6. 2 weeks after the removal of pigmentation.

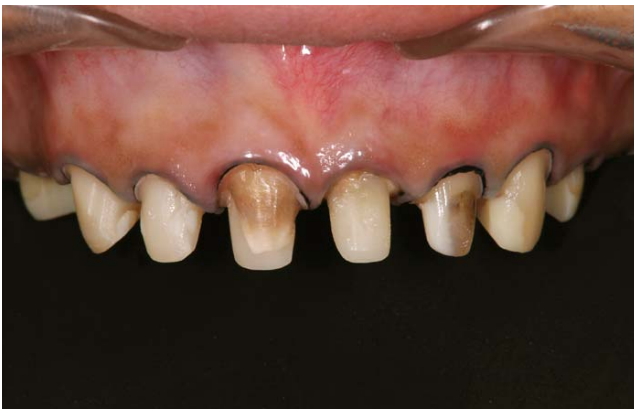

Fig. 7. Abutment teeth after preparation. Some discolored abutment teeth were observed.

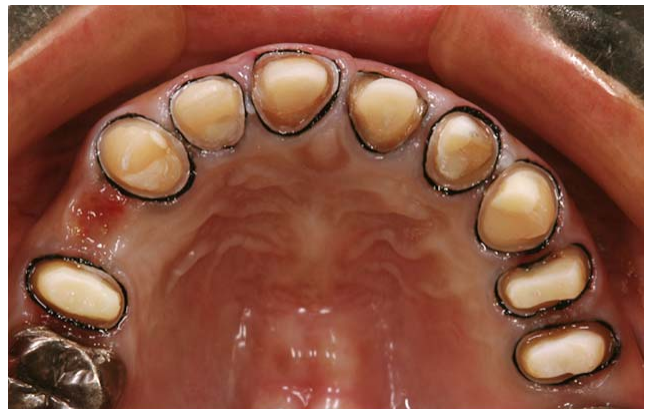

Fig. 8. Occlusal view of abutment teeth. In case of the non-vital tooth, a fiber post and composite resin core were used.

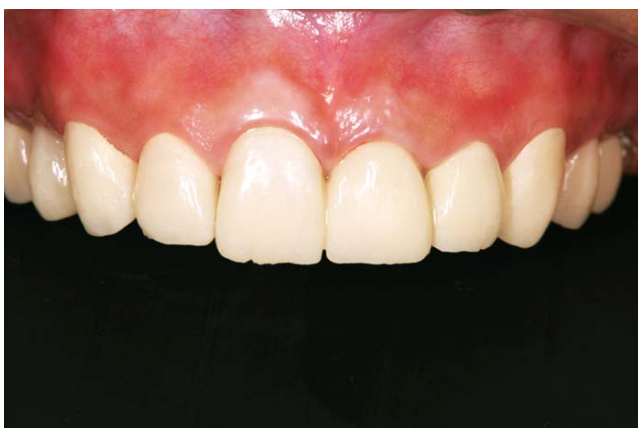

Fig. 9. Second provisional restorations. Because the cervical positions of the right and left central incisors were asymmetric, a gingivectomy is conducted.

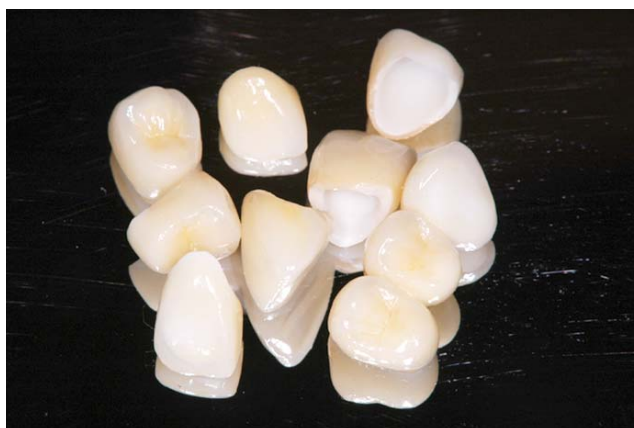

Fig. 10. Definitive crowns and a fixed partial denture fabricated by zirconia framework (Lava, 3M).

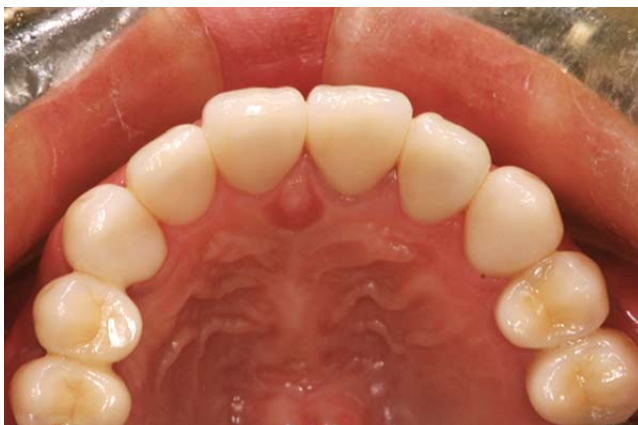

Fig. 11. Occlusal view after treatment.

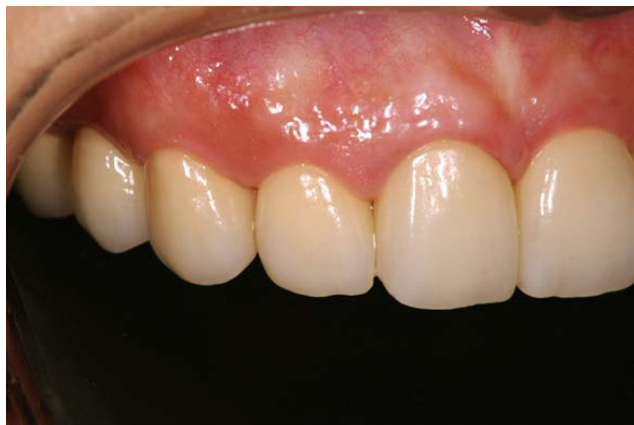

Fig. 12. Right lateral view after treatment.

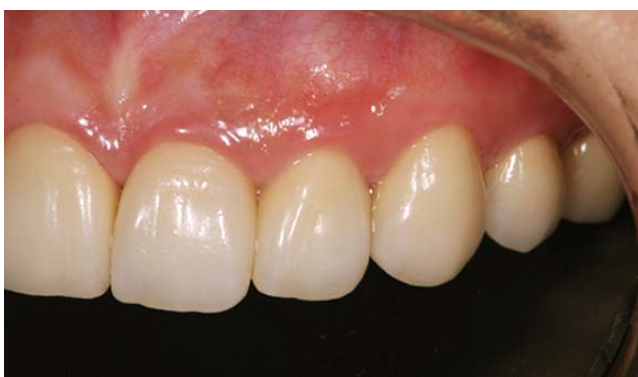

Fig. 13. Left lateral view after treatment.

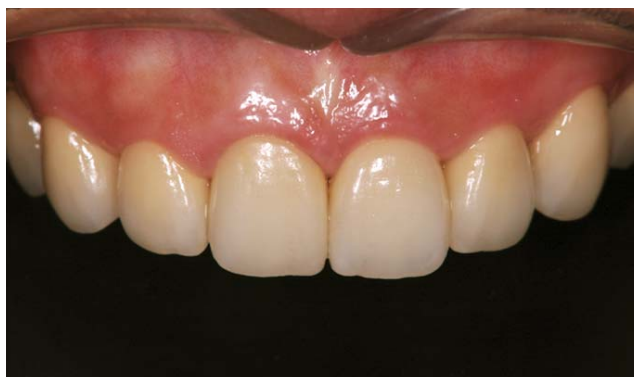

Fig. 14. Frontal view of the patient after treatment. The patient was quite satisfied with her new smile line.

Discussion

Zirconia frames have excellent mechanical strength and fracture resistance, so they can be used to fabricate fixed partial dentures. Thus they are especially useful for treatment when patients need to receive crowns and fixed partial dentures during the same treatment sequence. Furthermore, since zirconia is not as translucent as glass ceramics, the appearance of zirconia frame is not very much affected by the color of the abutment tooth.⁴ The patient described in this case report had some discolored abutment teeth. Therefore, crowns and a fixed partial denture using zirconia frames were used to treat her, since they do not tend to be affected by the color of the abutment.

There are a variety of reasons for discoloration along the gingiva. Above all, gingival staining due to deposits of melanin pigment is the most frequently encountered type.⁵ The gingiva of the patient in question seemed to be discolored due to the deposit of melanin pigment, as well; this was removed using medication (phenol and ethanol). This is a relatively easy procedure and the patient does not experience too heavy a burden during the process.

A ridge preservation procedure was performed using FDBA to preserve the post-extraction socket. It has been reported that this is an effective way to preserve bone.⁶ In this instance, the prosthetic procedure was performed four months after the surgery. No great amount of bone absorption was observed thereafter, suggesting that ridge preservation using FDBA was effective.

In order to achieve a highly esthetic treatment outcome, it is necessary to both use an all-ceramic restoration and also to consider the color and shape of the gingiva, as described in this case report.

References

1. Guazzato M, Albakry M, Ringer SP, Swain MV. Strength, fracture toughness and microstructure of a selection of all-ceramic materials. Part 2. Zirconia-based dental ceramics. *Dent Mater* 2004; 20: 449-456.
2. Sailer I, Feher A, Filser F, Gauckler LJ, Hammerle CH. Five-year clinical results of zirconia frameworks for posterior fixed partial dentures. *Int J Prosthodont* 2007; 20: 383-388.
3. Roediger M, Gersdorff N, Huels A, Rinke S. Prospective evaluation of zirconia posterior fixed partial dentures: four-year clinical results. *Int J Prosthodont* 2010; 23: 141-148.
4. Chen YM, Smales RJ, Yip KH, Sung WJ. Translucency and biaxial strength of four ceramic core materials. *Dent Mater* 2008; 24: 1506-1511.
5. Melei M, Vescovi P, Mooi WJ, van der Waal I. Pigmented lesions of the oral mucosa and perioral tissues: a flow-chart for the diagnosis and some recommendations for the management. *Oral Surg Oral Med Oral Oathol Oral Radiol Endod* 2008; 105: 606-616.
6. Allegrini S Jr, Koenig B Jr, Allegrini MR, Yoshimoto M, Gederange T, Fanghaenel J, Lipski M. Alveolar ridge sockets preservation with bone grafting – review. *Ann Acad Med Stetin* 2008; 54: 70-81.