

## Case Report

# Fibrous Dysplasia with Aneurysmal Bone Cyst Presenting as Painful Solitary Skull lesion

Jung Won Lee, M.D.,<sup>1</sup> Jae Hoon Kim, M.D.,<sup>1</sup> Seung Hoon Han, M.D.,<sup>2</sup> Hee In Kang, M.D.<sup>1</sup>

*Department of Neurosurgery,<sup>1</sup> Eulji University Eulji Hospital, Seoul, Korea*

*Department of Rehabilitation,<sup>2</sup> Hanyang University Guri Hospital, Guri, Korea*

We report a rare case of fibrous dysplasia with the development of a secondary aneurysmal bone cyst presenting as solitary tumor of calvarium. Although fibrous dysplasia with aneurysmal bone cyst is rare, it should be taken into account in differential diagnosis of the osteolytic solitary skull lesion.

**KEY WORDS :** Aneurysmal bone cyst · Fibrous dysplasia · Skull.

## INTRODUCTION

Fibrous dysplasia (FD) is a benign skeletal disorder, first described by Lichtenstein, in which abnormal development of fibroblast replaces medullary bone with fibrocellular tissue<sup>6,9,14</sup>. Among them, craniofacial FD represents approximately 7% of benign bone tumors<sup>7</sup>. The three most common radiological features of FD are pagetoid, sclerotic, and cystic patterns<sup>8</sup>. Computed tomographic (CT) scans show widening of diploic spaces, osseous expansion, and ground glass opacity<sup>12</sup>. Magnetic resonance image (MRI) reveals typically low signal intensity on T1- and T2-weighted images with contrast enhancement<sup>2</sup>.

Aneurysmal bone cyst (ABC) is an expanding osteolytic lesion superimposed on an existing pathological process of the bone<sup>11</sup>. ABC appears on plain X-rays as an ovoid lesion with varying degrees of diploic expansion or cortical thinning<sup>11</sup>. CT scan reveals an expansile bony cyst and MRI demonstrates high signal intensity on T1-weighted images, indicating hemorrhagic transformation<sup>5,11</sup>. On histopathology, ABC appears as blood-filled cavernous spaces with a paucity of endothelial cells. The cysts are separated by septa

composed of fibrous tissue, which contain multinucleated giant cells and osteoid tissue<sup>3</sup>. ABC involves most commonly in the vertebrae and long bone. However, only a few cases of ABC affecting the calvarium have been reported. Moreover, the occurrence of a concomitant FD and ABC in calvarium is exceedingly rare. In the search of literature using Medline, only 10 cases including our report were retrieved<sup>1,10,13,16,18,20</sup> (Table 1). Although the mechanism of the occurrence of FD with ABC is unknown, there is a report that a secondary form of ABC may arise from a disruption in the osseous circulation caused by primary lesion<sup>4</sup>.

Here, we report a rare case of FD in combination with ABC on the frontoparietal bone presenting as rapidly growing solitary scalp mass with review of literature.

## CASE REPORT

This 18-year-old girl presented with painful scalp mass on the right frontoparietal region, 3 cm in diameter. She had no specific medical history and her general condition was good. She experienced severe headache of abrupt-onset 10 days ago and noticed a newly developed scalp mass on the right frontoparietal region. Physical examination was normal except for a bulging, tender scalp mass on the right frontoparietal region. She was neurologically intact. Routine laboratory data, including serum calcium, phosphorus, and alkaline phosphatase, were within normal limits.

A plain skull X-ray revealed an irregular osteolytic lesion

• Received : July 15, 2010 • Revised : September 3, 2010

• Accepted : December 21, 2010

• Address for reprints : Jae Hoon Kim, M.D.

Department of Neurosurgery, Eulji University School of Medicine,  
280-1 Hageye1-dong, Nowon-gu, Seoul 139-711, Korea

Tel : +82-2-970-8268, Fax : +82-2-979-8268

E-mail : grimi2@hanmail.net

involving skull vault (Fig. 1). Brain computed tomography scans showed approximately 2.5 cm sized, lobulated, osteolytic lesion over the right frontoparietal bone (Fig. 2). The center of the lesion was eccentric to the calvaria. As a consideration of her age and radiographic findings, it was initially regarded to be an eosinophilic granuloma involving skull. Plain X-rays and radionuclide bone scan were taken for other long bones and vertebrae for seeking evidence of histiocytosis, but there were no osteolytic bone lesions other than calvarial one.

During operation, a dark hemorrhagic cystic lesion was attached to the subcutaneous tissue and had completely eroded the inner and outer tables of skull, but there was no evidence of invasion of the dura. At the margins of the lesion, the skull was thickened and gritty in an area 1 to 1.5 cm around the lesion. En-bloc resection of the bony lesion including surrounding healthy bone enough to clear resection margin and curettage of the soft tissue involvement were performed. The cranial defect was repaired with the molded methyl methacrylate plate. After operation, no neurological

deficit was found and a good cosmetic result was achieved.

On histopathological examination, the two different components were noted. The tissue removed from the solid component was composed of overgrowth of fibrous matrix and haphazardly scattered bony trabeculae characteristic of FD (Fig. 3). And, tissue removed from the cystic component showed cystic spaces containing red blood cells separated by septa containing spindle cell and multinucleated giant cells characteristic of ABC (Fig. 4). The final pathologic findings were consistent with FD in combination with ABC.

### DISCUSSION

FD with ABC presenting with solitary calvarial lesion is an extremely rare entity. This lesion is first reported by Branch<sup>1)</sup> in 1986. The primary diseases known to be associated with ABC are osteoclastoma, osteosarcoma, osteoblastoma and hemangioma<sup>1)</sup>. The report of ABC associated with FD is very rare, and moreover, the occurrence in skull vault is even rarer. Martinez et al.<sup>15)</sup> found only one case (2.4%) of ABC

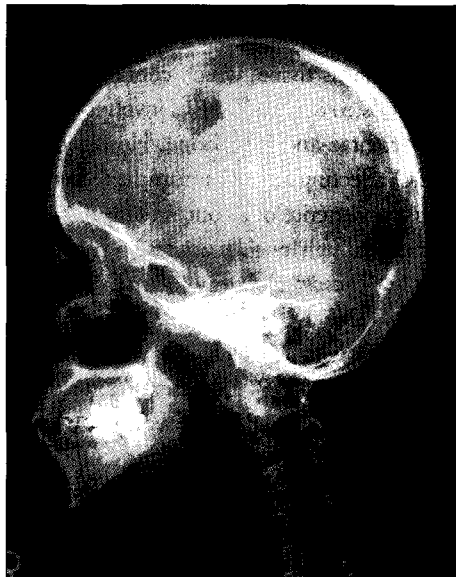


Fig. 1. Plain roentgenogram of the skull, lateral view, showing a lobulated osteolytic lesion on the right frontoparietal skull.




Fig. 2. Computerized tomographic scans (A) with bone setting (B) revealing an osteolytic lesion with erosion of the inner and outer skull tables and expansion of the diploic space in the right frontoparietal area.



Fig. 3. Photomicrograph demonstrating abundant fibrous stroma and irregularly arranged woven bone spicules revealing no conspicuous rimming consistent with fibrous dysplasia (H&E stain, original magnification  $\times 20$ ).



Fig. 4. Photomicrograph showing blood filling cavernous space surrounded by multinucleated osteoclastic giant cells, proliferating fibroblasts and capillaries (H&E stain, original magnification  $\times 200$ ).

in the 42 patients with FD. All the cases of calvarial FD with ABC retrieved by Medline search in literature have been reviewed and are summarized in Table 1.

On the analysis of the reported 9 cases, the most common clinical feature is expanding mass on the scalp with or without pain during a short period. The nature of rapid growth may come from the malignant change of FD. However, FD is a benign disease, even though malignant transformation has been reported in 0.5% of patients with monostotic FD and in 4% of polyostotic FD<sup>19</sup>. Therefore, the possibility of ABC transformation or abrupt cystic hemorrhage should be considered especially in patients who are younger than 20 years old. The most common radiological appearance of ABC transformation is the osteolytic lesion involving the inner and outer table of skull and expansion of the diploic space. The fluid-fluid level may suggest intracystic hemorrhage<sup>11</sup>.

On histopathology, FD with ABC has two components. FD component is irregular bony trabeculae with varying number of fibroblasts. ABC component is blood-filled cavernous space surrounded by multinucleated giant cells<sup>10</sup>.

The differential diagnosis of solitary osteolytic skull lesion includes hemangioma, epidermoid cyst, and eosinophilic granuloma<sup>17</sup>. Skull hemangioma is usually solitary lytic diploic space lesions. Hemorrhagic transformation can be seen on magnetic resonance images. Epidermoid cyst involves both the inner and outer tables and is well-defined lesions that lack central trabeculae and have a sclerotic rim. On the other hand, eosinophilic granulomas are round or oval non-sclerotic skull lesion with sharply defined margins. However, the differential diagnosis of these lesions is difficult on the radiological findings, confirmation by histopathologic finding is essential.

In review of the literature, the treatment of choice for FD

with ABC is en-bloc resection and cranioplasty. Also, close follow-up to the resected lesion is recommended. In selected cases, preoperative embolization can be helpful to perform the excision with minimal blood loss<sup>10</sup>.

## CONCLUSION

We report a rare case of FD with secondary hemorrhage from ABC. Although this disease entity is very rare, we should take it consideration in differential diagnosis of osteolytic calvarial lesions when the characteristic fluid-fluid level on CT scans and rapidly growing scalp mass is presented.

## References

1. Branch CL, Challa VR, Kelly DL : Aneurysmal bone cyst with fibrous dysplasia of the parietal bone. reports of two cases. *J Neurosurg* 64 : 331-335, 1986
2. Brown EW, Megerian CA, McKenna MJ, Roos RA : Fibrous dysplasia of the temporal bone. *Am J Roentgenol* 165 : 679-682, 1995
3. Burger PC, Scheithauer BW, Vogel FS : *Surgical pathology of the nervous system and its coverings*, ed 3. Edinburgh : Churchill Livingstone, 1991, pp 1-17
4. Caccac MA, Malis LI, Anderson PJ : Aneurysmal parietal bone cyst. Case report. *J Neurosurg* 37 : 237-241, 1972
5. Calliauw L, Roels H, Caemaert J : Aneurysmal bone cysts in the cranial vault and base of skull. *Surg Neurol* 23 : 193-198, 1985
6. Casselman JW, De Jonge I, Neyt L, De Clercq C, D'Hont G : MRI in craniofacial fibrous dysplasia. *Neuroradiol* 35 : 234-237, 1993
7. Edgerton MT, Persing JA, Jane JA : The surgical treatment of fibrous dysplasia : With emphasis on recent contributions from craniomaxillofacial surgery. *Ann Surg* 202 : 459-479, 1985
8. Fries JW : The roentgen features of fibrous dysplasia of the skull and facial bone. *Am J Roentgenol* 77 : 71-76, 1957
9. Ha SK, Park JY, Kim SH, Lim DJ, Park YK, Chung YK, et al. : Fibrous dysplasia involving the fronto-orbital bone: surgical experience. *J Korean Neurosurg Soc* 34 : 23-26, 2003
10. Itshayek E, Spector S, Gomori M, Segal R : Fibrous dysplasia in combination with aneurysmal bone cyst of the occipital bone and the clivus: case report and review of the literature. *Neurosurgery* 51 : 815-

**Table 1.** Summary of published cases of fibrous dysplasia in combination with aneurysmal bone cyst presenting with solitary lesion of calvarium

| Author/Year        | Sex/age | Symptom                                  | Duration of symptom | Location                  | CT findings                                                                                            |
|--------------------|---------|------------------------------------------|---------------------|---------------------------|--------------------------------------------------------------------------------------------------------|
| Branch CL, 1986    | F/9     | Expanding painful mass / Painless mass   | 1 month / 2 years   | Parietal / Frontotemporal | Large area of bone lysis with erosion of the inner and outer tables and expansion of the diploic space |
| Branch CL, 1986    | M/19    | Painless mass                            | 4 weeks             | Parietal                  | Cystic expansion of the skull and soft tissue mass with an abnormal rim of contrast enhancement        |
| Rappaport ZH, 1989 | M/25    | Painless mass                            | Unknown             | Occipital                 | Intradiploic hypodense lesion                                                                          |
| Wojno KJ, 1994     | F/14    | Painless mass                            | Unknown             | Temporal                  | heterogeneous cystic lesion                                                                            |
| Wojno KJ, 1994     | M/40    | Expanding mass                           | Unknown             | Frontal                   | Diffuse thickening of the calvarium and cystic lesion with septation                                   |
| Itshayek E, 2002   | M/19    | Expanding painless mass                  | Unknown             | Occipital                 | Expanded diploic space with ground glass appearance                                                    |
| Lin WC, 2004       | M/18    | Expanding painful mass                   | 2 weeks             | Frontal                   | Cystic degeneration and multiple cavities with internal fluid-fluid level                              |
| Mattei TA, 2005    | F/19    | Headache, nuchal rigidity, Painless mass | Unknown             | Occipital                 | Subarachnoid hemorrhage and diploic cyst with fluid-fluid level                                        |
| Lee JW, 2010       | F/18    | Expanding painful mass                   | 10 days             | Frontoparietal            | Osteolytic lesion and expansion of the diploic space                                                   |

- 818, 2002
11. Kransdorf MJ, Sweet DE : Aneurysmal bone cyst : concept, controversy, clinical presentation, and imaging. *Am J Roentgenol* 164 : 573-580, 1995
  12. Laine FJ, Kuta AJ : Imaging of sphenoid bone and basiocciput : pathological consideration. *Semin Ultrasound CT MR* 14 : 160-177, 1993
  13. Lin WC, Wu HT, Wei CJ, Chang CY : Aneurysmal bone cyst arising from fibrous dysplasia of the frontal bone. *Eur Radiol* 14 : 930-932, 2004
  14. Lichtenstein L : **Bone tumors**, ed 5. St Louis : CV Mosby, 1977, pp 403-422
  15. Martinez V, Sissons HA : Aneurysmal bone cyst. a review of 123 cases including primary lesions and those secondary to other bone pathology. *Cancer* 61 : 2291-2304, 1988
  16. Mattei TA, Mattei JA, Ramina R, Aguiar PH : Fibrous dysplasia in combination with aneurysmal bone cyst presenting as a subarachnoid haemorrhage. *Neurol Sci* 26 : 178-181, 2005
  17. Osborn AG : **Diagnostic Neuroradiology**, ed 1. St. Louis : Mosby, 1994, pp 516
  18. Rappaport ZH : Aneurysmal bone cyst associated with fibrous dysplasia of the skull. *Neurochirurgia* 32 : 192-194, 1989
  19. Ruggieri P, Sim FH, Bond JR : Malignancies in fibrous dysplasia. *Cancer* 73 : 1411-1424, 1994
  20. Wojno KJ, McCarthy EF : Fibro-osseous lesions of the face and skull with aneurysmal bone cyst formation. *Skeletal Radiol* 23 : 15-18, 1994