

## Clinical Article

# Comparative Study of Lumbar Magnetic Resonance Imaging and Myelography in Young Soldiers with Herniated Lumbar Disc

Suk-Hyung Kang, M.D.,<sup>1,2</sup> Seung Hong Choi, M.D., Ph.D.,<sup>3</sup> Nak Jong Seong, M.D.,<sup>3</sup> Jung Min Ko, M.D.,<sup>3</sup> Eun-Suk Cho, M.D.,<sup>3</sup> Kwang Pil Ko, M.D., Ph.D.<sup>4</sup>

*Department of Neurological Surgery,<sup>1</sup> Chung-Ang University College of Medicine, Seoul, Korea*

*Departments of Neurological Surgery,<sup>2</sup> Radiology,<sup>3</sup> The Armed Forces Capital Hospital, Seoul, Korea*

*Division of Epidemiology and Health Index,<sup>4</sup> Center for Genome Science, Korea National Institute of Health, Korea Centers for Disease Control and Prevention, Seoul, Korea*

**Objective :** This study was undertaken to compare the diagnostic performances of magnetic resonance imaging (MRI), MR myelography (MRM) and myelography in young soldiers with a herniated lumbar disc (HLD).

**Methods :** Sixty-five male soldiers with HLD comprised the study cohort. A visual analogue scale for low back pain (VAS-LBP), VAS for leg radiating pain (VAS-LP), and Oswestry disability index (ODI) were applied. Lumbar MR, MRM, and myelographic findings were checked and evaluated by four independent radiologists, respectively. Each radiologist was asked to score (1 to 5) the degree of disc protrusion and nerve root compression using modified grading systems devised by the North American Spine Society and Pfirrmann and the physical examination rules for conscription in the Republic of Korea. Correlated coefficients between clinical and radiological factors were calculated. Interpretational reproducibility between MRI and myelography by four bases were calculated and compared.

**Results :** Mean patient age was  $20.5 \pm 1.1$ . Mean VAS-LBP and VAS-LP were  $6.7 \pm 1.6$  and  $7.4 \pm 1.7$ , respectively. Mean ODI was  $48.0 \pm 16.2\%$ . Mean MRI, MRM, and myelography scores were  $3.3 \pm 0.9$ ,  $3.5 \pm 1.0$ , and  $3.9 \pm 1.1$ , respectively. All scores of diagnostic performances were significantly correlated ( $p < 0.05$ ). However, none of these scores reflected the severity of patients' symptoms. There was no statistical difference of interpretational reproducibility between MRI and myelography.

**Conclusion :** Although MRI and myelography are based on different principles, they produce similar interpretational reproducibility in young soldiers with a HLD. However, these modalities do not reflect the severity of symptoms.

**KEY WORDS :** Comparison study · Herniated Lumbar Disc · Interpretational reproducibility · Magnetic Resonance Imaging · MR Myelography · Myelography.

## INTRODUCTION

Magnetic resonance imaging (MRI), which replaced the myelography, is considered as a gold standard imaging method for the diagnosis of spinal disorders. However, in military medicine in the Republic of Korea, myelography also has been regarded as an important diagnostic tool. The purposes of this study were to compare MR and MR Myelography (MRM)

with myelography to determine which would reflect better the patient state and to compare their interpretational reproducibility using diagnostic images in young soldiers with a herniated lumbar disc (HLD). The authors hoped that the results of such a study would help the military administration to devise patient management guidelines.

## MATERIALS AND METHODS

From September 2007 to June 2008, 65 male in-patients with low back pain and associating leg radiating pain in one military hospital were enrolled in this study. All patients were male, in their early 20's, and soldiers. The patients with only low back pain, with an operative or pain intervention history,

• Received : June 1, 2010 • Revised : September 24, 2010  
• Accepted : December 27, 2010  
• Address for reprints : Suk-Hyung Kang, M.D.  
Department of Neurological Surgery, Chung-Ang University College of Medicine, Hangang-ro 3-ga, Yongsan-gu, Seoul 140-757 Korea  
Tel : +82-2-748-9565, Fax : +82-2-798-2818  
E-mail : nscharisma@hanmail.net

with spondylolysis or spondylolisthesis, with a tumor, with an infection, or with a fracture owing to trauma were excluded.

**Clinical findings of patients**

Visual analogue scale (VAS) for lower back pain (LBP), VAS for leg radiating pain (LP) and the Oswestry disability index (ODI) were applied as measures of clinical severity.

**Radiological factors**

As radiological factors, lumbar MRI, MRM, and myelography were checked and evaluated by four independent radiologists. For MRI and MRM, 1.5 Tesla systems (GE and Siemens) were used.

Regarding MRI, all patients were studied using axial T1 (TR/TE/NEX/FA, 616.7/10.3 ms/1.0/90°) and T2 (TR/TE/NEX/FA, 3050/111.1 ms/1.0/90°)-weighted images, and sagittal T1 and T2-weighted spin-echo images of the lumbar and sacral spines using a 28 × 28 cm Field of View (FOV) and 4 mm slice thickness (ST).

For MRM, all patients were studied using coronal section T2 gradient echo images with a 28 × 28 cm FOV, 1.6 mm ST, TR 4.5, TE 1.3, FA 45°, NEX 5. For myelography, an Allura Xper FD-20 (Philips Medical Systems, Best, Netherlands) for angiograph was used. Under the fluoroscope, 10 cc of water-soluble contrast (Visipaque®, GE Healthcare, Cork, Ireland) was injected into the intradural space of the L4/5 spinal canal. After 2-5 minutes in the sitting position, AP,

lateral, and both oblique views were taken. Finally, cine images were taken for accurate evaluation.

According to nomenclature of North American Spine Society (NASS), the grading system of Pfirrmann and the physical examination rules for conscription in the Republic of Korea, which provide information on relations between the nerve root and the protruding disc, each of the four independent radiologists provided a grade from 1 to 5 by reviewing MRI, MRM, and myelography<sup>7,16,17</sup>. Grade 1 was regarded as minimal root irritation, indicating disc bulging or protrusion without root irritation. Grade 5 represented as maximal root irritation, indicating complete root compression by the protrude disc materials. (Table 1, Fig. 1)

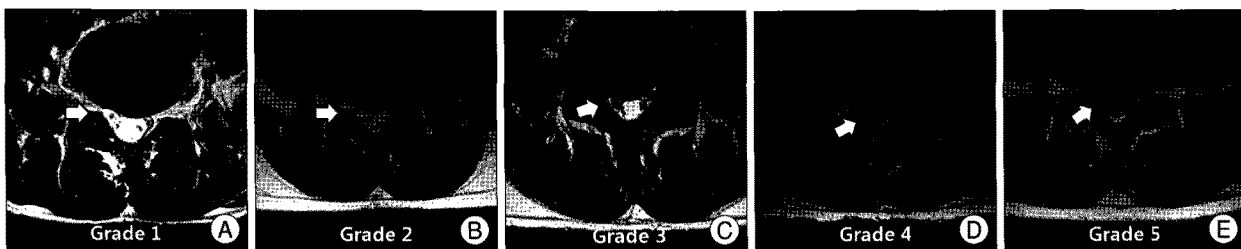
To compare the interpretational reproducibility of MRI, MRM, and myelography, four radiologists observed lumbar MRI, MRI, and myelography images, independently. The interpretational reproducibility was calculated and compared on the basis of four criterias; 1) The complete interobserver agreement rate (all interpretation were same)<sup>11</sup>, 2) concordant rate (more than 3 results were same), 3) one grade difference rate (all interpretational result were within 1 grade)<sup>11</sup> and 4) standard deviation of interpretational scores. With these bases, interpretational reproducibility was compared; MRI versus myelography and MRI with MRM versus myelography.

**Statistical analysis**

Statistical analysis was performed using correlation coeffi-

**Table1.** Interpretational scoring system for lumbar magnetic resonance imaging, MR myelogram and myelography

Score	MRI & MRM findings	Myelography findings
1	Disc bulging or protrusion without root contact	Thecal sac indentation without root contact and deviation
2	Disc bulging or protrusion with root contact	Thecal sac indentation with root contact but no deviation
3	Disc bulging or protrusion with root deviation	Thecal sac indentation with root deviation and no root compression
4	Disc bulging or protrusion with root compression and deviation, possible to decline root outline	Thecal sac indentation with partial root compression
5	Disc bulging or protrusion with complete root compression, impossible to decline root out line	Thecal sac indentation with complete root compression, showing positive cut-off sign



**Fig. 1.** Lumbar magnetic resonance imaging (MRI) findings based on the scoring system. A : Score 1 represents bulging or protrusion without root contact. High signal intensity around the root (arrow) implies no root irritation. B : Score 2 represents disc bulging or protrusion with root contact. The protruded disc contacts the root and the signal intensity around the root (arrow) is preserved. C : Score 3 represents disc bulging or protrusion with root deviation. Contrary to left, right root (arrow) is deviated, but the signal around the root is preserved. D : Score 4 represents disc bulging or protrusion with root compression and deviation. It is possible to decline root outline (arrow), which is compressed by protruded disc. E : Score 5 is represents disc bulging or protrusion with complete root compression. It is impossible to decline root out line (arrow), which is compressed by protruded disc.

**Table 2.** Correlation coefficients (Spearman's rho) between radiological and clinical factors

		AGE	VAS_LBP	VAS_LEG	ODI	MRI	MRM	Myelography
MRI	Correlation coefficient	-0.022	-0.094	0.130	-0.040	1.0	0.834	0.746
	<i>p</i> -value	0.864	0.454	0.301	0.753	0	0.000	0.000
MRM	Correlation coefficient	-0.034	-0.081	0.232	0.025	0.834	1.0	0.826
	<i>p</i> -value	0.786	0.520	0.063	0.842	0.000	0	0.000
CM	Correlation coefficient	-0.059	0.001	0.162	-0.097	0.746	0.826	1.0
	<i>p</i> -value	0.639	0.992	0.197	0.443	0.000	0.000	0

MRI : magnetic resonance image, VAS : visual analogue scale, LBP : low back pain, LEG : leg pain, ODI : Oswestry disability index, CC : Correlation coefficient

coefficients (Spearman's rho), Pearson's chi-square test, and the paired-t test. Statistical significance was accepted for *p* values of < 0.05.

## RESULTS

The 65 patients were all male soldiers in their early 20's. Mean patient age was 20.5 ( $\pm$  1.1). Mean lower back and leg radiating VAS pain scores were 6.7 ( $\pm$  1.6) and 7.4 ( $\pm$  1.7), respectively, mean ODI was 48.0 ( $\pm$  16.2) %. Mean MRI, MRM, and myelography scores were 3.3  $\pm$  0.9, 3.5  $\pm$  1.0 and 3.9  $\pm$  1.1, respectively.

No significant correlation was found between radiological and clinical factors. However, MRI, MRM, and myelography diagnostic interpretations were found to be significantly related (*p* = 0.000) (Table 2).

Complete interobserver agreement rates for MRI, MRM and myelography, were 6.2%, 15.4% and 35.4%, and the concordance rates (more than 3 of the 4 radiological interpretations were same) were 47.7%, 41.5%, and 61.5%, respectively. The one grade difference rates (all interpretational results were within 1 grade) were 53.8%, 57.0%, and 55.4% respectively. The standard deviations of interpretational score were 0.74  $\pm$  0.37, 0.66  $\pm$  0.40 and 0.62  $\pm$  0.58 respectively. In the point of interpretational reproducibility comparisons, there were no significant differences between MRI and myelography, and between MRI with MRM and myelography, respectively (Table 3, 4).

## DISCUSSION

Many patients suffer from lower back pain and associated radiating leg pain and this situation is not different in military medicine. Because of the various compensations in military medical situation, radiological findings are sometimes regarded as being more important than clinical findings, although radiological findings are not always correlated with

**Table 3.** The results of interpretational reproducibility comparison between lumbar magnetic resonance imaging and myelography

Standards	MRI	Myelography	<i>p</i> -value
Complete interobserver agreement	4 (6.2%)	23 (35.4%)	0.087*
Accordance over 3 radiologic interpretations	30 (46.2%)	40 (61.5%)	0.194*
Disagreement within 1 grade difference	35 (53.8%)	39 (55.4%)	0.128*
Standard deviation	0.74 $\pm$ 0.37	0.62 $\pm$ 0.58	0.098 <sup>†</sup>

\*Inter-group statistical significances were tested using Pearson's chi-square test, <sup>†</sup>Statistical significances were determined using the paired-t test

**Table 4.** The results of interpretational reproducibility comparison between lumbar magnetic resonance imaging with MR myelogram and myelography

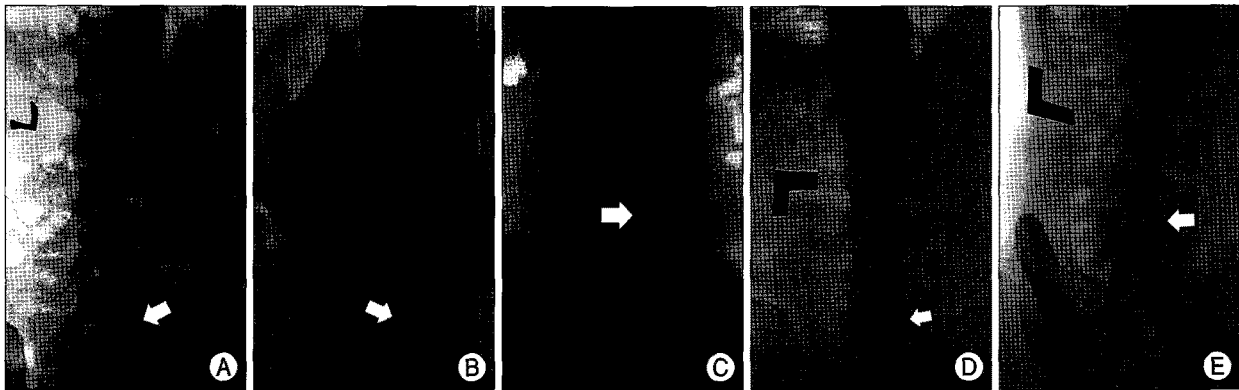
Standards	MRI + MRM	Myelography	P-value
Complete interobserver agreement	11 (16.9%)	23 (35.4%)	0.443*
Accordance over 3 radiologic interpretations	31 (47.7%)	40 (61.5%)	0.326*
Disagreement within 1 grade difference	43 (66.15%)	39 (55.4%)	0.087*
Standard deviation	0.62 $\pm$ 0.39	0.62 $\pm$ 0.58	0.992 <sup>†</sup>

\*Inter-group statistical significances weretested using Pearson's chi-square test, <sup>†</sup>Statistical significances were determined using the paired-t test. MRI : magnetic resonance image, MRM : magnetic resonance myelography

clinical findings<sup>2,13,14,20,21</sup>).

According to Military Manpower Administration, spinal disorders are not considered as a major disease for recruitment drafting systems. Currently, 26,000 individuals are performing a Public Interest Service as an alternative to military service, and of these about 700 are spinal patients. However, according to the Ministry of National Defense, about 4,000 young men are discharged from military service annually due to illness. Of these, 35% have a spinal disorder and herniated lumbar disc (HLD) is the most commonly encountered disease entity. Unfortunately, there are many cases of second gain which includes worker's compensation. We thought this is the reason why radiological findings are regarded more importantly than clinical symptoms in military medicine and Physical Examination System prior to conscription.

According to the physical examination rules for conscription in the Republic of Korea, physical state is divided into 6 groups and last two of these groups are exempted from enlistment. In cases with a spinal degenerative disease, three types warrant discharge from military service. These are : 1) a neurological emergent state and its sequelae, such as, cauda equina syndrome or foot drop; 2) spinal stenosis affecting more than 50% of the spinal canal; and 3) intervertebral disc



**Fig. 2.** Findings of lumbar myelography based on the scoring system. A : Score 1 is suggested in case with disc bulging or protrusion without root contact. The outline of root (arrow) is clear and contrast filling defect suggest thecal sac indentation owing to bulging or protruded disc. B : Score 2 is suggested in case with disc bulging or protrusion with root contact. The outline of root (arrow) is partially ambiguous, contrast filling defect suggest thecal sac indentation with root contact. However, there is no root deviation. C : Score 3 is suggested in case with disc bulging or protrusion with root deviation. The outline of root (arrow) is clear and angled. These finding suggest that root is deviated without root compression. D : Score 4 suggested in case with disc bulging or protrusion with root partial-compression and deviation. The outline of root is partially obscure and angled (arrow). These findings suggest root is deviated with partial root compression. The rest part of the root is visible. E : Score 5 is considered in case with disc bulging or protrusion with complete root compression. The outline of root is completely obscure, showing positive cut-off sign (arrow). These findings suggest complete root compression.

disease showing complete root compression by a herniated lumbar disc. Myelography is regarded as an important diagnostic tool as MRI in military medicine. Since most of spinal diseases in military medicine are HLD, myelography is sometimes regarded as a better diagnostic performance without any evidence.

In this study, we used 5-score system to evaluate the relationship between root and extruded disc materials, some part of the physical examination rules for conscription in the Republic of Korea was applied for the scoring system (Table 1). Basically, it was assumed that this grade could reflect the severity of HLD. Radiologic findings, however, could not reflect the clinical severity although such radiologic findings would be judged more objectively rather than clinical findings.

Due to on-going improvements in diagnostic performance, new diagnostic procedures are continuously replacing established procedures. For the diagnosis of spinal disorders, MRI and MRM are replacing myelography, because they are believed to be superior in terms of visualizing invasiveness and complications<sup>6,8,9</sup>. However, myelography is still performed, for example, for diagnostic purposes in patients with an implanted cardioverter-defibrillator contraindicating magnetic resonance imaging<sup>3</sup>. In contrast to ferromagnetic artifact of MRI, myelography produces high quality images in the presence of metallic implants like pedicle screws<sup>10,19</sup>. Furthermore, although there is no evidence, myelography is sometimes preferred due to contrast's physical characteristics, specific gravity, which may also evoke clinical symptoms, such as, radiculopathy after migrating under gravity<sup>4</sup>.

At the beginning of this study, we assumed that myelography was more accurate than MRI or MRM, and that it reflected better the symptomatic severity. This was because

the fact that MRI and MRM provide static images, whereas myelography provides dynamic images by utilizing the high specific gravity of water soluble contrast, and is considered to be a type of provocation study. In the view of interpretational reproducibility, myelography is supposed to be better than MRI. To compare the interpretational reproducibility, we used four standards. We expressed complete interobserver agreement as in cases of all interpretations were same, which we thought was the most ideal and desirable. To gain more strong evidence, we used other statistical methods which would be able to reflect the interpretational reproducibility; concordant rate (more than 3 results were same), one grade difference rate (all interpretational result were within 1 grade)<sup>11</sup> and standard deviation of interpretational scores. However, in this study there was no difference in the aspect of neither clinical correlations nor interpretational reproducibility.

Regarding MRI and MRM, their less invasive natures, low complication rates, and high inter-observer agreements are strong points as compared with myelography<sup>1,5,15,18</sup>. However, there are different opinions about MRM, which is less accurate<sup>12,16</sup>. Myelography is good radiologic method for the evaluation of spinal disease, especially in specific conditions. However, it is invasive and has possible complications. The present study shows that all three modalities produce similar results, regardless the standards. The results of the present study also show significant relationships between the three in terms of radiologic performance. MRI with MRM can replace myelography, especially for the diagnosis of young adults with a spinal disorder. In terms of interpretational reproducibility, this study also shows that MRI and MRM are equivalent to myelography.

There are several limitations in this present study. All pati-

ents were male, soldiers, in-patients and young adults. The number of participants was small in number, being 65, and it was retrospective. However, cross-sectional studies in military medicine have some unique strong points, for example in the present study, all patients were males in their early 20's, and soldiers, and the lack of potential confusing factors added to the power of the statistical analysis.

## CONCLUSION

Although MRI, MRM, and myelography are based on different physical principles, they produce similar results in terms of diagnosis performance in young soldiers with HLD. None of these three modalities reflected symptom severity and no one technique was superior to the others in terms of interpretation. The authors believe that the results of this study could help the military administration to produce a better patient management guidelines.

## References

1. Aota Y, Niwa T, Yoshikawa K, Fujiwara A, Asada T, Saito T : Magnetic resonance imaging and magnetic resonance myelography in the pre-surgical diagnosis of lumbar foraminal stenosis. *Spine* 32 : 896-903, 2007
2. Borenstein DG, O'Mara JW Jr, Boden SD, Lauerman WC, Jacobson A, Platenberg C, et al. : The value of magnetic resonance imaging of the lumbar spine to predict low-back pain in asymptomatic subjects : a seven-year follow-up study. *J Bone Joint Surg Am* 83-A : 1306-1311, 2001
3. Boye S, Schumacher J : Diagnosis of vertebral canal haematoma by myelography and spiral computer tomography in a patient with an implantable cardioverter-defibrillator contraindicating magnetic resonance imaging. *Br J Anaesth* 103 : 137-138, 2009
4. Cordier D, Wasner MG, Gluecker T, Gratzl O, Merlo A : Acute paraplegia after myelography : decompensation of a herniated thoracic disc. *Br J Neurosurg* 22 : 684-686, 2008
5. de Graaf I, Prak A, Bierma-Zeinstra S, Thomas S, Peul W, Koes B : Diagnosis of lumbar spinal stenosis : a systematic review of the accuracy of diagnostic tests. *Spine (Phila Pa 1976)* 31 : 1168-1176, 2006
6. Doh J, Hwang S, Yun S, Bae H, Lee K, Yun I, et al. : Acute paraplegia following lumbar puncture in a patient with cervical disc herniation - case report -. *J Korean Neurosurg Soc* 30 : 1042-1046, 2001
7. Fardon DF, Milette PC : Nomenclature and classification of lumbar disc pathology. Recommendations of the combined task forces of the north american spine society, american society of spine radiology, and american society of neuroradiology. *Spine* 26 : E93-E113, 2001
8. Feydy A, Pluot E, Guerini H, Drape JL : Role of imaging in spine, hand, and wrist osteoarthritis. *Rheum Dis Clin North Am* 35 : 605-649, 2009
9. Goldberg AL, Kershah SM : Advances in imaging of vertebral and spinal cord injury. *J Spinal Cord Med* 33 : 105-116
10. Grams AE, Gempt J, Forschler A : Comparison of spinal anatomy between 3-tesla mri and CT-myelography under healthy and pathological conditions. *Surg Radiol Anat*, 2009
11. Griffith JF, Wang YX, Antonio GE, Choi KC, Yu A, Ahuja AT, et al. : Modified pfirrmann grading system for lumbar intervertebral disc degeneration. *Spine (Phila Pa 1976)* 32 : E708-E712, 2007
12. Hergan K, Amann T, Vonbank H, Hefel C : Mr-myelography : A comparison with conventional myelography. *Eur J Radiol* 21 : 196-200, 1996
13. Jarvik JG, Hollingworth W, Heagerty PJ, Haynor DR, Boyko EJ, Deyo RA : Three-year incidence of low back pain in an initially asymptomatic cohort : Clinical and imaging risk factors. *Spine* 30 : 1541-1548; discussion 1549, 2005
14. Malfair D, Beall DP : Imaging the degenerative diseases of the lumbar spine. *Magn Reson Imaging Clin N Am* 15 : 221-238, vi, 2007
15. Molla E, Marti-Bonmati L, Arana E, Martinez-Bisbal MC, Costa S : Magnetic resonance myelography evaluation of the lumbar spine end plates and intervertebral disks. *Acta Radiol* 46 : 83-88, 2005
16. O'Connell MJ, Ryan M, Powell T, Eustace S : The value of routine mr myelography at mri of the lumbar spine. *Acta Radiol* 44 : 665-672, 2003
17. Pfirrmann CW, Dora C, Schmid MR, Zanetti M, Hodler J, Boos N : Mr image-based grading of lumbar nerve root compromise due to disk herniation : reliability study with surgical correlation. *Radiology* 230 : 583-588, 2004
18. Ramsbacher J, Schilling AM, Wolf KJ, Brock M : Magnetic resonance myelography (MRM) as a spinal examination technique. *Acta Neurochir (Wien)* 139 : 1080-1084, 1997
19. Song KJ, Choi BW, Kim GH, Kim JR : Clinical usefulness of ct-myelogram comparing with the mri in degenerative cervical spinal disorders : is CTM still useful for primary diagnostic tool? *J Spinal Disord Tech* 22 : 353-357, 2009
20. Videman T, Battie MC, Gibbons LE, Maravilla K, Manninen H, Kaprio J : Associations between back pain history and lumbar mri findings. *Spine (Phila Pa 1976)* 28 : 582-588, 2003
21. Zhang Y, An HS, Tannoury C, Thonar EJ, Freedman MK, Anderson DG : Biological treatment for degenerative disc disease : Implications for the field of physical medicine and rehabilitation. *Am J Phys Med Rehabil* 87 : 694-702, 2008