

Successful Renal Autotransplantation for the Treatment of Severe Renovascular Hypertension in a 14-year-old Boy

Min Chul Ji, M.D., Se Jin Park, M.D., Jae Young Choi, M.D.*
Young Guk Ko, M.D.[†], Myoung Soo Kim, M.D.[‡]
Ji Hong Kim, M.D. and Jae Il Shin, M.D.

The Institute of Kidney Disease, Department of Pediatrics, Severance Children's Hospital
Department of Pediatric Cardiology*, Internal Medicine[†]
Department of Surgery and The Research Institute for Transplantation[‡]
Yonsei University College of Medicine, Seoul, Korea

= Abstract =

Percutaneous transluminal renal angioplasty (PTRA) is the current treatment of choice for renal artery revascularization, but renal autotransplantation has been an alternative treatment for complex cases. Here we report a 14-year-old boy with severe hypertension successfully treated with PTRA and renal autotransplantation. Doppler ultrasonography and computed tomography (CT) angiography revealed slight narrowing in the right renal artery ostium and complete obstruction in the left renal artery ostium with multiple collaterals. PTRA with stent insertion was performed for the treatment of the right renal artery, but it was impossible for the left renal artery due to the total obstruction. Therefore, left nephrectomy for autotransplantation was done with the peritoneal approach and the left kidney was autotransplanted to the ipsilateral iliac fossa. Postoperatively, Doppler ultrasonography and mercapto-acetyl-triglycine (MAG-3) renogram were performed, which showed normal renal artery blood flow and kidney function. Blood pressure was normalized and anti-hypertensive drugs were gradually tapered. Fibromuscular dysplasia was suspected to be responsible for the renal artery stenosis based on clinical aspects. In conclusion, renal autotransplantation is also a good treatment option for children with severe renovascular hypertension when endovascular treatment has failed or is not possible. (**J Korean Soc Pediatr Nephrol 2010;14:223-229**)

Key Words : Renovascular, hypertension, percutaneous transluminal renal angioplasty, renal autotransplantation, Children

Introduction

Hypertension is uncommon in children and adolescents and is usually secondary to an underlying disease. Renovascular disease is the most common cause of hypertension in this age

접수 : 2010년 9월 17일, 수정 : 2010년 9월 20일
승인 : 2010년 9월 28일
책임저자 : 신재일, 서울시 서대문구 성산로 250
연세대학교 의과대학 소아과학교실
Tel : 02)2228-2073 Fax : 02)393-9118
E-mail : shinji@yuhs.ac

group which covers 5–10% of all cases [1, 2]. Renovascular disease is a potentially curable cause of hypertension. Therapeutic options include medications, surgical revascularization and percutaneous transluminal renal angioplasty (PTRA) [3, 4]. Currently, PTRA is a preferred treatment for renal artery revascularization, but renal autotransplantation has been an alternative treatment for complex cases. Nevertheless, there are a few reports on renal autotransplantation in pediatric patients with severe renal artery stenosis [5–7]. Here, we report the case of a 14-year old boy with very severe stenosis of renal artery requiring renal autotransplantation.

Case report

A 14-year-old boy was referred to our hospital for further evaluation and proper treatment with the diagnosis of renal artery stenosis made at another hospital. He had intermittent headaches which developed 15 months ago and aggravated since 4 months ago. He had no family history of renal disease or hypertension and presented with no other neurologic manifestation (i.e. seizures) except for headache. He did not show signs of any genetic syndrome such as dysmorphic features or café au lait spots. No abdominal bruit was heard. The initial blood pressure was 160/120 mmHg. Blood pressures on both extremities were measured: 160/100 mmHg on the right arm, 160/105 mmHg on the left arm, 175/115 mmHg on the right leg, and 170/110 mmHg on the left leg.

On admission, the laboratory findings were as follows: Hemoglobin 14.3 g/dL, WBC 4,520/

mm³, Platelet 241,000/mm³, BUN/Cr 9.9/0.63 mg/dL, total protein 6.6 g/dL, albumin 4.5 g/dL, total calcium 9.4 mg/dL, phosphorus 4.5 mg/dL, Na 141 mmol/L, K 4.6 mmol/L, Cl 104 mmol/L, C-reactive protein (CRP) <1 mg/L (normal: 0–8 mg/L), erythrocyte sedimentation rate (ESR) 8 mm/hour (normal: 0–15 mm/hour), T3 160 ng/dL (normal: 80–200 ng/dL), fT4 1.13 ng/dL (normal: 0.73–1.95 ng/dL), TSH 0.8 μ IU/mL (normal: 0.3–4.0 μ IU/mL) and cortisol 82 ng/mL (normal: 70–250 ng/mL). Renin (3.42 ng/ml/hr, normal: 1.31–3.95 ng/ml/hr) and aldosterone (119.5 pg/mL, normal: 38.9–306.8 pg/mL) levels were within normal ranges. Urinalysis did not show any proteinuria and hematuria. 24-(hour) urine Vanillylmandelic acid and metanephrine were 5.25 mg/day (normal: 0–8.0 mg/day) and 0.5 mg/day (normal: 0–1.3 mg/day), respectively. Fundoscopic findings showed no abnormal vascularity, and no systolic or diastolic dysfunction was found on the echocardiogram.

24-(hour) ambulatory blood pressure monitoring was applied, and the mean blood pressure was 173/116 mmHg (systole 101–212 mmHg, diastole 74–156 mmHg) during the day and was 153/93 mmHg (systole 133–202 mmHg, diastole 54–146 mmHg) during the night.

Captopril renogram, Doppler ultrasonography and CT angiography were performed to evaluate renal artery stenosis. CT angiography and renal angiography (Fig. 1A, B) demonstrated slight narrowing in the right renal artery ostium and complete obstruction in the left renal artery ostium with multiple collaterals. No abnormalities were observed in the abdominal aorta.

Revascularization was planned because hy-

pertension was not adequately controlled with amlodipine and atenolol combination therapy. PTRAs with stent insertion was performed for the treatment of the right renal artery, but it was impossible for the left renal artery due to the total obstruction. Therefore, left nephrectomy for autotransplantation was done with the peritoneal approach. For minimization of ischemic injury, renal arterial perfusion via collateral arteries was maintained until the nephrectomy. Cold perfusion with organ preservation solution (Histidine-Tryptophane-Ketoglutarate solution) was performed through the intact left renal artery, and we carried out a subsequent renal biopsy for the evaluation of histologic abnormality of the autotransplantation, which demonstrated normal renal architecture. The left kidney was autotransplanted to the ipsilateral iliac fossa. The left renal vein was anastomosed to the external iliac vein by the end-to-side fashion, and the left renal artery was anastomosed to the external iliac artery by the end-to-side fashion.

Fibromuscular dysplasia was suspected to be causing the renal artery stenosis based on clinical aspects, including young age, absence of signs suggesting a genetic syndrome and normal ESR and CRP levels.

Postoperatively, Doppler ultrasonography and MAG-3 renogram were performed, which showed normal renal artery blood flow and kidney function. A technetium-99m-labeled dimercaptosuccinic acid (DMSA) scan revealed that the autotransplanted kidney functioned well (Fig. 2). Blood pressure was normalized to 127/70 mmHg, and anti-hypertensive drugs were gradually tapered. Only aspirin was administered to prevent thrombosis.

Discussion

Renovascular hypertension is classically defined as systemic hypertension from renal arterial stenosis or obstruction and results from an activation of renin-angiotensin caused by decreased arterial blood flow to a part or all

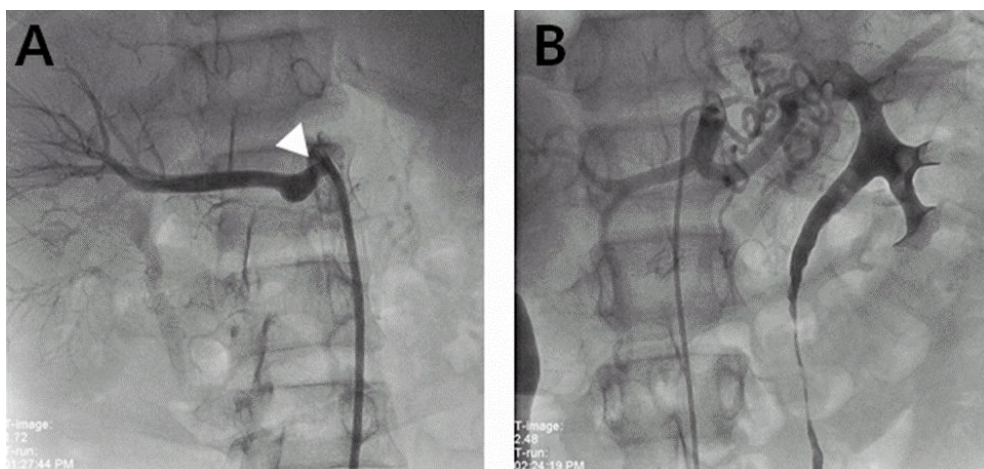


Fig. 1. (A) Right renal angiography shows the stenosis of right renal artery ostium (white arrow head). (B) Left renal angiography shows collateral vessels.

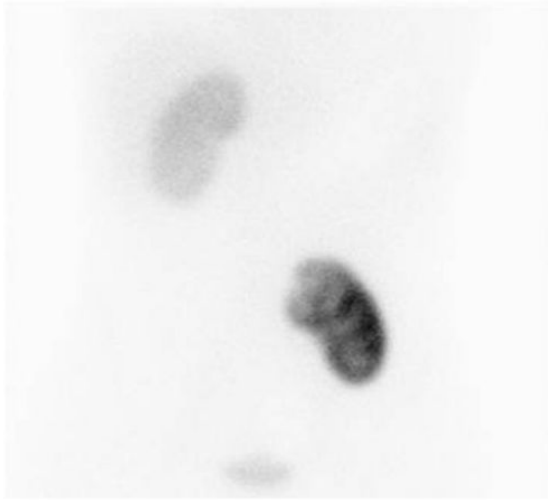


Fig. 2. DMSA scan shows that left autotransplanted kidney functions well

of one or both kidneys, secondary to stenotic abnormalities of the aorta or renal artery and its branches [8]. But, plasma renin activity may not be elevated in the bilateral renal artery stenosis like our patient because elevated systemic blood pressure developed with sodium and volume retention eventually restores the renin level to normal [9]. The etiologies of renovascular hypertension in pediatric patients differ from those in adults, in whom the disorder is mostly related to atherosclerosis. The most common cause of renovascular hypertension in this age group is fibromuscular dysplasia, which accounts for up to 60% [10]. Other causes include middle aortic syndrome, neurofibromatosis type I, tuberous sclerosis, Williams' syndrome, Marfan syndrome, and different kinds of systemic vasculitis such as Takayasu's disease, polyarteritis nodosa, and Kawasaki disease [11]. Different types of tumors including neuroblastoma and Wilms' tumor can also compress the renal vasculature

causing hypertension [11].

Several imaging modalities play a role in screening renal artery stenosis in hypertensive patients including Doppler ultrasonography, renal scintigraphy, CT angiography, and magnetic resonance angiography. Even though many advances have been made in imaging technology, digital subtraction angiography remains the gold standard in the diagnosis of renovascular disease [12].

Therapeutic modalities of renovascular hypertension include antihypertensive medication, PTRA with or without stent implantation, and surgical treatment [3, 4]. Patients with renovascular hypertension usually need more than one antihypertensive drug for blood pressure control, but do not show a favorable response to medical therapies. We started with amlodipine and added atenolol because previous administration of angiotensin-converting enzyme inhibitor at the other hospital was not effective, but the result was not satisfactory.

Long-term administration of antihypertensive drug causes side effects and reduced intrarenal blood flow may lead to renal parenchymal damage and the deterioration of renal function. In these situations, endovascular therapy and surgery are two options for renal artery revascularization.

PTRA with or without stenting is a valuable treatment option in pediatric renal artery stenosis [13], of which the success rate is in the range of 28–94% in several studies [11]. Some patients develop restenosis after PTRA which can be treated by repeated angioplasty or surgery [14]. PTRA may be unsuccessful or not possible in some cases because of the

hilar location of atherosclerosis or inflammatory lesions in vasculitis such as Takayasu's arteritis. Open surgery can be indicated when both medical treatment and PTRAs have failed.

Nephrectomy was an initial operative intervention for the cure of renovascular hypertension, but currently the indication would be just for the removal of a small, poorly functioning kidney that is causing the hypertension [11]. The surgical options available for renovascular hypertension include in situ revascularization with aorto-renal, spleno-renal, or mesenterio-renal bypass techniques and renal autotransplantation [8]. Surgical outcome was good with cure rates of 36-70% and with improvement in a further 26-56% [11].

Dubernard et al. reported that renal autotransplantation was superior to bypass surgery, especially in relief of hypertension and long-term angiographic changes [15]. In addition, bypass surgery is not available for small children because of technical limitations [8]. For these reasons, renal autotransplantation has been an alternative treatment for more than 30 years, especially in complex cases [6]. Chiche et al. investigated the early and late outcomes of renal autotransplantation according to the etiology of the underlying renal artery disease [6]. They concluded that renal autotransplantation was a highly effective treatment for complex renovascular lesions related to fibromuscular dysplasia and Takayasu's disease, and it might be the only alternative in cases involving extensive renovascular disease although it was less effective for atherosclerosis [6]. Nevertheless, most of the pediatric patients have been successfully treated with PTRAs and

only a few case of renal autotransplantation have recently been reported [5-7]. Though renal transplantation is a relatively safe procedure, it may be accompanied with some complications. Minor complications include a suture abscess, mild chronic wound pain and transient acute tubular necrosis, and major complications include renal artery stenosis, bowel infarction, renal vein thrombosis and transplant loss [16]. Therefore, a careful follow-up after successful surgery is needed.

Though the concise etiology of renal artery stenosis was vague in our patient, the most probable cause was fibromuscular dysplasia. The atherosclerotic change is not common in young age and the normal levels of inflammatory markers lowered the possibility of vasculitis such as Takayasu's disease. The patient had no signs of genetic diseases such as neurofibromatosis type I, tuberous sclerosis and Williams' syndrome.

In conclusion, renal autotransplantation is also a good treatment option for children with severe renovascular hypertension when endovascular treatment has failed or is not possible.

한 글 요 약

신 자가이식을 통한 14세 소년에서 발생한 심한 신성 고혈압의 성공적인 치료

연세대학교 의과대학 세브란스 어린이병원 소아청소년과 신장질환 연구소, 소아심장과*, 내과학교실†, 외과학교실, 장기이식 연구소‡

지민철 · 박세진 · 최재영*
고영국† · 김명수‡ · 김지홍 · 신재일

신성 고혈압은 신동맥의 협착 혹은 폐색으로 인해 유발되는 전신성 고혈압이다. 최근에는 신동맥의 재

개통을 위해 PTR가 선호되고 있지만, 복잡한 경우에 있어서는 신 자가이식이 대안적인 치료방법으로서 시행되어 왔다. 저자들은 심각한 고혈압 증상을 보인 14세 남자 환아를 PTR 및 신 자가이식을 시행하여 성공적으로 치료하였기에 보고하는 바이다. 도플러 초음파 검사와 CT 혈관조영술상 우측 신동맥 기시부에서 약간의 좁아짐과 다발적인 측부순환을 동반한 좌측 신동맥 기시부의 완전폐색이 확인되었다. 우측 신동맥 협착의 치료를 위해 PTR와 스텐트 삽입술을 시행하였으나 좌측 신동맥은 완전폐색으로 인해 시술이 불가능하여 좌측 신장을 절제한 후 동측 장골외에 자가이식하였다. 수술 후 시행한 도플러 초음파 검사와 MAG-3 신주사 검사상 신혈류와 신기능은 정상이었다. 혈압은 정상화되었으며 항고혈압제 투여도 점차 중단하였다. 임상적인 특성을 고려할 때 신성 고혈압의 원인은 섬유근성 형성이상으로 생각되었다. 결론적으로 신 자가이식은 혈관내 중재적 시술이 실패하였거나 불가능한 경우에 선택할 수 있는 치료방법이다.

References

- 1) Gill DG, Mendes de CB, Cameron JS, Joseph MC, Ogg CS, Chantler C. Analysis of 100 children with severe and persistent hypertension. *Arch Dis Child* 1976;51:951-6.
- 2) Wyszynska T, Cichocka E, Wieteska-Klimczak A, Jobs K, Januszewicz P. A single pediatric center experience with 1025 children with hypertension. *Acta Paediatr* 1992; 81:244-6.
- 3) Kang BC, Ha IS, Kim IO, Cheong HI, Choi Y, Ko KW. Renovascular hypertension in children. *J Korean Soc Pediatr Nephrol* 1997;1:101-8.
- 4) Lee KY, Chang KO, Kim MS, Hong SJ, Kim SS, Kim YS, et al. Renal autotransplantation—a case report—. *J Korean Soc Vasc Surg* 1995;11:151-6.
- 5) Sevmis S, Karakayali H, Boyvat F, Aytakin C, Haberal M. Renal autotransplantation for complex renovascular hypertension. *Transplant Proc* 2006;4:559-61.
- 6) Chiche L, Kieffer E, Sabatier J, Colau A, Koskas F, Bahnini A. Renal autotransplantation for vascular disease: late outcome according to etiology. *J Vasc Surg* 2003;37: 353-61.
- 7) Huang Y, Duncan AA, McKusick MA, Milliner DS, Bower TC, Kalra M, et al. Renal artery intervention in pediatric and adolescent patients: a 20-year experience. *Vasc Endovascular Surg* 2008;41:490-9.
- 8) Arap S, Dénes F T, Bortolotto L. Renovascular hypertension in children. *Curr Urol Rep* 2001;2:181-2.
- 9) Textor SC. Renovascular hypertension and ischemic nephropathy. In: Brenner BM, editors. *Brenner & Rector's The Kidney*. 8th ed. Philadelphia: Saunders, 2008:1528-66.
- 10) Estepa R, Gallego N, Orte L, Puras E, Aracil E, Ortuño. Renovascular hypertension in children. *Scand J Urol Nephrol* 2000;35: 388-92.
- 11) Tullus K, Brennan E, Hamilton G, Lord R, McLaren CA, Marks SD, et al. Renovascular hypertension in children. *Lancet* 2008;371: 1453-63.
- 12) Gao J, Fisher A, Chung J. Color duplex ultrasonography in detecting renal artery abnormalities in a patient with neurofibromatosis 1: a case report. *Clin Imaging* 2006;30:140-2.
- 13) König K, Gellermann J, Querfeld U, Schneider MB. Treatment of severe renal artery stenosis by percutaneous transluminal renal angioplasty and stent implantation: review of the pediatric experience—apropos of two cases. *Pediatr Nephrol* 2006;21:663-71.
- 14) Shroff R, Roebuck DJ, Gordon I, Davies R, Stephens S, Marks S, et al. Angioplasty for renovascular hypertension in children: 20-year experience. *Pediatrics* 2006;118:268-75.
- 15) Dubernard JM, Martin X, Gelet A, Mongin D,

- Canton F, Tabib A. Renal autotransplantation versus bypass techniques for renovascular hypertension. *Surgery* 1985;97:529-34.
- 16) Webster JC, Lemoine J, Seigne J, Lockhart J, Bowers V. Renal autotransplantation for managing a short upper ureter or after ex vivo complex renovascular reconstruction. *BJU Int* 2005;96:871-4.