

A case of postoperative nasopharyngeal reflux associated with retropharyngeal lymphangioma in newborn infant

Kyo Yeon Koo, M.D., Jun Seok Lee, M.D., Soon Min Lee, M.D., Min Soo Park, M.D.
Ran Namgung, M.D., Kook In Park, M.D., Chul Lee, M.D., Choon Sik Yoon, M.D.*
Woo Hee Jung, M.D.[†] and Hong Shik Choi, M.D.[†]

Departments of Pediatrics, Radiology*, Clinical Pathology[†] and Otorhinolaryngology[†]
Yonsei University College of Medicine, Seoul, Korea

= Abstract =

Lymphangioma is a rare benign congenital tumor of the lymphatic system, which is commonly diagnosed before 2 years of age. In the national report, cystic lymphangioma was usually reported as a huge translucent mass located in the head and neck area. Its occurrence in retropharyngeal space with respiratory obstruction and swallowing difficulty in neonate is extremely rare and postoperative nasopharyngeal reflux has rarely been reported. Complete resection is the standard therapy. However, involvement of the upper airway may be determining prognosis in the extensive lymphangiomas because of the difficulty of complete excision. We present a case of cystic lymphangioma in neonate which was initially asymptomatic but gradually progressed to cause respiratory obstruction due to enlargement. After resection, nasopharyngeal reflux developed with dysfunction of the soft palate and gradually improved with conservative care over 5 months. (*Korean J Pediatr* 2010;53:258-261)

Key Words : Cystic Lymphangioma, Deglutination disorder, Excision, Pharyngeal Diseases

Introduction

Lymphangioma is a benign congenital tumor of the lymphatic system which involves chiefly the head and neck¹⁾. But retropharyngeal lymphangioma with respiratory obstruction and swallowing difficulty is extremely rare in a neonate²⁾. Retropharyngeal lymphangioma are mostly asymptomatic. But occasionally obstructive symptoms, failure to thrive and respiratory distress may be present when the tumors extend into the upper airway and oral cavity and these symptoms sometimes rarely sustain after operation^{3, 4)}. Complete excision is the best choice for treatment of lymphangioma⁴⁾. However, it is difficult to execute complete excision of the retropharyngeal lymphangioma around the upper airway^{1, 3, 4)}. In this paper, we present a case of re-

tropharyngeal lymphangioma with postoperative nasopharyngeal reflux in a 14 day-old neonate.

Case report

A male baby was born at 40⁺¹ weeks of gestation by normal vaginal delivery. The birth weight was 3,280 g. His mother had received prenatal screening check-ups routinely without any specific findings. Immediately after birth, he had transient tachypnea and intermittent vomiting but improved in several hours. Initial physical examination revealed no specific abnormal findings. However, on the eleventh day after birth, the patient had an episode of sudden desaturation and continued to display chest retractions, coarse breath sounds and stridor. We intubated the patient for respiratory care and enhanced computed tomography (CT) scan of the neck was performed for the evaluation of airway on the fourteenth day. CT scan of the neck showed a large retropharyngeal cystic mass which highly suggested the possibility of cystic lymphangioma. The cystic lesion was measured 3.1×2.9×1.1 cm. The mass was mainly located in anteroinferior aspect of the clivus reaching the

Received : 25 July 2009, Revised : 9 October 2009

Accepted : 2 November 2009

Address for correspondence : Min Soo Park, M.D.

Department of Pediatrics, Gang Nam Severance Hospital, Yonsei University College of Medicine, 146-92 Dogok-dong, Gangnam-gu, Seoul 135-720, Korea.

Tel : +82.2-2019-3351, Fax : +82.2-3461-9473

E-mail : minspark@yuhs.ac

anterior portion of C4 body with compression of retropharyngeal and pharyngeal airway and extended along the left parapharyngeal space and anterior aspect of left carotid space to the left lower neck, 2.2 cm in length (Fig. 1A). On the same day, surgical excision was performed under general anesthesia via transoral approach. Bulging mass was exposed on the retropharyngeal area from nasopharynx level to oropharynx level. Its capsule was removed easily with an incision over the cyst. Yellowish clear discharge was sucked out, and the tissue pathology confirmed the lesion as a cystic lymphangioma. A follow-up CT scan of the neck was done on the next day. The previously noted retropharyngeal cystic lesion had disappeared at the central neck portion (Fig. 1B).

Because post-operative oral feedings were unsuccessful, accompanied with sustained vomiting and dysphagia, we additionally performed an esophagography. The initial esophagography showed mild nasopharyngeal reflux with aspiration of contrast from the oropharynx to the nasopharynx and signs of dysfunction of the soft palate without a tracheoesophageal fistula (Fig. 2A). The feeding was supplied entirely by a feeding tube.

After discharge, a series of esophagography were done for nasopharyngeal reflux. Two months after operation, follow-up esophagography still visualized minimal aspiration in the side of trachea (Fig. 2B). However, the final follow-up esophagography at 5 months after operation

showed no evidence of nasopharyngeal reflux, and the patient was tolerable to the oral feedings (Fig. 2C). In addition, echocardiography, neurosonography and abdominal sonography showed no specific findings.

Discussion

Lymphangioma is a rare benign congenital tumor of the lymphatic system, which is classified based on the size of the endothelial cell-lined lymphatic sinuses histologically: Capillary lymphangioma consist of small capillary-sized lymphatic vessels, cavernous lymphangioma contain large dilated lymphatic vessels and cystic lymphangioma contain large macrocystic spaces^{1, 3)}. Our case was diagnosed as cystic lymphangioma on the ground of tissue pathology and on the radiologic finding of cystic mass occupying space.

Lymphangioma can appear in any site, but the cystic lymphangiomas usually appear as large soft tissue masses with translucency on the exposed areas of the neck and can be easily discovered early in life even though main parts was deeply seated in loose connective tissues^{1, 4, 5)}. However, involvement of the upper airway is rare, and only few cases are reported in retropharyngeal space or isolated to the larynx. In our case the lymphoma involved the upper airway, more specifically the retropharyngeal area. Lymphangioma presents in variable sizes⁴⁾. Small and unnoticed lymphangioma is only presented later with secondary symp-

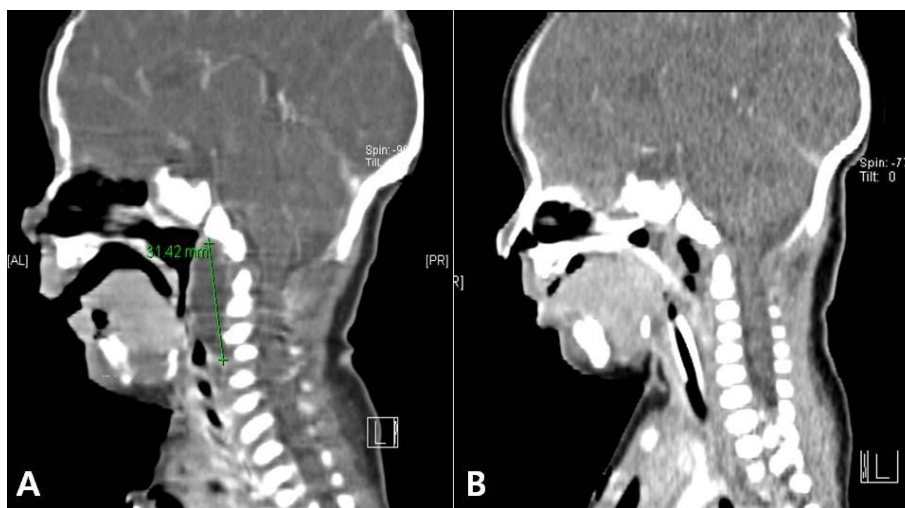


Fig. 1. (A) A cervical CT scan shows a large retropharyngeal cystic mass with a low attenuation density, measured at 3.1×2.9×1.1 cm and mainly located from anteroinferior aspect of clivus to anterior portion of C4 body with compression of retropharyngeal and pharyngeal airway. (B) Postoperative cervical CT shows resected lesion of the cystic mass with air shadow and postsurgical fluid collection.

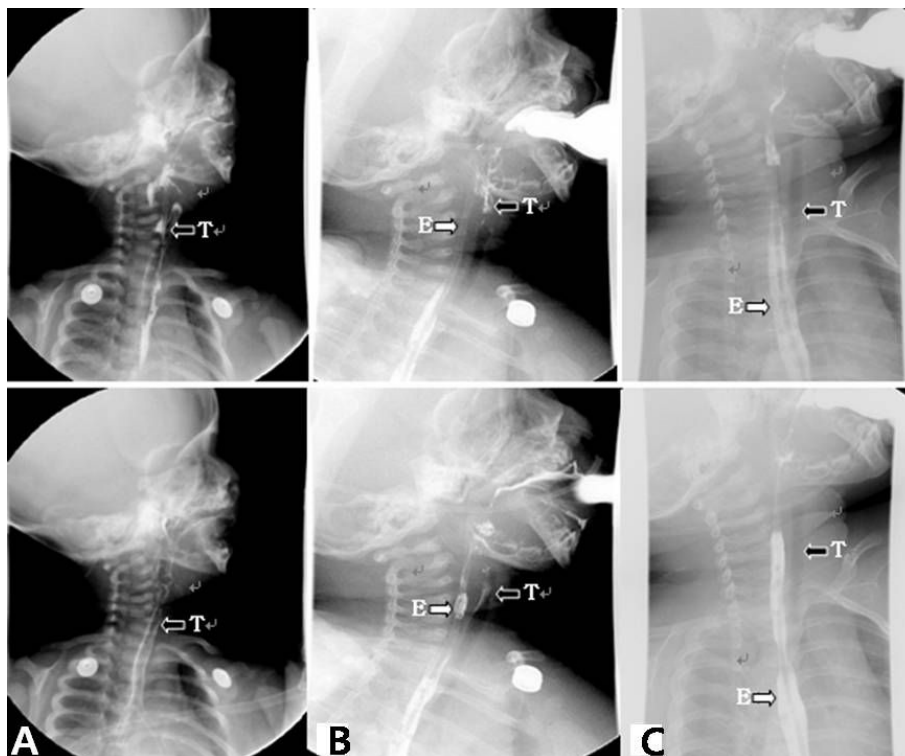


Fig. 2. Esophagography was performed serially. (A) The initial esophagography showed mild retropharyngeal reflux with aspiration of contrast from the oropharynx to the nasopharynx and trachea and dysfunction of the soft palate without a tracheoesophageal fistula. (B) At 2 month after operation, contrast still appeared in trachea presenting minimal aspiration after swallowing. (C) At 5 month after operation, tracheal aspiration was not visible after swallowing barium. The white arrow (⇔) indicate esophagus and the black arrow (◀) indicate the trachea. Abbreviations : T, trachea; E, esophagus.

toms depending on their size or locations. In the case of infection, trauma or hemorrhage, the cyst can rapidly grow in size in several days, however, it usually grows slowly in proportion to the growth of the infant. Respiratory obstruction and swallowing difficulty, which are the second and third most common symptoms take place when mass extends to the oral cavity, pharynx and larynx. Also isolated tongue involvement induce symptoms of macroglossia, dysphagia and airway obstruction. Stridor, cyanosis, apnea, dysphagia with failure to thrive, these symptoms appear when cysts extend into thoracic inlet, mediastinum^{3, 4, 6}. Dyspnea occurs in 11% to 27% of the patients⁷. When cystic hygroma is located in the retropharyngeal space, it is not easily detected initially, but may later be detected by secondary symptoms like respiratory obstruction and feeding problem^{3, 4}.

Involvement of the upper airway may be a factor determining prognosis because of the difficulty of complete excision^{1, 3, 4, 6, 7}. Even though the new treatment modalities

such as sclerotherapy, diathermy, percutaneous aspiration, radiotherapy and systemic cyclophosphamide, the treatment of choice at present is complete radical resection of the mass in order to prevent the recurrence of lymphangiomas^{1, 3, 4, 6}. The recurrence rate depends upon the complexity of the lesion and completeness of excision. For completely removed lesions the recurrence rate was approximately 10–27%, whereas for partially resected lesions, 50–100%³. If possible, early surgery is recommended before developing ambiguous boundary with adjacent tissue. Only neonates with large cervical cystic hygromas causing tracheal compression and respiratory distress require urgent resection^{1, 3, 4}.

In transoral surgery, the rate of postoperative complication reveals in approximately 45% which consist with wound infection (7.4%), infection or leakage of cerebrospinal fluid (11.1%), lower cranial nerve dysfunction (11.1%), palatal problem (14.8%), swallowing problem or speech difficulty (18.5%) and nasopharyngeal reflux (11.1%)⁹. However

nasopharyngeal reflux almost related with palatal extension of transoral procedure and has rarely been reported in the neonate^{9, 10}. In the barium study, nasopharyngeal reflux is defined as passage of contrast medium from the oropharynx or hypopharynx into the nasopharynx of the nose in the course of swallowing¹¹. After transoral procedure, it mainly occur due to velopharyngeal insufficiency, as a result of soft or hard palate injury, structural changes in the posterior pharyngeal wall or large dead space in the posterior pharynx^{9, 10}. In our case, nasopharyngeal reflux was noted after transoral procedure without palatal extension, not from any anatomic abnormality such as tracheal-esophageal fistula but from dysfunction of soft palate. Spontaneous regression of postoperative nasopharyngeal reflux is mentioned in report of choanal atresia¹¹, as was found in our case.

We present a rare case of retropharyngeal lymphangioma in a 14-day-old infant. The baby initially was asymptomatic but later manifested stridor and respiratory difficulty, and eventually treated with excision of the mass. After resection, nasopharyngeal reflux which caused postoperative feeding difficulty persisted for a while, it was resolved gradually over 5 months after surgery.

요 약

수술 후 비인두 역류가 동반된 신생아의 후인두림프관종 1례

연세대학교 의과대학 소아과학교실
방사선과학교실*, 병리학교실†, 이비인후과학교실‡

구교연 · 이준석 · 이순민 · 박민수 · 남궁란
박국인 · 이 철 · 윤춘식* · 정우희† · 최홍식‡

후인두림프관종은 무증상으로 시작되어 크기의 증가에 따라 주위 구조물들을 압박하여 호흡곤란이나 연하곤란 등의 2차적 증상들을 유발할 수도 있는 드문 양성 종양이다. 현재까지 치료는 수술에 의한 완전 적출이 원칙이나 기도 주변에 인접한 림프종의

경우에는 완전 적출이 어려워 예후가 나쁘다. 신생아에서 후인두림프관종이 보고 된 경우는 드물며, 수술 후에 비인두역류증이 발생된 경우는 극히 드물다. 이에 저자들은 생후 14일에 호흡곤란 및 연하곤란 증상을 보인 신생아에서 후인두림프관종을 진단하여 완전 적출술로 치료하였으며 수술 후에 비인두역류증이 일정 기간 지속되어 보존적 치료를 시행한 후 회복된 1례를 경험하였기에 이를 보고하고자 한다.

References

- 1) Kang BS, Kang H, Kim SY, Kim JW, Park YM, Park CJ, et al. A clinicopathologic study of lymphangioma. Korean J Dermatol 2006;44:1044-50.
- 2) Smith WL, Yousefzadeh DK, Yiuchiu VS, Franken EA. Percutaneous aspiration of retropharyngeal space in neonate. AJR Am J Roentgenol 1982;139:1005-6.
- 3) Grasso DL, Pelizzo G, Zocconi E, Schleaf J. Lymphangiomas of the head and neck in children. Acta Otorhinolaryngol Ital 2008;28:17-20.
- 4) Brown RL, Azizkhan RG. Pediatric head and neck lesions. Pediatr Clin North Am 1998;45:889-905.
- 5) Sannoh S, Quezada E, Merer DM, Moscatello A, Golombek SG. Cystic hygroma and potential airway obstruction in a newborn: a case report and review of the literature. Cases J 2009;2:48-52.
- 6) Rosa PA, Hirsch DL, Dierks EJ. Congenital neck masses. Oral Maxillofac Surg Clin North Am 2008;20:339-52.
- 7) Hartl DM, Roger G, Denoyelle F, Nicollas R, Triglia JM, Garabedian EN. Extensive lymphangioma presenting with upper airway obstruction. Arch Otolaryngol Head Neck Surg 2000;126:1378-82.
- 8) Kenton A, Duncan N, Bhakta K, Fernandes CJ. Laryngeal lymphatic malformation in a newborn. J Perinatol 2003;23:567-71.
- 9) Tuite GF, Veres R, Crockard HA, Shell D. Pediatric transoral surgery: indications, complications, and long-term outcome. J Neurosurg 1996;84:573-83.
- 10) Itani O, Proffit C, May D, Shekhawat P. Special feature: radiological case of the mouth. velopharyngeal insufficiency causing nasopharyngeal reflux in the neonate. Arch Pediatr Adolesc Med 2000;154:1167-8.
- 11) Oestreich AE, Dunbar JS. Pharyngonasal reflux: spectrum and significance in early childhood. AJR Am J Roentgenol 1984;142:923-5.