

## 제2족지 수질부 유리피판을 이용한 수지첨부재건 치험례

연세대학교 의과대학 성형외과학교실, 연세대학교 의과대학 인체조직복원연구소

박용순·홍종원·김영석·노태석·나동균

— Abstract —

### Finger Tip Reconstruction Using 2<sup>nd</sup> Toe Pulp Free Flap - A Case Report -

Yong Sun Park, M.D., Jong Won Hong, M.D., Young Suk Kim, M.D.,  
Tai Suk Roh, M.D., Dong Kyun Rah, M.D.

*Department of Plastic & Reconstructive Surgery, Institute for Human Tissue Restoration,  
Yonsei University College of Medicine, Seoul, Korea*

**Purpose:** First introduced by Buncke and Rose in 1979, the neurovascular partial 2<sup>nd</sup> toe pulp free tissue transfer has been attempted to reconstruct posttraumatic finger tip injuries. Although some surgeons prefer other reconstructive methods such as skin graft and local flap, we chose the partial 2<sup>nd</sup> toe pulp flap owing to its many advantages. We report three successful surgical cases in which the patients had undergone this particular method of reconstruction.

**Methods:** We retrospectively examined three cases of fingertip injury patients due to mechanical injury. Bone exposure was seen in all three cases, All had undergone partial toe pulp free flap for soft tissue defect coverage.

**Results:** All flaps survived without any complications such as partial necrosis, hematoma or dehiscence. Although tingling sensation has returned in both cases, two-point discrimination has not returned yet. Currently no patient is complaining of any pain which gradually improved during their course of recuperation. All stitches were removed on postoperative 2 weeks. Patients are satisfied with the final surgical result and there are no signs of any edema or hematoma.

**Conclusion:** The homodigital reconstruction of finger tip injury using the partial 2<sup>nd</sup> toe pulp flap has numerous advantages compared to other reconstructive modalities such as its resistance to wear and tear and in that it provides a non-slip palmar digital surface. However it requires microsurgery which may not be preferred by surgeons. Advanced age of the patient can be a relative contraindication to this approach since atheromatous plaque from the donor toe can compromise flap circulation after surgery. We report three successful cases which patient age was considered appropriate. Further investigation with a larger number of cases and long term follow-up is deemed necessary.

**Key Words:** Finger tip injury, Toe pulp, Free flap

※통신저자: 홍종원

서울특별시 강남구 의주로 712

강남세브란스병원 별관 8층 성형외과학교실

Tel: 02-2019-3420, Fax: 02-3463-4914, E-mail: saturn@yuhs.ac

## I. Introduction

We report three cases in which 2<sup>nd</sup> toe pulp free composite tissue transfer was used to reconstruct soft tissue defect involving the palmar aspect of the finger tip. Both of the tissues had undergone hyperbaric oxygen therapy without any complications and postoperative sensory return was excellent. Donor sites had minimal morbidity with no functional deficit in terms of weight bearing and ambulation. Fingertip reconstruction using the 2<sup>nd</sup> toe pulp is a good method in terms of postoperative result and patient satisfaction. Although this method of reconstruction has been reported during the past several decades, reports are clustered back in the late 1970's and 80's.<sup>14</sup> There have been limited amount of literature although some surgeons have preferred this choice. Therefore we report our successful experiences as a case report to emphasize the significance and advantages of 2<sup>nd</sup> toe pulp free flap.

The Fingertip is defined as structures distal to the creases at the distal interphalangeal joint.

Finger tip injuries are the most common type of amputation injuries. Among the five fingers, the index finger is the most frequently injured digit. Further, the distal end of a digit is the most frequently injured part of the hand.<sup>1</sup> The causes of finger tip injuries encompass occupational injuries using cutting tools such as knives, machines like power-saw or mechanical crushing or avulsion injuries from work places. Injuries resulting from special devices such as agricultural machine or snow blower are also common culprits. Finger tip injuries of the DIP joint usually entails not only functional but also aesthetic loss as well.

Several factors must be taken into consideration in order to reconstruct the finger tip: specific type of reconstruction, amputation level, number of involved digits, the patient's need and motivation, patient's overall general health, medical problems, associated injuries, occupation,

hand dominance, and activity levels.<sup>1</sup> Despite economic strains and difficulties in recovering full function after reconstruction, the partial toe pulp free flap has been quite often opted by many patients in Korea owing to the deeply rooted Confucian preaching that one's body parts must be respected since it is a gift from one's parents.<sup>2</sup> Reconstruction of the fingertip includes composite graft, skin graft, local flaps or regional flaps depending on the size of the soft tissue defect. Soft tissue defects involving the nail and the pulp require not only simple coverage as in the case with composite tissue or skin graft but also a durable cover as well. Sensation is also an important factor.

The advantages of using the great toe for reconstruction of the finger tip injury may include the fact that it provides a greater cutaneous surface than using the 2<sup>nd</sup> toe and a better sensory discrimination (static two point discrimination is 7~18 mm vs 10~25 mm).<sup>3</sup> However despite these advantages the authors of this journal rather used the 2<sup>nd</sup> toe as the donor site because the using the great toe also holds some disadvantages as well.<sup>4</sup> The 2<sup>nd</sup> toe is used instead of the great toe because of the sequelae to the foot is of larger magnitude when the first toe is employed.

The free toe pulp neurovascular flap reconstruction was first introduced by Buncke and Rose in 1979 to reconstruct posttraumatic fingertip injury. Historically, non-sensate flaps such as the cross-fingered flaps were the initial reconstructive methods commonly used for fingertip injury and the realization of the importance of sensation led to use the sensory pulp as reconstructive modality.<sup>5</sup> Other reconstructive options for finger tip reconstruction include bony shortening and primary repair, skin or composite grafts, local (such as neurovascular island pedicle flap or cross-finger flap), regional (ie: groin flap), and free flaps.<sup>6</sup> Because of the many reconstructive methods available, decision making process of fingertip injuries can often be

challenging. The many reconstructive methods mentioned as some options have drawbacks such as non-aesthetic appearance, the need to shorten the finger, persistent pain, hypersensitivity, cold intolerance, paresthesia, soft tissue atrophy, absence of nail or nail deformity, joint stiffness, and decreased power grip.<sup>6</sup> Here we present three cases of finger tip injuries all of whom had undergone the free toe pulp neurovascular free flap reconstruction.<sup>1</sup>

Numerous classification systems and algorithms have been proposed according to different bases and modifications. Lister(1991) devised algorithm based on questions, Ishikawa et al.(1990) classified according to distal digital amputation levels and divided into zones based on nail, Elshahy(1997) similarly based on distal amputation levels and used the nail as the basis of classification, while Hirase(1997) based on arterial anastomosis.<sup>7</sup> A new classification for fingertip injuries, namely the PNB classification system, were devised on the basis of the TNM classifications used for malignant disease. Analogous to the approach used in the TNM classification, the new classification originates from the fact that there are three structures comprising the finger tip: the soft tissue, the nail and its supporting structures. The PNB stands for Pulp, Nail and Bone. Because of the numerical nature of the system, quantification and statistical analysis of data has become much easier.<sup>7</sup>

The advantages of free toe pulp transfer has been previously well introduced through Morrison (1992)<sup>8</sup> in that it provides durable cover which can withstand wear and tear, enables non-slip palmar grip, provides not only protective sensation but also tactile and two-point discrimination sensation which allows fine motor movements with minimal donor site morbidity.<sup>8</sup>

On the other extreme, the disadvantages of this particular method of operation can be ascribed to the disadvantages of any type of free

flap: in that it requires elaborate microsurgical environment and close postoperative flap monitoring although there have been reported documentations of surgery done only under loupe magnification.

## OPERATIVE TECHNIQUE

Under general anesthesia, the patient is placed on the operation table in supine position with arm abducted. A pneumatic tourniquet is applied at the upper arm. Then upper limb and ipsilateral lower leg is prepared and draped. After designing the margins for debridement of the soft tissue defect, complete exsanguination of the arm is done using rubber strips. The pneumatic tourniquet is inflated up to 300 mmHg and rubber strip are removed. Debridement is done using number 15 blade scalpel and sharp Metzenbaum scissors. Using pieces of latex glove as a template, pattern is duplicated by placing the piece on top of the raw surface and tracing it with Gentian Violet solution and a sharp wooden pick. The acquired replicated pattern is intricately cut with fine scissors. The raw surface is then covered temporarily with wet Bosmine-saline mixed solution (Bosmine:normal saline=1:10) soaked gauze to prevent further bleeding. Next, flap design is made by tracing the replica on the 2<sup>nd</sup> toe. A back-cut for pedicle is drawn proximally in a zig-zag pattern in order to minimize wound contracture. Under loupe magnification, the flap is harvested from the radial aspect of the 2<sup>nd</sup> toe including the lateral dorsal digital artery and nerve as the neurovascular pedicle. To minimize donor site morbidity, the skin of the dorsal aspect and the lateral counterpart of the second toe along with the metacarpophalangeal joint is preserved. This enables the donor site to be closed primarily later during the procedure. Dissection is carried out proximally and radially after identifying the vascular pedicle. After clamping the vascular pedicle and nerve, flap is harvested and irrigated with heparin to prevent

clot formation then covered with warm saline soaked gauze while preparing microsurgery. Under  $\times 40$  magnification with surgical microscope, end-to-end anastomosis of the the identified proper palmer digital artery of the finger and dorsal digital artery of the 2<sup>nd</sup> toe is done using #10-0 nylon sutures. Then the nerves are anastomosed in a similar manner at a fascicular level. The tourniquet is deflated to check circulation. Irrigation with lidocaine and papaverine is done. Flap inseting is done and primary repair is done layer by layer using #5-0 vicryl sutures and #5-0 nylon. A silastic drain is inserted to prevent hematoma.

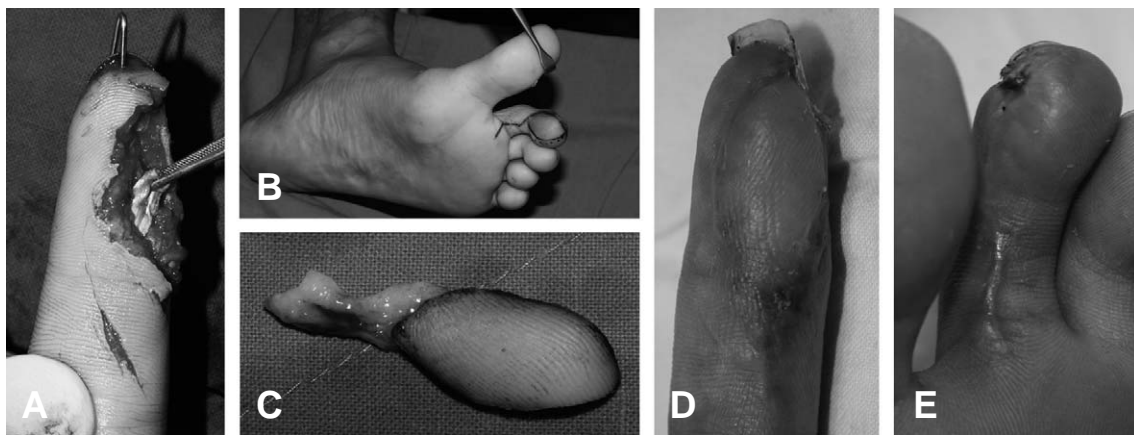
## II. Case

### CASE 1

A 27 year old male patient without any past medical history sustained a finger tip amputation injury at the left 2<sup>nd</sup> finger and a deep laceration wound at the Left thumb while handling an electrically powered saw. He was admitted to the emergency department where immediate administration of intravenous antibiotics was initiated. For proper management, he was relocated to the operation theater where debridement, arteriorrhaphy, tenorrhaphy and K-wire

fixation followed by composite tissue replantation was done. Although hyperbaric oxygenation therapy was prompted beginning on postoperative day 1, total necrosis of composite tissue was evident on day 14. After discarding the fully necrotized composite tissue, aggressive debridement was done followed by daily saline soaked wet gauze dressing. A vaseline gauze was placed above the saline soaked dressing to prevent water from evaporating. The toe pulp transfer was scheduled on postoperative day 21. Under general anesthesia tourniquet was applied. The size of the soft tissue defect measured  $2.5 \times 1.7$  cm. Design was made at the donor site medial volar aspect of the 2<sup>nd</sup> Lt. toe. After tourniquet inflation up to 300mmHg, flap elevation was carried out while preserving the neurovascular bundle. The length of the vascular pedicle measured 2 cm.

The harvested toe pulp free flap was placed on the raw surface and end-to-end anastomosis of the palmar digital artery and the medial plantar artery was done under the surgical microscope. The remaining raw surface was covered with Hyalomatrix<sup>®</sup> which was later to be removed and replaced with skin graft. Although tingling sensation was evident, two point discrimination sensation has not yet returned both in terms of static and dynamic. Finger weakness and function



**Fig. 1.** [CASE 1] 27 year old male patient (A) Debridement and intraoperative identification of neurovascular bundle, (B) Donor site design: 2<sup>nd</sup> toe, (C) 2nd toe pulp free flap after harvest, (D) Recipient site postoperative day 19, (E) Donor site postoperative 1 month.

returned to the level enough to do daily usual activities(Fig. 1).

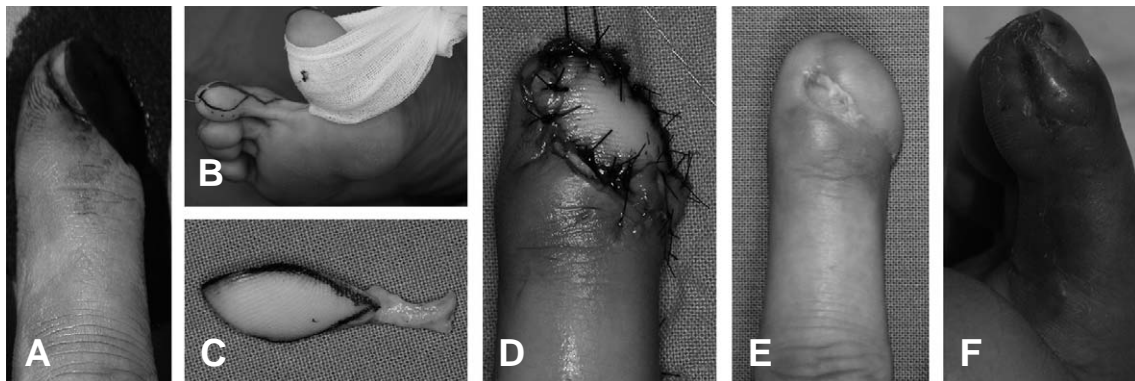
### CASE 2

A 47 year old female sustained mechanical injury to her Rt. 3<sup>rd</sup> finger and was admitted to the emergency department. Massive amount of irrigation with normal saline followed by intravenous antibiotic administration was done. She was then relocated to the operation theater. On gross examination, the soft tissue defect spanned the whole finger nail involving the volar, medial and dorsal part of the finger tip obliquely. Size of the defect was 1×1.5 cm. Radiographic studies showed no evidence of bone involvement. The finger was urgently derbided. Although measures to maximize viability of the free flap was done such as intravenous administration of prostaglandin derivative (Eglandin<sup>®</sup>) and hyperbaric oxygenation of the tissue with localized single chamber oxygenation, near-total flap necrosis was observed at postoperative day 7. The pulp flap transfer was done on postoperative day 12 after removing the necrotized flap. Design was made at the medial aspect of the right 2<sup>nd</sup> toe and flap elevation was carried out similar to that of CASE1. Likewise, the remaining soft tissue defect was also covered with skin harvested from the sole of the right foot. Salvage procedure

through intravenous administration of Eglandin<sup>®</sup> was done due to congestion starting from postoperative day 2 to day 4. Stitches were removed 2 weeks postoperatively. The newly replanted 2<sup>nd</sup> toe pulp flap survived without any complications such as flap congestion or hematoma. Although tingling sensation was evident, two point discrimination sensation has not yet returned both in terms of static and dynamic. Finger weakness and function returned to the level enough to do daily usual activities. After six months, the patient had undergone nailbed-plasty(Fig. 2).

### CASE 3

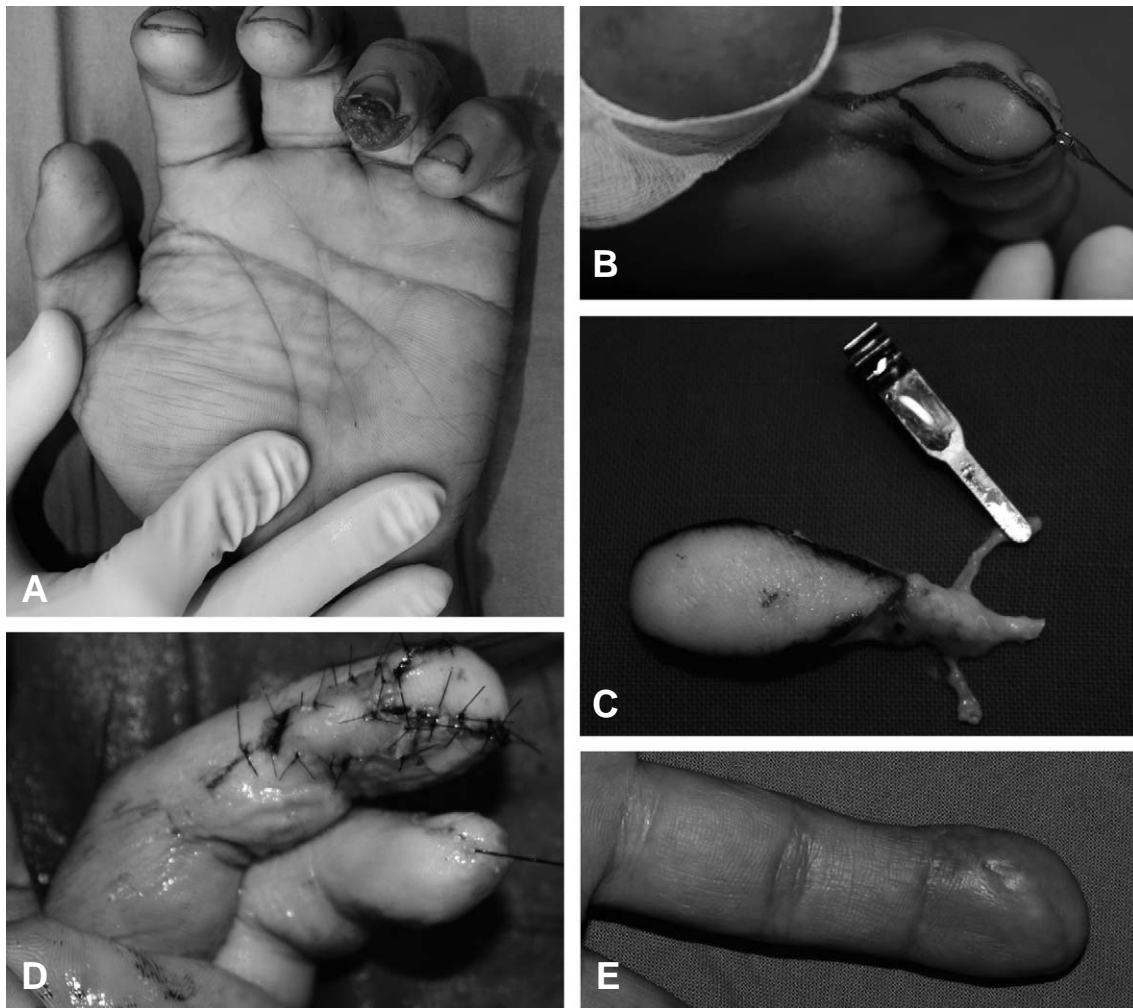
A 29 year old male labor worker sustained mechanical injury to his left 4<sup>th</sup> finger tip and was admitted to the emergency department. Upon arrival, massive amount of irrigation with normal saline followed by intravenous antibiotic administration was done. He did not bring the amputated piece with him. He was taken to the operation theater for emergency operation. On physical examination, the soft tissue defect did not involve the finger nail but part of the volar aspect and tip of the finger including the pulp defect was noted. Size of the defect was 2.5×1.7 cm. Radiographic studies showed no evidence of bone involvement. Immediate debridement followed by venous free flap eleva-



**Fig. 2.** [CASE 2] 47 year old female patient sustained 3<sup>rd</sup> finger tip injury (A) Debridement immediately after injury, (B) Donor site design: 2<sup>nd</sup> toe, (C) After flap harvest including the neurovascular bundle, (D) 2<sup>nd</sup> toe pulp partial harvest immediately after surgery, (E) Recipient site postoperative 1 month (F) Donor site Postoperative 1 month.

tion was done from the ipsilateral 2<sup>nd</sup> toe and arteriorrhaphy was done under the microscope. For precautionary measures, procedures to maximize viability of the free flap was done including intravenous administration of prostaglandin derivative (Eglandin<sup>®</sup>) and hyperbaric oxygenation of the tissue with localized single chamber oxygenation. Although the patient was a heavy smoker with 15 pack years of cigarette smoking, he was kept at quit state postoperatively during his entire hospitalization. Because the amputated piece was discarded by the patient, pulp flap transfer was done immediately after the accident. Design was made at the medial aspect of the left 2<sup>nd</sup> toe and flap elevation was carried

out in a similar fashion to CASE 1 and CASE 2. Likewise, the remaining soft tissue defect was also covered with skin harvested from the sole of the right foot. Salvage procedure through intravenous administration of Eglandin<sup>®</sup> was done due to congestion starting from postoperative day 2 to day 4. Stitches were removed 2 weeks postoperatively. The newly replanted 2<sup>nd</sup> toe pulp flap survived without any complications. Although tingling sensation was evident, two point discrimination sensation has not yet returned both in terms of static and dynamic. Finger weakness and function returned to the level enough to do daily usual activities(Fig. 3).



**Fig. 3.** [CASE 3] 29 year old male patient sustained 4th finger tip injury (A) Debridement immediately after injury, (B) Donor site design: 2<sup>nd</sup> toe pulp partial harvest (C) after flap harvest including the neurovascular bundle clamped with micro-clamp, (D) Immediately after surgery, (E) Recipient site postoperative 1 month.

### III. Discussion

Reconstruction of the finger tip using 2<sup>nd</sup> toe pulp tissue transfer has some advantages such as its relatively strong resistance to wear and tear and that it provides a non-slip palmar grip. Although first introduced in the 1960's, Buncke and Rose first described resurfacing of the fingertip with free toe pulp in 1979,<sup>14</sup> and not many surgeons have opted this procedure thereafter.<sup>9</sup> Hence, a limited amount of literature exists describing this particular method of operation. However, its usefulness and advantages have been recognized more recently commensurate with the evolution of knowledge of the topographic anatomy of the vascular pedicle at the finger and toe area. Furthermore, the pulp of the fingers are unique in that it is composed of glabrous skin which harbors a unique pattern of grooves and ridges that contributes to more stable pinch and grasp by increasing the surface area for contact. According to Sir Harold Gillie's surgical principle, "replace like with like" it is best to reconstruct the finger tip pulp with the most similar donor to achieve maximum functional and aesthetic result.<sup>3,10</sup> Although there are proven advantages of this flap, it is not suitable in certain conditions such as in pressure injection injuries or crush injuries. The indication and contraindications of microsurgical free toe pulp reconstruction has been well described by Deglise and Botta in 1991.<sup>3</sup> Indications include cutaneous defects involving more than 2/3 of the pulp of the first three fingers of the hand, trauma involving several fingers, pulp defect with painful neuroma, or in conditions which cosmesis is a concern especially in young women. On the other hand, contraindications are in crush injuries or high energy injection injuries where the extent of injury is uncertain or in patients with advanced age.<sup>3</sup>

### Surgical Pitfalls

When choosing the donor site it is best to choose the ipsilateral foot as the donor site. However, preoperative assessment of the vascular pedicle should be confirmed through hand held Doppler ultrasound device. In addition, it is wise to have a systematic knowledge of the sequence of surgical procedures prior to surgery since microsurgical technique is required in both the recipient and donor site. A two team approach can save operative time. However, when circumstances do not allow, one team approach is possible as such was the case for the authors. We had to apply tourniquet to both recipient and donor site at the outset of surgery. After thoroughly exploring and indentifying the neurovascular pedicle of the finger, we approached the donor toe until full harvest and primary repair. We then came back to the finger and finished the rest of the surgical procedures. It is important to note that the tourniquet must be applied until anastomosis of the vessels and nerves are finished. If the surgeon is not experienced enough, a single team approach might delay the ischemia-reperfusion time which may influence flap survival outcome.

### Postoperative Management

The postoperative management is equally important as is successful operative techniques. Immediate postoperative care should be undertaken in order to ensure flap survival because of the tenuous blood supply of the vascular pedicle like in any kind of free flap operation. Lest the neurovascular bundle be displaced or bent so as to compromise perfusion, a moderate form of fixation such as splinting may help. Sometimes depending on surgeon's preference, a Kirschner<sup>®</sup> wire may be inserted into the finger tip. The authors believe that this can become too invasive causing further soft tissue injury or compromise the blood supply. Therefore we used only finger

splints for fixation. Flaps are monitored on the basis of physical examination. Both the recipient and donor sites are kept elevated to minimize edema and help venous drainage. Splinting should be kept for at least 2 weeks. In addition, proper fluid therapy along with institution of broad spectrum antibiotics (3<sup>rd</sup> generation cephalosporin) is necessary. In cases where contamination is obvious, an aminoglycoside gentamycin should be added intravenously. One of the most important reasons this particular method of reconstruction was chosen lies on the fact that the homodigital 2<sup>nd</sup> partial toe pulp transfer provides 2 point discrimination sensation. Therefore sensory reeducation program is necessary and should be done on patient recuperation which is begun simultaneously with early passive motion therapy on postoperative day 10. Weight bearing of the donor foot is not done until postoperative 4 weeks.

### Sensory Return

It was once postulated that sensory return may be explained through several possible mechanisms: increased cortical representation area, increased peripheral cutaneous receptors, and better use of skin surface. Many of the documentations support the process of reinnervation rather than regeneration as possible mechanism. According to Jabaley, there is no correlation between the number of sensory corpuscles and sensory return.<sup>11</sup> Dellon has also pointed out that there are no visual Meissner's corpuscles after nerve repair.<sup>12</sup>

Moreover, sensory reeducation cannot increase the density of receptors and nerve fibers such as the Meissner's corpuscle. In fact the number actually is decreased after replantation.<sup>13</sup> Despite this fact the sensory function improves after sensory reeducation program perhaps due to cortical reorganization caused by increased neural activity in the postcentral gyrus.<sup>10</sup>

The exact timing of sensory return may vary

from one individual to another depending on the extent of injury and individual time to recovery. According to Buncke and Rose, the successful return of two point discrimination required 10 or more months after surgery,<sup>14</sup> and in the studies done by Foucher et al, 8 or more months were needed for sensory return.<sup>15</sup>

Therefore, it seems quite obvious that sensory function has not yet returned in both of the cases in our study. Aforementioned statistics suggests that it would take much longer follow up periods to perform two point discrimination tests whether it be static or dynamic. Although passive exercise was educated in each patient any quantitative sensory evaluation was deemed not necessary since time was too early at the moment. Among these many advantages, it is the satisfactory sensory recovery that makes this mode of reconstruction a desirable choice. There are two types of fibers responsible for perception of touch: slowly adapting fibers and rapidly adapting fibers. The former is associated with static two-point discrimination test and Semmes-Weinstein test while the latter is associated with moving two-point discrimination test and vibration sense.<sup>6</sup>

The partial toe pulp transfer has more advantages than drawbacks in that it leaves minimal donor site morbidity and minimal scar at easily hidden area while securing a sensate and durable flap that enables the patient to recuperate quickly. Furthermore, the treads of the pulp derived from the toe has many similarities and function such as a firm prehensile grasp that even augments grasping power. The authors report our three successful cases as case report since this procedure has not been so commonly employed throughout the past several decades and the fact that it seems quite worthwhile mentioning the high success rates today owing to the advancements in the knowledge in the anatomy, technical skills and instruments compared to the past. The major limitation to this study is the short follow up period and relatively



small number of cases compared to other studies.

## REFERENCES

- 1) Wei F-C: Chapter 52. In Green DP (ed): *Green's operative hand surgery*. fifth ed, Philadelphia, Pa., Elsevier/Churchill Livingstone, 2005, p 1835.
- 2) Lee DC, Kim, JS, Ki, SH, Roh, SY, Yang, JW, Chung, KC: Partial second toe pulp free flap for fingertip reconstruction. *Plast Reconstr Surg* 121: 899, 2008.
- 3) Deglise B, Botta, Y: Microsurgical free toe pulp transfer for digital reconstruction. *Ann Plast Surg* 26: 341, 1991.
- 4) Le-Quang C: [Forum: reconstruction of the traumatic thumb in practice...the surgeon passes!]. *Ann Chir Plast Esthet* 38: 437, 1993.
- 5) Satish C, Nema, S: First dorsal metacarpal artery islanded flap: A useful flap for reconstruction of thumb pulp defects. *Indian J Plast Surg* 42: 32, 2009.
- 6) Ozcelik IB, Tuncer, S, Purisa, H, Sezer, I, Mersa, B, Kabakas, F, Celikdelen, P: Sensory outcome of fingertip replantations without nerve repair. *Microsurgery* 28: 524, 2008.
- 7) Evans DM, Bernardis, C: A new classification for fingertip injuries.[erratum appears in J Hand Surg [Br] 2000 Aug;25(4):414 Note: Bernadis, C [corrected to Bernardis, C]]. *Journal of Hand Surgery-British Volume* 25: 58, 2000
- 8) Morrison WA: Thumb and fingertip reconstruction by composite microvascular tissue from the toes. *Hand Clin* 8: 537, 1992
- 9) Logan A, Elliot, D, Foucher, G: Free toe pulp transfer to restore traumatic digital pulp loss. *Br J Plast Surg* 38: 497, 1985
- 10) Lin CH, Lin, YT, Sassu, P, Wei, FC: Functional assessment of the reconstructed fingertips after free toe pulp transfer. *Plast Reconstr Surg* 120: 1315, 2007
- 11) Jabaley ME, Burns, JE, Orcutt, BS, Bryant, M: Comparison of histologic and functional recovery after peripheral nerve repair. *Journal of Hand Surgery-American Volume* 1: 119, 1976.
- 12) Dellon AL: Reinnervation of denervated Meissner corpuscles: a sequential histologic study in the monkey following fascicular nerve repair. *Journal of Hand Surgery-American Volume* 1: 98, 1976.
- 13) Wei FC, Carver, N, Lee, YH, Chuang, DC, Cheng, SL: Sensory recovery and Meissner corpuscle number after toe-to-hand transplantation. *Plast Reconstr Surg* 105: 2405, 2000.
- 14) Buncke HJ, Rose, EH: Free toe-to-fingertip neurovascular flaps. *Plastic & Reconstructive Surgery* 63: 607, 1979.
- 15) Foucher G, Merle, M, Maneaud, M, Michon, J: Microsurgical free partial toe transfer in hand reconstruction: a report of 12 cases. *Plastic & Reconstructive Surgery* 65: 616, 1980.