

# Acrodysostosis Associated with Symptomatic Cervical Spine Stenosis

Jung Min Ko<sup>1</sup>, Kyu Sung Kwack<sup>2</sup>, Sang-Hyun Kim<sup>3</sup> and Hyon-Ju Kim<sup>1</sup>

<sup>1</sup>Department of Medical Genetics, <sup>2</sup>Department of Radiology, <sup>3</sup>Department of Neurosurgery, Ajou University School of Medicine, Suwon, Korea

Acrodysostosis is an extremely rare disorder characterized by short fingers and toes with peripheral dysostosis, nasal hypoplasia, and mental retardation. We report a 16-year-old Korean boy with acrodysostosis who had characteristic clinical features and cervical spine stenosis manifested by neurologic symptoms. On presentation, he complained of difficulty in raising his arms, and suffered from intermittent pain and weakness in both upper extremities. He had short stature and dysmorphic facial features, including a broad, depressed nasal bridge, small, upturned nose, bilateral epicanthal folds, and mild hypertelorism. Moderate mental retardation and sensorineural hearing loss in both ears were also present. Radiological findings included broad, short metacarpals and phalanges with cone-shaped epiphyses, bilateral Madelung deformities, hypertrophied first metatarsals, and thickening of the calvarium. Magnetic resonance imaging findings included stenosis of the cervical spine, platybasia with compression into the cervicomedullary junction, and downward displacement of the cerebellar tonsils. Here, we report a case of acrodysostosis with symptoms and signs of cervical spinal stenosis first in Korea. If it is diagnosed in the early stages, possible life-threatening complications, including spinal canal stenosis, can be managed properly and permanent neurologic sequelae might be avoided. Therefore, it is important to consider acrodysostosis in the differential diagnosis of peripheral dysostosis.

**Key Words:** Acrodysostosis, Peripheral dysostosis, Spinal canal stenosis, Madelung deformity, Brachymelia

## Introduction

Acrodysostosis (OMIM 101800) is an extremely rare skeletal dysplasia characterized by abnormally short and malformed bones of the hands and feet, nasal hypoplasia, and mental retardation. Additional manifestations include

short stature, and abnormalities of the spine, mandible, and skull<sup>1, 2)</sup>. It was first described by Maroteaux and Malamut in 1968<sup>3)</sup>, and since then, around 50 cases have been reported in the literature. The etiology and prevalence are still unknown. Most cases are sporadic, although some cases have occurred in families, suggesting autosomal dominant inheritance<sup>4-7)</sup>.

Spinal canal stenosis has been underappreciated in this syndrome, despite the loss of normal caudal widening of the lumbar interpediculate distance seen on spine radiographs in the early reports<sup>1, 2)</sup>. Recently, it has been demonstrated that spinal canal stenosis is a common radiologic finding in acrodysostosis<sup>8)</sup>; however, most of these findings are asymptomatic, with only a few reported

접 수: 2010년 10월 26일

수정본접수: 2010년 11월 30일

게재승인일: 2010년 12월 10일

게재일: 2010년 12월 31일

**Correspondence:** Hyon-Ju Kim

Department of Medical Genetics, Ajou University School of Medicine, San 5, Wonchon-dong, Yeongtong-gu, Suwon, 443-721, Korea  
Tel: +82-31-219-4522, Fax: +82-31-219-4521  
E-mail: genetics@kornet.net

cases manifesting neurologic symptoms, including numbness, intermittent claudication, back pain, or paraparesis<sup>8–10</sup>.

Although there has been just one report of Acrodysostosis in Korea, any sign of spinal stenosis was not documented in this previous report. Here, we report a 16-year-old Korean boy who suffered from acrodysostosis with characteristic clinical features which have been reported in other cases, along with neurologic symptoms due to stenosis in the cervical spine, as documented by imaging studies first in Korea<sup>11</sup>.

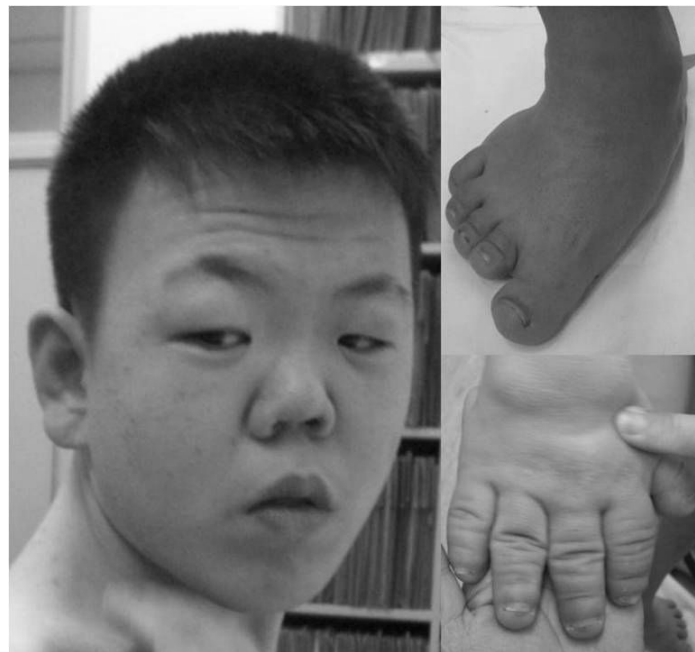### Case report

A 16-year-old boy with dysmorphic facial features, psychomotor delay, and short stature was referred for evaluation. He also complained of difficulty in raising his arms, and suffered from intermittent pain and weakness in both upper extremities.

He was born to a 27-year-old primigravida mother

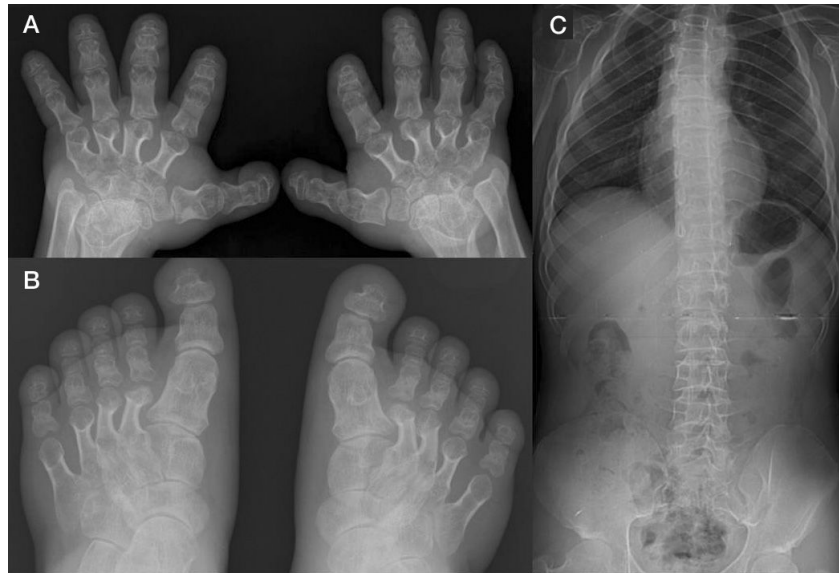
and 33-year-old father, and weighed 2.9 kg at birth. Both parents were healthy and there is no history of consanguinity. After birth, he was noted to be dysmorphic with maxillonasal hypoplasia and brachydactyly. A chromosome analysis performed at 6 months of age showed a normal 46,XY karyotype. He started to walk by 18 months of age and to speak simple words by 8 years. At 7 years of age, he underwent nasal septum reconstruction because of severe snoring and chronic maxillary sinusitis.

Physical examination findings included, height 155 cm (<3<sup>rd</sup> percentile), weight 57 kg (25–50<sup>th</sup> percentile) and head circumference 57 cm (75–90<sup>th</sup> percentile). He had dysmorphic facial features with a broad, depressed nasal bridge and a small, upturned nose, despite surgical reconstruction. He also had maxillary hypoplasia, a tendency to keep his mouth open, dental malocclusion, mild ocular hypertelorism, and bilateral epicanthal folds (Fig. 1). However, an unusual iridal color change was not seen. His fingers and toes were very short and stubby,



**Fig. 1.** Facial features including a broad, depressed nasal bridge, a small, upturned nose, bilateral epicanthal folds, and mild hypertelorism, and brachymelia of the hand and the foot are seen in this photograph.

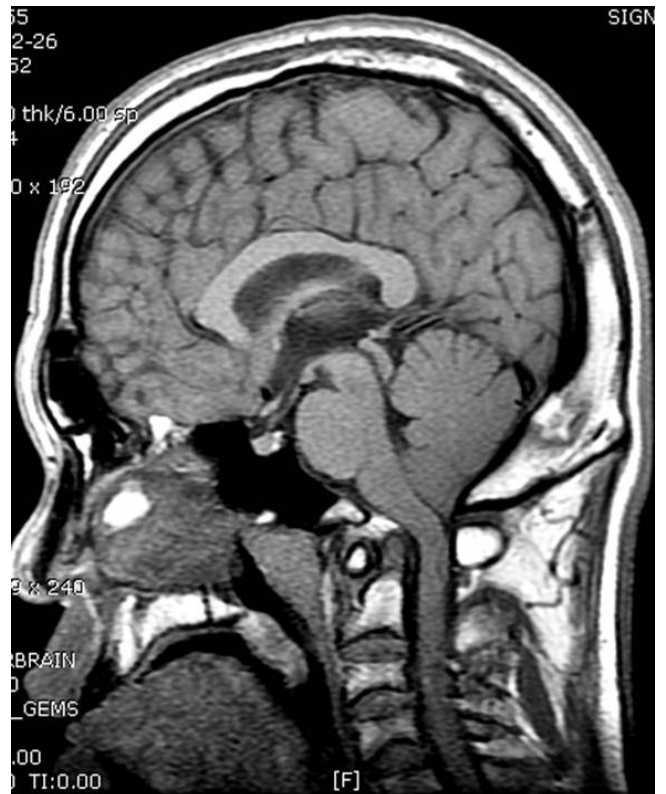
\*We obtained formal permission to publish this facial photograph from the parents.



**Fig. 2.** Skeletal radiographs show (A) shortened and stubby metacarpals and phalanges with Madelung deformities of both wrist joints, (B) shortened metatarsals and phalanges with hyperplasia of the first ray, and (C) loss of caudal widening of vertebral interpediculate distances.

and the skin of the dorsum of the hands was wrinkled. His forearms and lower legs were disproportionately shorter than his arms and upper legs. The range of motion was limited in both shoulders and elbows. He had developed secondary sexual characteristics, and his sexual maturity rating was Tanner stage 4. Muscle strength was determined to be grade 4 in both upper extremities, and deep tendon reflexes were normal. There were no sensory changes in his upper extremities.

A detailed skeletal survey showed broad, short metacarpals and phalanges with cone-shaped epiphyses (Fig. 2). He had Madelung deformity of the wrists, and the radial epiphyses had fused, and his bone age was older than 19 years. He also had significantly hypertrophied first metatarsals. His skull was distinctly brachycephalic, and the calvarium was thickened. Loss of normal caudal widening of the lumbar interpediculate distance was seen on spine radiographs. Basal skull and cervical spine magnetic resonance imaging findings included spinal canal stenosis, platybasia with angulation and compression into the cervicomedullary junction, and downward displacement of the cerebellar tonsils (Fig. 3). Spinal canal stenosis in acrodysostosis tends to



**Fig. 3.** MRI shows thickening of the calvarium, platybasia with angulation and compression into the cervicomedullary junction, downward displacement of the cerebellar tonsil, and evidence of cervical spinal stenosis.

progress with time. If neurological symptoms and signs will aggravate or the spinal canal lesion will progress in the follow-up MR imaging after six months, we plan to decompress of the lesion surgically.

Moderate mental retardation was identified by neuropsychiatric evaluation. The results of repeated karyotyping and array comparative genomic hybridization using bacterial artificial chromosome (BAC) clones (MACArray Karyo 1440 BAC-chip, Macrogen, Korea) were normal. His laboratory findings were unremarkable, with normal serum calcium, phosphorus, alkaline phosphatase, and parathyroid hormone levels. The results of pure tone audiometry revealed mild to moderate sensorineural hearing loss in both ears (right ear=30 dB, left ear=45 dB).

## Discussion

Diagnosis of acrodysostosis is entirely dependent on a combination of clinical and radiologic features. The most unique and constant feature of acrodysostosis is generalized peripheral dysostosis. Severe shortening of the metacarpals, metatarsals, and phalanges are caused by prematurely-fused, cone-shaped epiphyses. Nasal hypoplasia and mental retardation are other cardinal features<sup>3)</sup>. However, none of these findings is by itself diagnostic. Because acrodysostosis and pseudohypoparathyroidism both show shortening of the tubular bones in the hands and feet, short stature, and mental retardation, these syndromes can be confused<sup>8, 12)</sup>. Whereas abnormalities in calcium and parathyroid hormone metabolism are seen in patients with pseudohypoparathyroidism, they are not recognized in patients with acrodysostosis. Some previous studies have looked for abnormalities in the alpha subunit of the signal transducing protein (Gs-alpha) and *GNAS1* gene, which is the well known cause of most forms of pseudohypoparathyroidism<sup>8, 12)</sup>.

However, in patients with acrodysostosis, no sequence variations have been found, and normal Gs-alpha bioactivity has been observed. These results indicate

that acrodysostosis is etiologically distinct from pseudohypoparathyroidism. Our patient's laboratory findings were normal, and the findings of forearm brachymelia, first ray hyperplasia, and absence of soft tissue calcification were important distinguishing features that helped differentiate the diagnosis of acrodysostosis from other peripheral dysostosis syndromes including pseudohypoparathyroidism.

Our patient was also found to have calvarial thickening with platybasia, bilateral Madelung deformities, and spinal canal stenosis. Although these are not consistent findings in most patients with acrodysostosis<sup>1, 2)</sup>, severe complications associated with these findings can occur and progress over time. Spinal canal stenosis in particular seems to be anatomically present in early childhood and may cause neurologic symptoms and permanent neurologic sequelae in patients with acrodysostosis<sup>8)</sup>. There have been some reports that spinal canal stenosis is a common complication in acrodysostosis<sup>8, 9)</sup>. In one previous study, 5 (38.5%) of 13 patients with spinal canal stenosis required decompressive laminectomies. It has also been suggested that in patients with acrodysostosis, the frequency and severity of spinal stenosis are similar to what is seen in achondroplasia patients<sup>8)</sup>. Therefore, spinal cord symptoms must be evaluated in all acrodysostosis patients. The symptoms associated with spinal canal stenosis have been reported primarily for the lumbosacral region; however, some cases, including our patient, have complained of pain and weakness in their upper extremities, suggestive of cervical spine stenosis<sup>8, 9)</sup>.

The distal radius and ulna can be malformed in acrodysostosis. In one previous report, 3 of 20 (15.0%) patients had wrist joint abnormalities and 2 patients had Madelung deformities<sup>1)</sup>. Our patient also had bilateral Madelung deformities of both wrist joints. It may be caused by a growth arrest on ulnar and volar side of the distal radius and articulation of the radial and dorsal distal radial physis with the entire proximal row of carpal bones, and it results in pain and decreased range of

motion<sup>1)</sup>.

More than 75% of reported patients have had intellectual deficits, with a mean intelligence quotient of 61<sup>1, 2)</sup>. Moderate mental retardation was also identified in our patient. Although associated neurologic defects, including hydrocephalus, optic nerve atrophy, seizures, choreoathetosis, and strabismus have been reported in some acrodysostosis patients<sup>1)</sup>, to date, no explanation for mental retardation is apparent.

Recurrent otitis and/or hearing loss have been noted in more than 50% of patients<sup>1, 2)</sup>, and bilateral sensorineural hearing loss was also identified in our patient. One case was reported with wide internal auditory meati, and this condition is sometimes encountered in children with total deafness<sup>13)</sup>. However, this finding has also been observed in a few normal subjects, and further studies are necessary to confirm the clinical significance of this sign.

Most reported cases have occurred sporadically; however, an autosomal dominant inheritance pattern was seen in more than 10% of patients, and there seems to be variable expressivity of clinical phenotypes even in familial cases<sup>4, 7, 14)</sup>. Owing to the rarity of acrodysostosis, the natural course of the disorder and underlying genetic background have not yet been clarified. It is thought that a genetic defect in an unidentified gene is the cause of this disorder; however, we did not discover any abnormalities in the results from a repeated karyotype analysis and an array comparative genomic hybridization test.

The patient we report shows very characteristic phenotypic features and closely resembles the original and the reported descriptions of acrodysostosis<sup>3)</sup>. Although this disorder is extremely rare, it is important to consider acrodysostosis in the differential diagnosis of peripheral dysostosis. If diagnosed in the early stages, possible life-threatening complications, including spinal canal stenosis, can be managed properly and permanent neurologic sequelae might be avoided. The natural history and genetic background need to be further studied in order to provide appropriate management and genetic counseling.

## 국문초록

선단이골증(acrodysostosis)은 매우 드문 골격계 이형성 질환의 하나로, 말단골 이형성을 보이는 짧은 손가락과 발가락, 코뼈의 저형성 및 정신 지체를 그 특징으로 한다. 본 증례에서 저자들은 전형적인 임상 양상을 보이면서 신경 증상 및 징후와 경추관 협착을 동반한 선단이골증 16세 남아를 경험하여 보고하고자 한다. 환이는 양쪽 상지의 간헐적인 통증과 위약감을 호소하였으며 양팔을 높이 들어올리는 것이 불가능함을 주소로 내원하였다. 신체 검진상 저신장을 보였으며 넓으면서도 낮은 콧등, 작고 위로 들려 올라간 코끝, 양쪽 눈의 안쪽 눈구석 주름 및 경한 안양안격리증 등 특징적 안면 소견을 보였다. 신경심리검사상 중등도의 정신지체가 확인되었으며 청력검사상 양측의 신경성 난청 소견이 동반되어 있었다.

방사선학적 검사에서는, 원뿔 모양의 골단을 보이는 넓으면서도 짧은 중수골 및 지골, 양측 전외부의 마델룽 변형(Madelung deformity), 과형성된 첫 번째 중족골과 두꺼워진 두개골이 확인되었다. 뇌 및 척추 자기공명영상검사에서는 경추관 협착, 경추-연수 접합부의 압박을 동반한 편평두개저 및 소뇌 편도의 하방 이동 소견을 보였다. 선단이골증에서 동반되는 경추관 협착증은 시간이 지남에 따라 진행되는 경향을 보이므로, 6개월 후 추적 영상검사에서 진행되는 소견을 보이거나 증상이나 징후가 악화될 경우에는 수술적 압박술을 실시할 계획이다.

본 증례는 선단이골증의 국내 보고로는 두 번째이나, 경추관 협착증의 증상 및 징후를 동반한 선단이골증의 첫 번째 보고이다. 선단이골증에서의 척추관 협착증은 시간이 지남에 따라 진행되는 증상이며 심각한 합병증이 초래될 수 있기 때문에, 특징적 임상 양상을 보이는 환자를 조기에 진단할 수 있다면 이러한 합병증에 대한 적절한 치료로서 치명적인 신경학적 후유증의 발생을 피할 수 있다. 따라서, 말단골의 이형성을 보이는 환자의 중요한 감별 질환 중 하나로 선단이골증은 반드시 고려되어야 할 것이다.

## References

- 1) Robinow M, Pfeiffer RA, Gorlin RJ, McKusick VA, Renuart AW, Johnson GF, et al. Acrodysostosis. A syndrome of peripheral dysostosis, nasal hypoplasia, and mental retardation. *Am J Dis Child* 1971;121:195-203.

- 2) Butler MG, Rames LJ, Wadlington WB. Acrodysostosis: report of a 13-year-old boy with review of literature and metacarpophalangeal pattern profile analysis. *Am J Med Genet* 1988;30:971-80.
- 3) Maroteaux P, Malamut G. Acrodysostosis. *Presse Med* 1968;76:2189-92.
- 4) Steiner RD, Pagon RA. Autosomal dominant transmission of acrodysostosis. *Clin Dysmorphol* 1992;1:201-6.
- 5) Niikawa N, Matsuda I, Ohsawa T, Kajii T. Familial occurrence of a syndrome with mental retardation, nasal hypoplasia, peripheral dysostosis, and blue eyes in Japanese siblings. *Hum Genet* 1978;42:227-32.
- 6) Frey G, Martin J, Dietel K. Acrodysostosis--an autosomal dominant peripheral dysplasia. *Kinderarztl Prax* 1982;50:149-53.
- 7) Hernandez RM, Miranda A, Kofman-Alfaro S. Acrodysostosis in two generations: an autosomal dominant syndrome. *Clin Genet* 1991;39:376-82.
- 8) Graham JM Jr., Krakow D, Tolo VT, Smith AK, Lachman RS. Radiographic findings and Gs-alpha bioactivity studies and mutation screening in acrodysostosis indicate a different etiology from pseudohypoparathyroidism. *Pediatr Radiol* 2001;31:2-9.
- 9) Sezer N, Sutbeyaz ST, Koseoglu F, Aras M, Akin C. Adult case of acrodysostosis with severe neurologic involvement. *J Back Musculoskelet Rehabil* 2009;22:125-9.
- 10) Hamanishi C, Nagata Y, Nagao Y, Sohen S, Tanaka S. Acrodysostosis associated with spinal canal stenosis. *Spine (Phila Pa 1976)* 1993;18:1922-5.
- 11) Lee SH, Oh CW, Kim KS, Kim KB. A Case of Acrodysostosis. *J Korean Pediatr Soc* 1995;38:133-7.
- 12) Wilson LC, Oude Luttikhuis ME, Baraitser M, Kingston HM, Trembath RC. Normal erythrocyte membrane Gs alpha bioactivity in two unrelated patients with acrodysostosis. *J Med Genet* 1997;34:133-6.
- 13) Reiter S. Acrodysostosis. A case of peripheral dysostosis, nasal hypoplasia, mental retardation and impaired hearing. *Pediatr Radiol* 1978;7:53-5.
- 14) Sheela SR, Perti A, Thomas G. Acrodysostosis: autosomal dominant transmission. *Indian Pediatr* 2005;42:822-6.