

전완부에 발생한 내혈관 유두내피 증식증(Masson 혈관종)

경희대학교 의학전문대학원 동서신의학병원 정형외과학교실,
아주대학교 의과대학 정형외과학교실*

전영수 · 유기형 · 김상환*

내혈관 유두내피 증식증 (Masson 혈관종)은 피부나 피하조직에 주로 발생하는 흔하지 않은 양성 혈관 병변으로 혈관 내피세포의 과도한 증식으로 발생할 수 있다. 이 질환은 정상 또는 기형적인 혈관에서 일차적으로 발생할 수 있으며, 혈관종, 화농성 육아종, 또는 림프관종 등과 동반될 수 있다. 혈관내 유두상 내피성 과형성증은 임상적, 조직학적으로 저등급의 혈관 육종으로 오인하여 진단, 치료할 수 있으므로 감별하여야 한다. 저자는 27세 환자가 전완부의 종물을 주소로 내원하여 상기 병명으로 진단한 예를 경험하였기에 문헌 고찰과 함께 이를 보고하는 바이다.

색인 단어: 전완부, 내혈관 유두 내피 증식증, Masson 혈관종

Introduction

Intravascular papillary endothelial hyperplasia may show a pattern similar to angiosarcoma due to the vascular non-neoplastic endothelial proliferation process³⁾. Intravascular papillary endothelial hyperplasia has been termed in 1923 by Masson⁸⁾ as "Vegetant intravascular hemangioendothelioma", and since Clerkin and Enzinger¹⁾ reported it as "intravascular papillary endothelial hyperplasia", it has been known as such term most commonly until now²⁾. The authors experienced a case of intravas-

cular papillary endothelial hyperplasia developed in the forearm, and thus we report the case with a review of the literature.

Case report

A 27 years old male patient was admitted for a mass in the left forearm. The mass was discovered for the first time 2 years ago, and the size was increased gradually and slowly, and recently, pain and the reduction of the range of motion of the wrist joint were developed. At the time of admission, in the left distal forearm area, a

*통신저자: 전 영 수

서울특별시 강동구 상일동 149

경희대학교 동서신의학병원 정형외과

Tel: (02) 440-6155, Fax: (02) 440-7475, E-mail: mozart13@khu.ac.kr

firm mass in the size of a fist of child was palpated, and at the percussion, the patient complained tingling sensation in the distal area. Loss of weight was not shown, and in the past history, there was no special trauma or past medical history. And there was no skin discoloration, and in blood test, abnormal results were not shown. In simple radiographs, a mass shadow in soft tissues and small round calcification finding were observed (Fig.1). In magnetic resonance imaging, a round shaped soft tissue tumor, 3.3×1.9×4.7 cm in size, in the distal forearm area was shown (Fig.2). On T1 weighted images, it is shown as low intensity sig-

nals in the hemorrhagic area mixed with

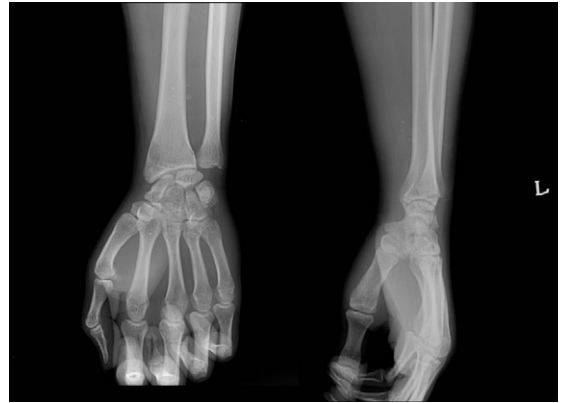

Fig. 1. Plain radiograph shows soft tissue swelling with small round calcification in distal forearm.

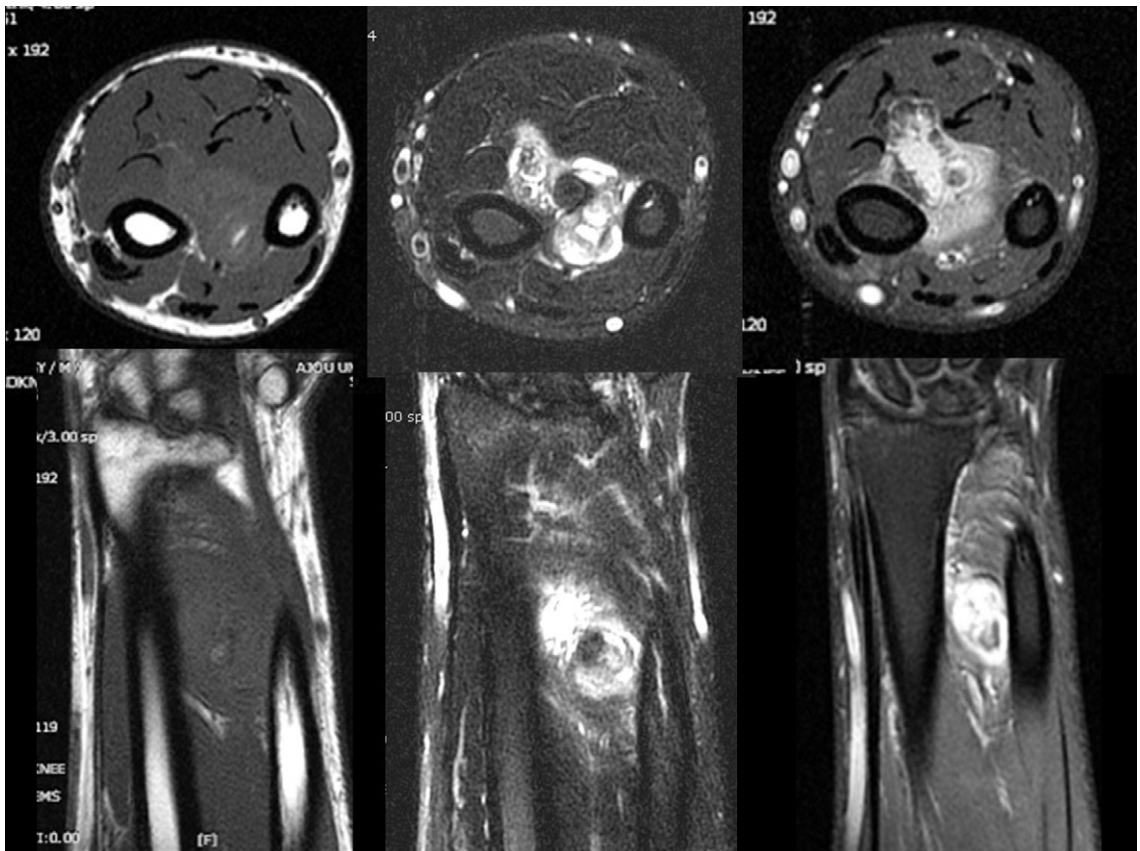

Fig. 2. Magnetic resonance imaging shows the mass showed nodular high signal intensiteis on precontrast images, heterogenous enhancement was noted after contrast enhancement. The center of mass seemed to be located among flexor pollicis longus, flexor digitorum and interosseous membrane.

high intensity signals, and on T2 weighted images, it appears as low signal intensity reflecting thrombus, etc., and the internal septum with low signal intensity may be observed. On axial & coronal images, there was spindle shaped soft tissue mass seen among the distal forearm. The mass showed nodular high signal intensities on precontrast images, heterogenous enhancement was noted after contrast enhancement. The center of mass seemed to be located among flexor pollicis longus, flexor digitorum and interosseous membrane. Neurovascular bundle of anterior interosseous artery and nerve seemed to be abut or closely located to that mass. The possibility of soft tissue mass originated from neurovascular bundle was suspected with focal hemorrhages. We performed incisional biopsy for diagnosis and for differential diagnosis with soft tissue sarcoma. Histologically, the papillae are lined by single layer of plump endothelial cells surrounding a collagenized core. There is no multilayering, tufting, solid areas, necrosis and little or no atypia. There is lit-

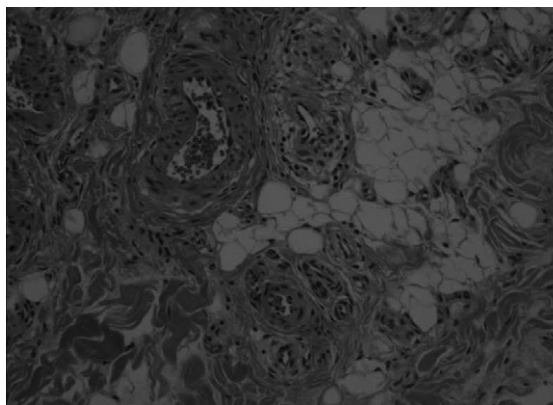


Fig. 3. These papillae are lined by single layer of plump endothelial cells surrounding a collagenized core. There is no multilayering, tufting, solid areas, necrosis and little or no atypia. There is little evidence of mitoses (Hematoxylin and Eosin, $\times 200$).

tle evidence of mitoses. It was diagnosed as intravascular papillary endothelial hyperplasia (Masson's hemangioma) (Fig.3). We performed marginal excision as treatment. In surgical findings, the mass was located between the Flexor hallucis longus, the Flexor digitorum fundus and the interosseous membrane, and a reddish blue colored mass covered with a capsule was extracted (Fig.4). After surgery, the tingling sensation and pain of the forearm disappeared, and until the two years follow up observation, special complications or recurrence findings were not shown.

Discussion

Intravascular papillary endothelial hyperplasia is not a common disease, it could be developed in any areas of body, and it is developed primarily in the dermal area or subcutaneous tissues of the head, neck, fingers and trunk⁶⁾. In 1923, Masson⁸⁾ considered intravascular papillary endothelial hyperplasia as benign neoplasia and termed as "Vegetant intravascular hemangioendothelioma", and reported for the first time, and 1932, Herschen⁴⁾ reported it as intravas-

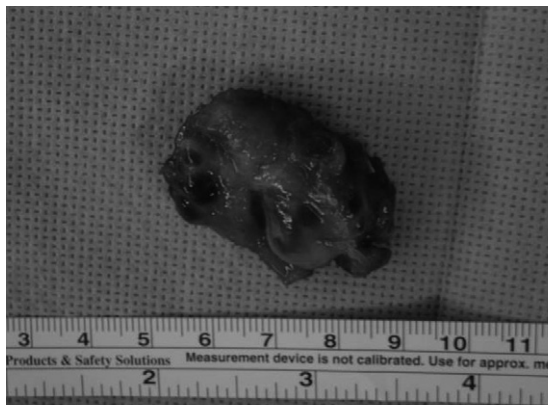

Fig. 4. Dark-red colored mass was removed from distal forearm.

cular hyperplasia rather than neoplasia, and subsequently it was introduced as various terms such as endothelial hemangiomas, intravenous vascular hyperplasia, Masson pseudo hemangiosarcoma, Masson hemangioma, etc.^{4,8)}. In 1976, Clerkin and Enzinger¹⁾ reported it as "Intravascular papillary endothelial hyperplasia", and subsequently, until now, it is most widely known as such term²⁾. In Korea, intravascular papillary endothelial hyperplasia was reported Yi et al.⁶⁾ and Hong et al.⁵⁾, and it consists of 2~4% of hemangioma developed in the skin or soft tissues. Primarily, it is developed in the finger most prevalently, and it occurs preferentially in the order of the head, neck, forearm, etc. It is a small hard mass on dermal layer, and the skin may be discolored to red color or blue color in some cases⁶⁾. The pathological mechanism of this disease has not been elucidated yet, nonetheless, according to studies conducted until now, the concept of a different variation of thrombus tissues has been accepted. It has been reported that such endothelial hyperplasia is stimulated by bFGF (basic fibroblast growth factor) released from macrophage accumulated in the area received trauma, intravascular papillary endothelial hyperplasia is induced. Such endothelial cells produce more bFGF, and thus such process is augmented by a positive feedback process⁷⁾.

Hashimoto et al.³⁾ classified intravascular papillary endothelial hyperplasia to three types. First, it is the primary or intravascular type (56 %), and hyperplasia of the normal blood vessel, and primarily hyperplasia within the vein. Second, it is the secondary or mixed type (40 %) and it is originated from preceding abnormalities such as hemangioma, arteriovenous malformation,

lymphangioma, etc., and third, it is the extravascular type (4%) and it is developed within hematoma. The difference of prognosis according to the classification is not clear. It has been shown that intravascular papillary endothelial hyperplasia is not associated with age, nonetheless, the mixed type is known to be developed in the older age group, and it occurs slightly more frequently in the female²⁾ (M:F = 1:1.2). The mean size is smaller than 2 cm, nevertheless, the extravascular type is larger and shows average 4.5 cm in size, and it occurs as solitary primarily, nevertheless, it may be developed as multicentric occasionally. The history of trauma was shown in only 4% cases²⁾.

At the time of the diagnosis of intravascular papillary endothelial hyperplasia, in histological findings, the endothelial layer is formed by normal endothelial cells, endothelial hyperplasia is a benign papillary pattern, abnormality of cells is not shown, and other than hemorrhage, malignant characteristics are not shown^{5,9)}. As the differential diagnosis, the differentiation from other hemangiomas is required. The significant of this disease is that it is discovered as a mass and thus it may be misdiagnosed as angiosarcoma by histological results³⁾. The papillary growth pattern of this disease is similar to the tufting of angiosarcoma, nevertheless, angiosarcoma has the characteristic that it is not limited in the intravascular area, and the histological findings of infiltrative growing, the polygonal pattern of cells, frequent mitosis, and necrotic area shown in angiosarcoma are not shown in intravascular papillary hyperplasia²⁾. In addition, it is required to differentiate from Kaposi's sarcoma, capillary hemangioma, and hemangioendothelioma⁹⁾. Radiologically, on simple radiographs, in cases with heman-

gioma or phlebolith in the vicinity, consequent results may be shown, and due to the influence of mass, erosion in adjacent bones may be observed⁶⁾. In magnetic resonance imaging, diverse results are observed, and in cases developed in the four extremities, on T1 weighted images, it is shown as low intensity signals in the hemorrhagic area mixed with high intensity signals, and on T2 weighted images, it appears as low signal intensity reflecting thrombus, etc., and the internal septum with low signal intensity may be observed. For its diagnosis or treatment, surgical excision is performed, and after radical excision, it almost never recurs, nevertheless, in partial resection cases, it may recur⁶⁾. For recurred cases or partial resection cases, radiation therapy may be attempted⁹⁾.

We reported a case of intravascular papillary endothelial hyperplasia developed in the forearm that could be misdiagnosed as sarcoma in soft tissues clinically, and it is considered that it must be differentiated always from angiosarcoma histologically.

REFERENCES

- 1) **Clarkin KP, Enzinger FM:** Intravascular papillary endothelial hyperplasia. Arch Pathol Lab Med, 100: 441-441, 1976
- 2) **Clifford PD, Temple HT, Jorda M, Marecos E:** Intravascular papillary endothelial hyperplasia (Masson's tumor) presenting as a triceps mass. Skeletal Radiol, 33: 421-425, 2004.
- 3) **Hashimoto H, Daimaru Y, Enjoji M:** Intravascular papillary endothelial hyperplasia: a clinicopathologic study of 91 cases. Am J Dermatopathol, 5: 539-545, 1983.
- 4) **Henschen P:** L'endovasculite proliferante thrombopoietique dans la lesion vasculaire locale. Ann Anat Pathol, 9:113-121, 1932
- 5) **Hong SK, Min H:** Intravascular papillary endothelial hyperplasia (Masson's Hemangioma) of the liver: A new hepatic lesion. J Korean Med Sci, 19: 305-308, 2004
- 6) **Lee SH, Suh JS:** Intravascular papillary endothelial hyperplasia of the extremities: MR imaging finding with pathologic correlation. Eur Radiol, 14: 822-826, 2004.
- 7) **Levere SM, Barsky SH, Meals RA:** Intravascular papillary endothelial hyperplasia: a neoplastic "actor" representing an exaggerated attempt at recanalization mediated by basic fibroblast growth factor. J Hand Surg[Am], 19: 559-564, 1994.
- 8) **Masson P:** hemangioendotheliome vegetant intravasculaire. Bull Soc Anat Paris, 93: 517-523, 1923.
- 9) **Stoffman MR, Kim JH:** Masson's vegetant hemangioendothelioma: case report and literature review. Journal of Neuro-Oncology, 61: 17-22, 2003

Abstract

**Intravascular Papillary Endothelial Hyperplasia
(Masson's hemangioma) Presenting as a Forearm Mass**

Young Soo Chun, M.D., Kee Hyung Rhyu, M.D., Sang Hwan Kim, M.D.*

*Department of Orthopaedic Surgery, East-West Neo Medical Center,
School of Medicine, Kyung Hee University, Seoul, Korea,
Department of Orthopaedic Surgery, School of Medicine,
Ajou University, Suwon, Gyeonggi-do, Korea**

Intravascular papillary endothelial hyperplasia (IPEH, Masson's hemangioma) is a non neoplastic reactive endothelial proliferation most commonly located in the skin or subcutaneous tissues although it has been reported in multiple locations throughout the body. This lesion may arise from malformed or normal vessels primarily, and may develop with hemangioma, pyogenic granuloma, or lymphangioma. This lesion, though benign, is clinically important since it may present as a mass and be confused histologically with angiosarcoma. The authors report a 27 years old patient with a mass in his forearm which results in intravascular papillary endothelial hyperplasia.

Key Words: Forearm, Intravascular papillary endothelial hyperplasia, Masson's hemangioma

Address reprint requests to

Young Soo Chun, M.D., Ph.D.
Department of Orthopaedic Surgery, East-West Neo Medical Center,
School of Medicine, Kyung Hee University, 149, Sangil-dong, Gangdong-gu, Seoul, Korea
TEL: 82-2-440-6155, FAX: 82-2-440-7475, E-mail: mozart13@khu.ac.kr