

Granulocytic Sarcoma in the Leg Mimicking Hemorrhagic Abscess

Song-Mee Cho¹, Won-Hee Jee²

Granulocytic sarcoma is a rare extramedullary tumor composed of immature granulocytic precursors. Usually, granulocytic sarcoma is seen in association with acute myeloid leukemia, or other myeloproliferative disorders. Rarely, it may manifest as a primary presentation before the onset of systemic disease in acute myeloid leukemia. The clinical suspicion of granulocytic sarcoma based on imaging findings is important for the management of the patient especially when systemic disease of acute myeloid leukemia is not confirmed as in our case. We report the MR findings of a granulocytic sarcoma in the left leg mimicking hemorrhagic abscess in a patient with acute myeloid leukemia. We believe that MRI can be a helpful diagnostic method of making a differential diagnosis of granulocytic sarcoma in a patient with leukemia, and this can be done by analyzing the signal intensity and the enhancement pattern.

Index words : Granulocytic sarcoma
Magnetic resonance (MR)
Acute myeloid leukemia

Introduction

Granulocytic sarcoma is also termed chloroma, myelosarcoma or extramedullary myeloid cell tumor, and it is a localized extramedullary neoplasm composed of immature myeloid precursor cells. Although granulocytic sarcoma is most commonly encountered in patients with acute and chronic myeloid leukemia, it may manifest as a primary presentation before the onset of systemic disease in acute myeloid leukemia (1, 2). If occurring in patients without manifestations of

acute myeloid leukemia, the tumor, granulocytic sarcoma often indicates the development of systemic disease within several months (mean 10.5 months) (2). The clinical suspicion of granulocytic sarcoma based on imaging findings is important for management of the patient before the confirmation of the systemic disease of acute myeloid leukemia.

Case Report

A 52-year-old woman presented with pain and swelling of the left lower leg. When the patient visited

JKSMRM 13:88-92(2009)

¹Department of Radiology, St. Paul's Hospital, College of Medicine, The Catholic University of Korea, Seoul, Korea

²Department of Radiology, Seoul St. Mary's Hospital, College of Medicine, The Catholic University of Korea, Seoul, Korea
Received; March 10, 2009, revised; April 30, 2009, accepted; May 12, 2009

Corresponding author : Won-Hee Jee, M.D., Department of Radiology, Seoul St. Mary's Hospital, College of Medicine, The Catholic University of Korea, 505 Banpo-dong, Seocho-gu, Seoul 137-701 South Korea
Tel. 82-2-2258-6238 Fax. 82-2-2258-1457 E-mail: whjee@catholic.ac.kr

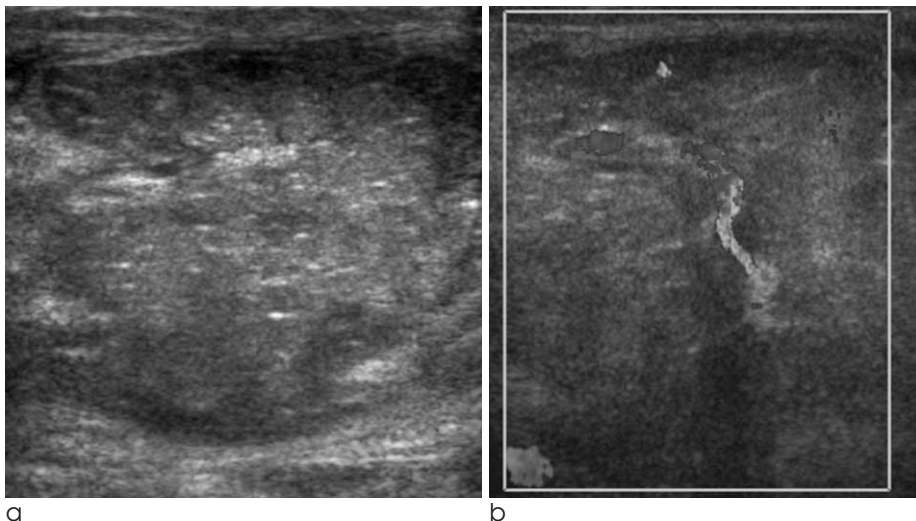


Fig. 1. A 52-year-old woman with pain and swelling of the left lower leg. (a) Longitudinal sonogram shows a well-defined heterogeneously hyperechoic mass in the medial head of left gastrocnemius muscle with small echogenic foci within it. (b) On color Doppler image abundant color flows are noted in the mass.

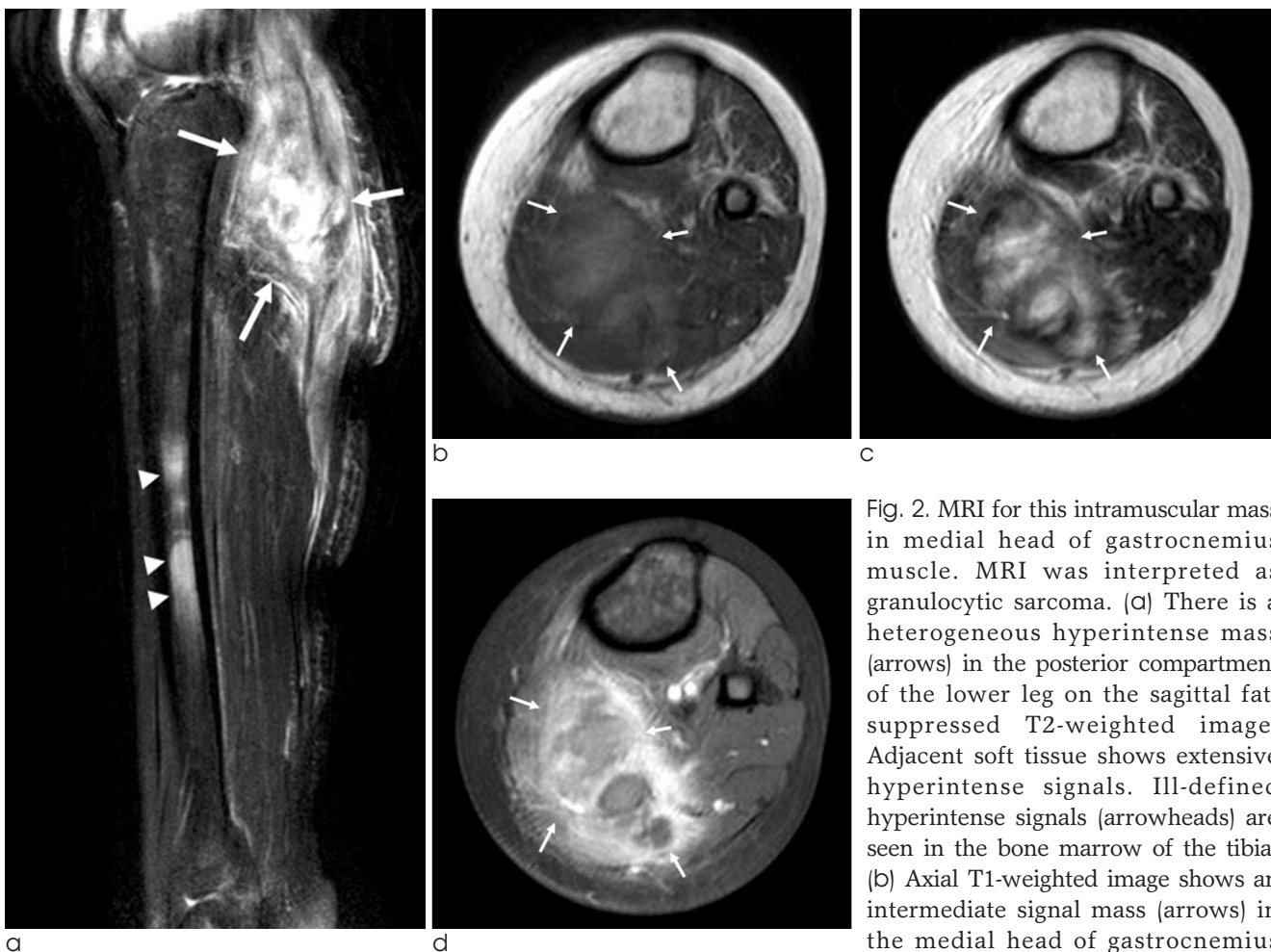

Fig. 2. MRI for this intramuscular mass in medial head of gastrocnemius muscle. MRI was interpreted as granulocytic sarcoma. (a) There is a heterogeneous hyperintense mass (arrows) in the posterior compartment of the lower leg on the sagittal fat-suppressed T2-weighted image. Adjacent soft tissue shows extensive hyperintense signals. Ill-defined hyperintense signals (arrowheads) are seen in the bone marrow of the tibia. (b) Axial T1-weighted image shows an intermediate signal mass (arrows) in the medial head of gastrocnemius muscle. (c) The mass (arrows) is heterogeneously mildly hyperintense on axial T2-weighted image. Ill-defined, hyperintense signal is seen in the adjacent muscle. (d) On contrast-enhanced fat-suppressed T1-weighted image, it shows peripheral, thick, irregular contrast enhancement with central non-enhancing areas (arrows).

our hospital she was referred from another hospital with a clinical suspicion of acute myeloid leukemia. Her blood revealed marked decreased number of red blood cells and platelets. Trauma and venous thrombosis were excluded. Hemorrhagic abscess was suspected based on clinical and sonographic findings. On sonogram, there was a relatively well-defined mass in medial head of left gastrocnemius muscle. It was heterogeneously hyperechoic with small echogenic foci within it (Fig. 1a). On color and power Doppler images, abundant color flows were observed in the mass (Fig. 1b). Adjacent gastrocnemius medial head was enlarged with diffuse increased echogenicity. MRI revealed an ill defined intramuscular mass in the posterior compartment with heterogeneously intermediate to hyperintense signal on T1-weighted images and heterogeneously hyperintense signal on T2-weighted

images (Fig. 2). Extensive hyperintense signals were seen in the adjacent muscles in the posterior compartment of the lower leg on T2-weighted images. On contrast-enhanced fat-suppressed T1-weighted images, peripheral irregular contrast enhancement with a large central non-enhancing area was noted in the mass. Bone marrow signal was heterogeneously hypointense on T1-weighted images and heterogeneously hyperintense on T2-weighted images, and showed heterogeneous enhancement on contrast-enhanced fat-suppressed T1-weighted images. Differential diagnosis of granulocytic sarcoma and hemorrhagic abscess was made on MRI. Hemorrhagic abscess was excluded because signal in the mass was not so high but mild on T2 weighted images. Due to the thrombocytopenia biopsy was delayed in a worry of massive bleeding. Ultrasound-guided biopsy was

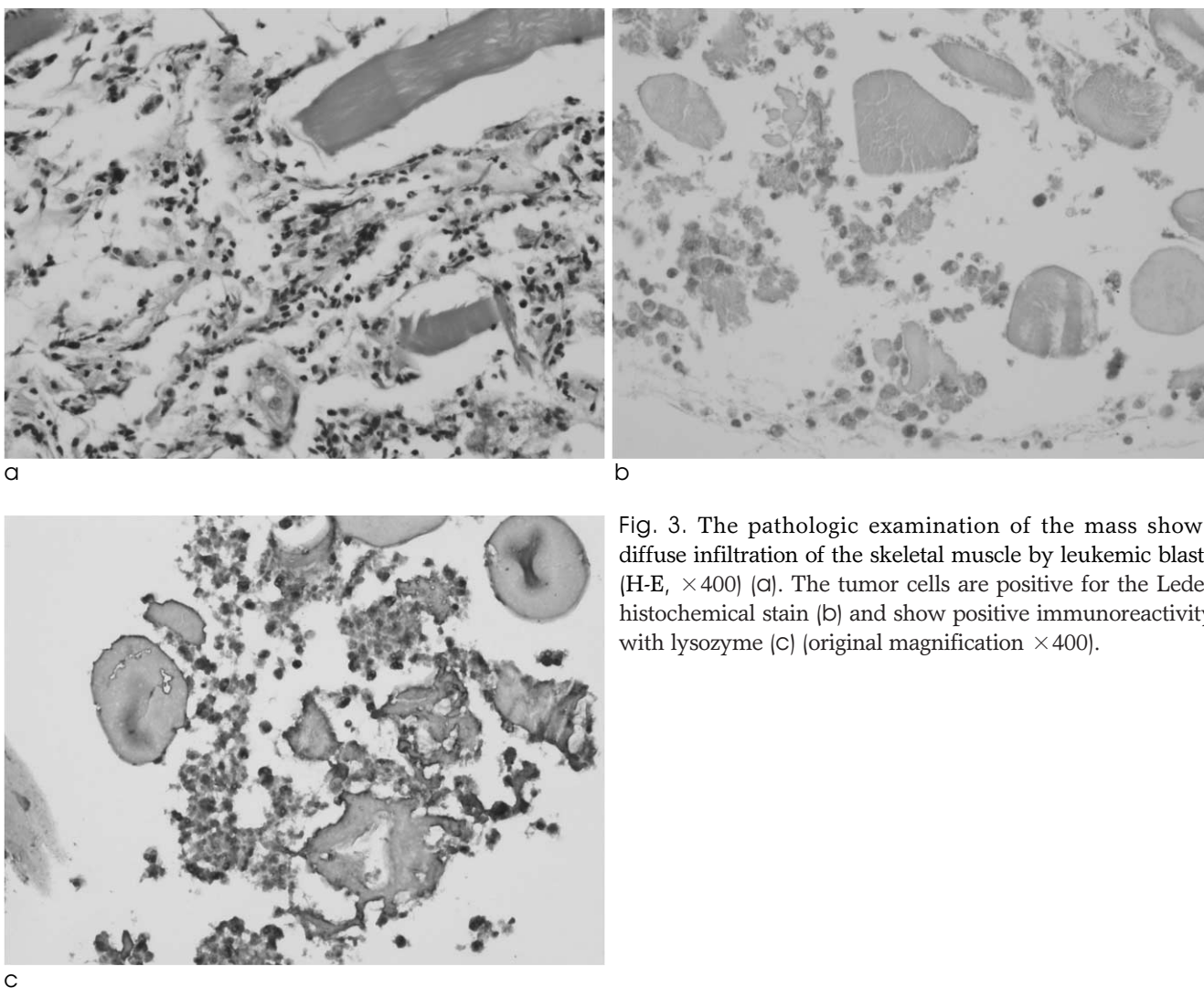


Fig. 3. The pathologic examination of the mass shows diffuse infiltration of the skeletal muscle by leukemic blasts (H-E, $\times 400$) (a). The tumor cells are positive for the Leder histochemical stain (b) and show positive immunoreactivity with lysozyme (c) (original magnification $\times 400$).

performed in the mass lesion after the platelet count was elevated more than 50000/L. Following ultrasound-guided biopsy of the mass bone marrow biopsy was done, and the diagnosis of acute myeloid leukemia was made. The bone marrow aspirates reveal about 66% of nucleated elements are blasts showing medium to large sized, round to oval shaped, finely chromatinated nuclei with or without distinct nucleoli, and scanty to moderate amount of blue cytoplasm. They express MPO, CD33, CD117, CD7, CD38, CD34 and HLA-DR on the immunophenotyping study and showed positive reaction to peroxidase stain. The pathologic examination of the mass lesion of the leg showed diffuse infiltration of the skeletal muscle by leukemic blasts (Fig. 3). The tumor cells were positive for the Leder histochemical stain and showed positive immunoreactivity with lysozyme.

Discussion

Since originally described in 1811 by Burns (3), a granulocytic sarcoma has been reported to involve various anatomic locations. It has a predilection in the subcutaneous tissue, orbit, paranasal sinuses, lymph nodes, and bones in a decreasing order (4). Although granulocytic sarcoma can involve any soft tissue of the body, the reports of appearances in the extremities without involvement of the trunk are rare (5, 6).

On the review of literatures the image findings of granulocytic sarcoma can be summarized into three types of lesions mimicking solid tumor, the lesion mimicking abscess or less commonly, the lesion mimicking myositis (4, 6). Image features akin to those seen in abscesses are reported in the various organs such as muscle, brain, paraspinal, skin, lung, or uterine cervix (5-7). Imaging characteristics of these lesions akin to those seen in abscesses were irregular peripheral enhancement with non-enhancing center of the lesion on contrast-enhanced images. Usually, granulocytic sarcomas akin to abscess were isointense to muscle signal on T1-weighted images and mildly hyperintense on T2-weighted MR images (5, 6). Ooi et al. (6) suggested that the presence of mild hyperintensity of the lesion on T2-weighted images which is not so intense as that of the cystic portion of the abscess may help differentiate granulocytic sarcoma from abscess. The signal intensity of granulocytic sarcoma on T2-

weighted images is presumably due to high levels of myeloperoxidase, an iron-containing enzyme which is normally found in white blood cells (8). In our case, granulocytic sarcoma showed heterogeneous, mixed low and high signals in the lesion on T1- and T2-weighted images which was quite similar to the previous report by Ko et al. (7).

Awareness of this form of acute myeloid leukemia and the imaging characteristics described would be helpful with the inclusion of granulocytic sarcoma in the differential diagnosis. We should discriminate granulocytic sarcoma from an abscess, hematoma, lymphoma, and the other malignant lesions that can occur in patients with leukemia in order to initiate prompt and appropriate therapy and to avoid any unnecessary operation (6, 7, 9, 10). In contrast to the malignant soft tissue tumors, there is a long segmental involvement of a soft tissue in our case of granulocytic sarcoma. Lymphoma also shows the characteristic findings of long segmental involvement of soft tissue as well as involvement of bone marrow like leukemia. However, in leukemia, the subcutaneous and skin involvements are not usually seen, which frequently observed in the lymphoma (9, 10).

In summary, the clinical suspicion of granulocytic sarcoma based on imaging findings is important for the management of the patient especially when the systemic disease of acute myeloid leukemia is not confirmed as in our case. MR findings of a granulocytic sarcoma in the left leg in a patient with acute myeloid leukemia are presented here. MRI can be a helpful diagnostic method of making a differential diagnosis of granulocytic sarcoma in a patient with leukemia.

References

1. Meis JM, Butler JJ, Osborne BM, Manning JT. Granulocytic sarcoma in nonleukemic patients. *Cancer* 1986;58:2697-2709.
2. Yamauchi K, Yasuda M. Comparison in treatments of nonleukemic granulocytic sarcoma: report of two cases and a review of 72 cases in the literature. *Cancer* 2002;94:1739-1746.
3. Burns A. Observations on the surgical anatomy of the head and neck. Edinburgh, Scotland: Tomas Bryce, 1811:364-366.
4. Pui MH, Fletcher BD, Langston JW. Granulocytic sarcoma in childhood leukemia: imaging features. *Radiology* 1994;190:698-702.
5. Scheipl S, Leithner A, Radl R, Beham-Schmid C, Ranner G, Linkesch W, et al. Myeloid sarcoma presenting in muscle-

tissue of the lower limb: unusual origin of a compartment-syndrome. Am J Clin Oncol 2007;30:658-659.

6. Ooi GC, Chim CS, Khong PL, Au WY, Lie AK, Tsang KW et al. Radiologic manifestations of granulocystic sarcoma in adult leukemia. AJR Am J Roentgenol 2001;176:1427-1431.

7. Ko SW, Kim YK, Jin GY, Lee SY, Kim CS. Granulocytic sarcoma manifested as a parametrical mass mimicking a haemorrhagic abscess: a case report with CT and MR findings. Br J Radiol 2007;80:e128-e130.

8. Parker K, Hardjasudarma M, McClellan RL, Fowler MR, Milner JW. MR features of an intracerebellar chloroma. AJNR Am J Neuroradiol 1996;17:1592-1594.

9. Lee VS, Martinez S, Coleman RE. Primary muscle lymphoma: clinical and imaging findings. Radiology 1997;203:237-244.

10. Eustace S, Winalski C, McGowen A, Lan H, Dorfman D. Skeletal muscle lymphoma: observations at MR imaging. Skeletal Radiol 1996;25:425-430.

대한자기공명영상학회지 13:88-92(2009)

다리에 생긴 출혈성 농양과 유사한 과립구성 육종

¹가톨릭대학교 의과대학 성바오로병원 영상의학과

²가톨릭대학교 의과대학 서울성모병원 영상의학과

조송미¹ · 지원희²

과립세포육종은 골수모세포라 불리는 미성숙 악성 백혈구로 구성된 골수 외 종양이다. 과립세포육종은 보통 급성 골수성 백혈병이나 골수이형성 증후군과 동반되나 드물게 급성 골수성 백혈병의 전신 질환 이전에 초기 발현으로 발병하기도 한다. 저자의 증례에서와 같이 급성 골수성 백혈병 확진 이전의 과립세포육종은 영상 소견이 임상적 의심과 함께 이 질환의 진단과 치료에 중요하다. 이 증례에서 출혈성 농양과 오인 가능한 과립세포육종의 자기공명영상 소견을 보고하고자 한다. 저자는 자기공명영상이 급성 골수성 백혈병 환자에서 농양으로부터 과립세포육종을 감별하는데 도움이 된다고 생각한다.

통신저자 : 지원희, (137-701) 서울특별시 서초구 반포동 505, 가톨릭대학교 의과대학 서울성모병원 영상의학과
Tel. 82-2-2258-6238 Fax. 82-2-2258-1457 E-mail: whjee@catholic.ac.kr