

## TREATMENT FOR IDIOPATHIC MULTIPLE DENTIGEROUS CYSTS: CASE REPORT

Ki-Baek Kim, Seon-Mi Kim, Kyu-Ho Yang, Nam-Ki Choi

*Department of Pediatric Dentistry, Chonnam National University School of Dentistry,  
Dental Research Institute and Second stage of BK21*

### Abstract

Dentigerous cysts generally encompass the crown of an unerupted tooth. These cysts are usually solitary. They are the second most common odontogenic type of cysts following radicular cysts, and are frequently associated with impacted mandibular third molars or maxillary canines.

Most multiple cysts found in the jaw are odontogenic keratocysts associated with the nevoid basal cell carcinoma syndrome, mucopolysaccharidoses and cleidocranial dysplasia. Although a single dentigerous cyst is well documented in the medical literature, including the prevalence, treatment and prognosis, multiple dentigerous cysts without any systemic symptoms is unusual. Furthermore, cases involving both the maxilla and mandible are especially rare.

We present the case of an 11-year-old boy with nonsyndromic multiple dentigerous cysts associated with a mandibular second premolar and a maxillary canine. The treatment was conservative and included marsupialization and eruption guidance. Further follow up is planned to rule out additional problems and the possible identification of a syndrome.

**Key words :** Odontogenic cysts, Dentigerous cyst, Basal cell nevus syndrome.

### I. INTRODUCTION

By definition, a cyst is a pathological cavity that is lined by epithelium and filled with fluid or semi-solid materials<sup>1)</sup>. Usually, the bone of the jaw has epithelium-lined cysts that may result from the inclusion of epithelium along embryonic lines of fusion<sup>2)</sup>. Dentigerous cysts are defined as cysts that originate from the separation of the follicle around the crown of teeth not yet erupted<sup>3)</sup>. Single dentigerous cysts are the second most common type of odontogenic cyst, following radicular cysts<sup>4-6)</sup>. The etiology of these cysts is unknown. There is usually no pain or discomfort associated with the enlargement of

the cysts. However, the osmotic pressure that develops causes continuous bony expansion. This results in asymptomatic facial swelling, facial asymmetry or paresthesia of the inferior alveolar nerve<sup>1-3)</sup>.

The histopathological features of dentigerous cysts include a cavity lined by stratified squamous epithelium, and occasional hyperplasia of the rete ridges in cases with inflamed cysts. Because it can be difficult to distinguish a small dentigerous cyst from a normal or enlarged dental follicle, based on microscopic features alone, the diagnosis should be confirmed by radiology examination. A radiolucent space or lesions surrounding the crown of 3 to 4 mm in diameter are consistent with

교신저자 : 최 남 기

광주광역시 북구 용봉동 300번지 / 전남대학교 치의학 전문대학원 소아치과학교실 / 062-530-5668 / helloworld@hanmail.net

원고접수일: 2008년 07월 18일 / 원고최종수정일: 2008년 12월 04일 / 원고채택일: 2009년 01월 05일

the diagnosis of a dentigerous cyst.

Dentigerous cysts are usually solitary. In most cases with multiple cysts of the jaw they are odontogenic keratocysts associated with basal cell carcinoma; occasionally, they are associated with syndromes such as mucopolysaccharidosis, cleidocranial dysplasia and Maroteaux-Lamy syndrome. Multiple dentigerous cysts are less common in patients who do not have a syndrome or a systemic disease. Furthermore, in the absence of a syndrome or systemic disease, dentigerous cysts on both the maxilla and mandible, at the same time, are rare. The following case illustrates a rare case of multiple dentigerous cysts in both the maxilla and mandible, unilaterally.

## II. Case Report

A 11-year-old boy was referred to the Department of Oromandibulo-facial Surgery, Chonnam National University Hospital, in Gwangju, to evaluate the asymptomatic facial swelling. There were no specific findings on the family, medical and dental history. The patient was diagnosed with multiple jaw cysts involving the permanent maxillary right canine and the mandibular right second premolar by clinical and radiographic examination (Fig. 1, 2-a, b, c). The tentative diagnosis was odontogenic keratocyst and dentigerous cyst. The patient had no additional findings such as mental retardation, developmental delay, skin lesions, or other findings suggestive of a syndrome. The radiological examination of the skull and trunk showed no specific findings such as calcifications, skeletal deformity of the ribs, clavicles, or vertebrae (Fig. 2-d,e). Although the patient was referred to the department of pediatrics and the department of dermatology to rule out systemic diseases such as the nevoid basal cell carcinoma syndrome, no such diagnosis was suspected. A conservative approach

to treatment was adopted with marsupialization during surgery, a biopsy was performed to confirm the diagnosis. The histological findings showed thin non-keratinized stratified squamous epithelium in both lesions (Fig. 3). Therefore, the final diagnosis was confirmed to be dentigerous cysts of the permanent maxillary right canine and mandibular right second premolar. One month after surgery, the patient was referred to the department of pediatric dentistry for oral care and eruption guidance using a space maintainer. Extraction of the primary maxillary right first and second molars and the mandibular second molar was performed, and the affected teeth were guided to erupt with a space maintainer. One year later, osseous tissue was found at the area where the cyst was marsupialized (Fig. 4), and the affected teeth were erupting favorably (Fig. 5). Clinical and radiographic examination is planned for further monitoring.

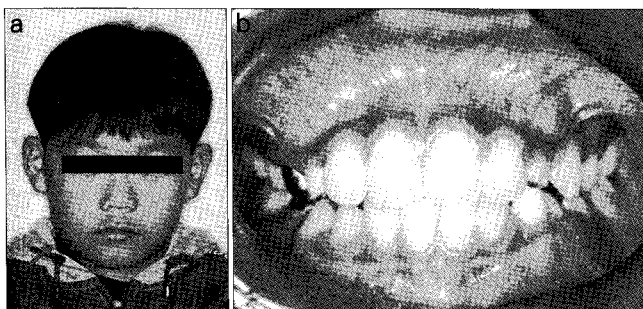


Fig. 1. Photograph at the first visit. (a) extraoral view, (b) intraoral view.

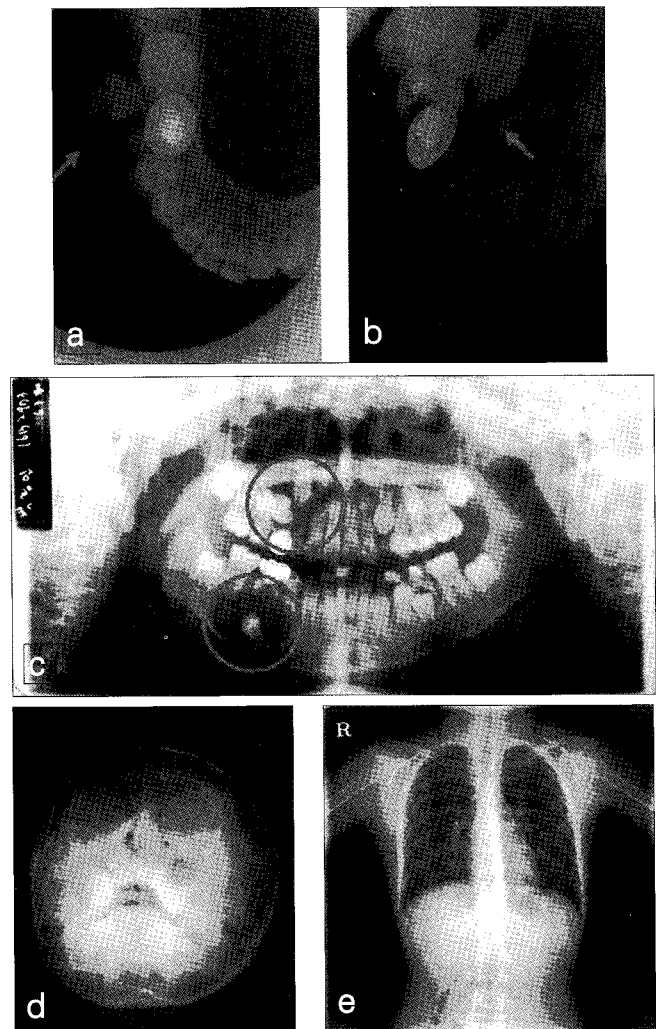
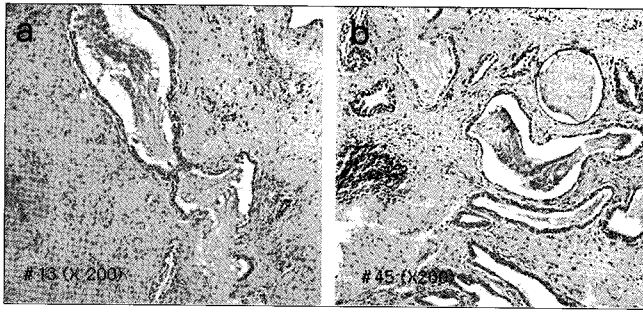
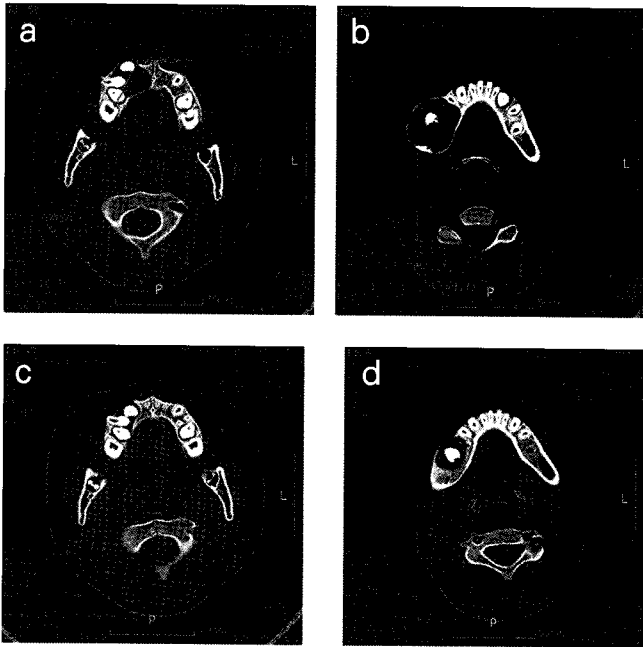


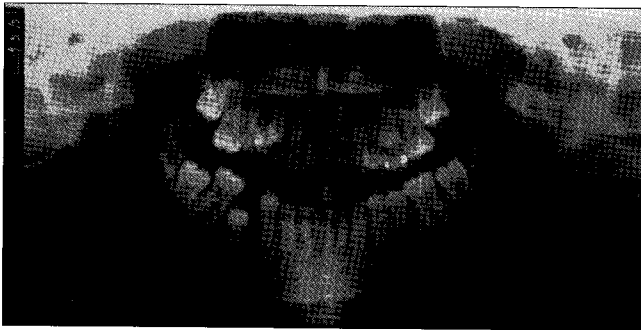
Fig. 2. Radiograph at the 1st visit. (a) upper occlusal view, (b) lower occlusal view, (c) panoramic view, (d) Water's view, (e) Chest PA.



**Fig. 3.** Histopathological view (× 200). Note the non-keratinized squamous cell epithelium lining. (a) # 13 area, (b) #45 area.



**Fig. 4.** Initial & Follow-up CT image at 6 months later. Note the size decreased. Initial view (a) #13, (b) #45; 6 months later, (c) #13, (d) #45.



**Fig. 5.** Follow-up panoramic radiograph. Note favorable eruption of #13, 45.

### III . DISCUSSION

The prevalence, treatment, and prognosis of single dentigerous cyst are well known. On the other hand, multiple dentigerous cysts without systemic diseases are rare, particularly ones both in the maxilla and mandible.

According to the previous researches, Ko et al<sup>10)</sup> reported 11 cases of multiple dentigerous cyst which were not related to any syndrome and treated by removal of the cyst. They also treated a 42-year-old Caucasian male patient with bilateral dentigerous cysts on permanent mandibular third molars by removal of the cyst.

After investigating previous studies, Freitas et al<sup>11)</sup> also reported 17 cases including all cases in the paper by Ko et al. Removal of the cyst was done in all cases except one that was not treated. They treated a 14-year-old male patient who had dentigerous cysts on permanent mandibular left second molar and maxillary right third molar by the same procedure.

Lastly, Evren et al.<sup>12)</sup> searched papers issued from 1967 to 2002 under a keyword of “dentigerous cyst, bilateral, and multiple” in MEDLINE, but failed to find anything. They treated a 6-year-old female patient with bilateral dentigerous cysts on maxillary sinuses by removal.

Besides reports mentioned above, several papers about multiple dentigerous cyst which was not related to any syndrome were found. Lonnie et al.<sup>13)</sup> reported that they treated a 7-year-old female patient who had dentigerous cysts on all unerupted permanent teeth except erupted permanent first molar, permanent central, and lateral incisor on both the maxilla and mandible by successive extraction of primary teeth with marsupialization. Also, Yoon and Kang<sup>14)</sup> published 2 treated cases of multiple dentigerous cyst which were not associated with any syndrome.

Cases mentioned above can not represent all multiple cysts which is not related to syndromes. However, these are rare cases for sure, and there are few reports about that these cysts are treated by conservative procedures such as marsupialization.

Decompression, marsupialization, removal, and surgical excision are 4 main treatments for dentigerous cyst. Marsupialization and removal are mostly used<sup>7,15)</sup>. Removal is fast and simple, but it causes a massive bone loss and extraction of the affected teeth. On the other hand, marsupialization can preserve the affected

teeth, but, it requires a long term follow-up, and infection can be occurred by the closure of the cyst or foreign bodies through the entrance of the cyst. To complement these shortcomings, an additional plugger or obturator can be used with a space maintainer<sup>16-19)</sup>. Canine and premolar unlike third molar are worthy to conserve strategically.

#### IV. SUMMARY

This case report is about a 11-year-old boy who had unilateral multiple dentigerous cysts on the maxilla and mandible simultaneously. This patient was treated with a conservative procedure such as marsupialization and eruption guidance using a space maintainer. Monitoring for 1 year is not enough to follow up the patient, thus further clinical and radiographical examinations in a regular basis is needed to assess the prognosis such as the recurrence of the cyst and systemic diseases.

#### REFERENCES

1. Sapp JP, Eversole LR, Wysocki GP : Contemporary oral and maxillofacial pathology, 2nd ed. New York, Elsevier Inc, 45-56, 2005.
2. Kramer IRH, Pindborg JJ, Shear M : Histological typing of odontogenic tumors, 2nd ed. New York, Springer-Verlag, 34-42, 1992.
3. Neville BW, Damm DD, Allen CM, et al. : Oral & Maxillofacial pathology. 2nd ed. Philadelphia, W.B. Saunders co, 590-601, 2002.
4. Mosqueda-Taylor A, Irigoyen-Camacho ME, Diaz-Franco MA, et al. : Odontogenic cyst; Analysis of 856 cases. Med Oral, 7:89-96, 2002.
5. Ochsenius G, Escobar E, Godoy L, et al. : Odontogenic cyst: Analysis of 2,944 cases in Chile. Med Oral Patol Oral Cir Bucal, 12:E85-91, 2007.
6. Meninggaud JP, Oprean N, Pitak-Arnop P : Odontogenic cyst: a clinical study of 695 cases. J Oral Sci, 48:59-62, 2006.
7. McDonald JS. : Tumors of the Oral Soft tissues and cysts and tumors of the bone. In: McDonald RE, Avery DR, eds. Dentistry for the Child and Adolescent. 8th ed. Philadelphia, CV Mosby Co, 148-173, 2004.
8. Cawson RA, Binnie WH, Eveson JW, et al. : Color atlas of oral disease. 2nd ed. Hong Kong, Mosby year book europe Ltd, 5.1-5.16, 2002.
9. Shafer WG, Hine MK, Levy BM, et al. : A textbook of oral pathology. 2nd ed. Philadelphia, W.B Saunders Co, 258-317, 1983.
10. Ko KS, Dover DG, Jordan RC : Bilateral dentigerous cysts - report of an unusual case and review of the literature. J Can Dent Assoc, 65:49-51, 1999.
11. Freitas DQ, Tempest LM, Sicoli E, et al. : Bilateral dentigerous cysts: review of the literature and report of an unusual case. Dentomaxillofac radiol, 35:464-468, 2006.
12. Evren U, Suat F, Cetin A, et al. : Bilateral maxillary dentigerous cysts: A case report. Oral Surg Oral Med Oral Pathol Oral Radiol Endod, 95:632-635, 2003.
13. Lonnie HN, Paolo P, Maria BP : Multiple dentigerous cysts of the maxilla and mandible: Report of a case. J Oral Maxillofac Surg, 45:694-697, 1987.
14. Yoon SJ, Kang BC : Multiple jaw cysts not associated with basal cell nevus syndrome. Korean J Oral Maxillofac Radiol 33:195-198, 2003.
15. Jacobi R : Spontaneous repositioning of displaced molars after marsupialization of a dentigerous cysts. J Am Dent Assoc 102:665-656, 1981.
16. Kang IS, Yang KH : Treatment of dentigerous cyst using marsupialization: a case report. J Kor Acad Pediatr Dent 25:613-618, 1998.
17. Park SJ, Lee KH, Kim DE : Case of dentigerous cysts treated by marsupialization. J Kor Acad Pediatr Dent, 30:459-464, 2003.
18. Eom CY, Choi YC, Lee KH : Two cases of dentigerous cysts treated by marsupialization. J Kor Acad Pediatr Dent, 25:268-276, 1998.
19. Kim JY, Kim HJ, Kim YJ, et al. : Eruption pattern of a cyst-associated mandibular premolar after marsupialization of a dentigerous cyst. J Kor Acad Pediatr, 30:373-384, 2003.

국문 초록

## 양악 편측에 발생한 다발성 합치성 낭종의 치험례

김기백 · 김선미 · 양규호 · 최남기

전남대학교 치의학전문대학원 소아치과학교실, 치의학연구소, 2단계 BK21

합치성 낭종은 일반적으로 미맹출 치아의 치관을 포함하고 있는 형태로, 치아 법랑질과 이장 상피 사이에 액체가 축적되어 생긴 잔존 법랑 상피조직의 퇴행성 변화로 부터 생긴다. 치근단 낭 다음으로 가장 흔한 치성 낭종으로, 주로 단독으로 발생하고 하악 제 3대구치와 상악 소구치에 호발한다.

악골의 다발성 낭종은 주로 기저세포 모반 증후군과 관련된 치성 각화낭이 대부분이고, 점액다당류증 또는 쇠골두개 이형성증과도 관련이 있을 수 있다.

단발성의 합치성 낭종은 우리에게 친숙할 정도로 유병율에서 치료 및 예후까지 잘 알려져 있으나, 전신병력이 없는 다발성의 합치성 낭종은 드물며, 상악과 하악에 발생한 다발성 낭종은 특히 더 드물다. 본 증례는 편측성으로 양악에 함께 발생한 다발성의 합치성 낭종을 가진 11세 소년에 대한 치료 증례로 1년간의 관찰 후 양호할만한 결과를 얻었기에 보고하는 바이다. 1년이라는 관찰 기간이 짧기 때문에 향후 지속적인 임상적, 방사선적 관찰을 필요로 하리라 사료된다.

**주요어 :** 치성 낭종, 합치성 낭종, 기저세포모반증후군