

Case Report

Repeated Intracerebral Hemorrhage from Developmental Venous Anomaly Alone

Min Geun Ku, M.D.,¹ Dong Youl Rhee, M.D., Ph.D.¹ Hwa Seung Park, M.D.,¹ Dae Neung Kim, M.D.²

Department of Neurosurgery,¹ Wallace Memorial Baptist Hospital, Busan, Korea

Department of Neurosurgery,² Veterans Hospital, Busan, Korea

Developmental venous anomalies (DVAs) are hemodynamically low flow, low resistance vascular malformations without clinical significance. Although most DVAs are asymptomatic and are found incidentally, sometimes they can be symptomatic with intracerebral hemorrhage, many of which are usually caused by associated cavernous malformations (CMs) rather than the DVAs themselves. Only a few cases have been reported in the literature where an intracerebral hemorrhage has been caused by a DVA alone. This report describes a case of an intracerebral hemorrhage due to DVA alone with review of the literature.

KEY WORDS : Developmental venous anomaly · Cavernous malformation · Intracerebral hemorrhage.

INTRODUCTION

Developmental venous anomalies (DVAs), also known as venous angiomas or venous malformations, are the most common form of intracranial vascular malformations. They represent anatomically disordered but physiologically essential venous drainage of surrounding normal cerebral tissue within a functionally normal arterial territory. In one third of patients with DVAs, other coexisting cerebral vascular malformations are found, predominantly cavernous malformations (CMs). DVAs are clinically silent lesions, of which the symptomatic hemorrhage rate is very low, with an estimated incidence of 0.22-0.34% per year^{7,17}. Furthermore, most hemorrhages are usually caused by associated CMs rather than DVAs alone. This report describes an intracerebral hemorrhage caused by a DVA without associated CMs.

CASE REPORT

A 16-year-old young man presented with increasing headache intensity. He had been admitted to our hospital

two months previously because of seizure. At that time, computed tomography (CT) and magnetic resonance imaging (MRI) of the brain revealed a homogenous, subacute staged hematoma localized in the right frontal region (Fig. 1A-D). Cerebral angiograms demonstrated the typical appearance of a DVA in the right frontal area (centrally located caput medusae of the lesion) without a cavernous malformation or any other associated vascular malformations (Fig. 2). He was treated conservatively because of the small volume of hematoma and the lack of neurological signs and symptoms. However, the follow-up brain imaging showed the increasing volume of hematoma with mass effect. The heterogenous, multiple-staged hematoma signal intensity at the same site suggested repeated hemorrhage of DVA (Fig. 1E-H). During the surgery for hematoma removal, neither a cavernous malformation nor any other vascular malformations were seen. The histological studies disclosed dilated thin-walled vessels diffusely distributed in normal white matter with an organized old hemorrhage (Fig. 3). His symptoms were relieved after surgery. In postoperative CT, the hematoma was near totally removed (Fig. 4). The postoperative course was satisfactory and he was discharged 17 days after operation without sequelae.

DISCUSSION

Developmental venous anomalies (DVAs) are relatively

• Received : June 3, 2008 • Accepted : December 29, 2008
• Address for reprints : Dong Youl Rhee, M.D., Ph.D.
Department of Neurosurgery, Wallace Memorial Baptist Hospital,
374-75 Namsan-dong, Geumjeong-gu, Busan 609-340, Korea
Tel : +82-51-580-2112, Fax : +82-51-582-6682
E-mail : rdy@wmbh.co.kr

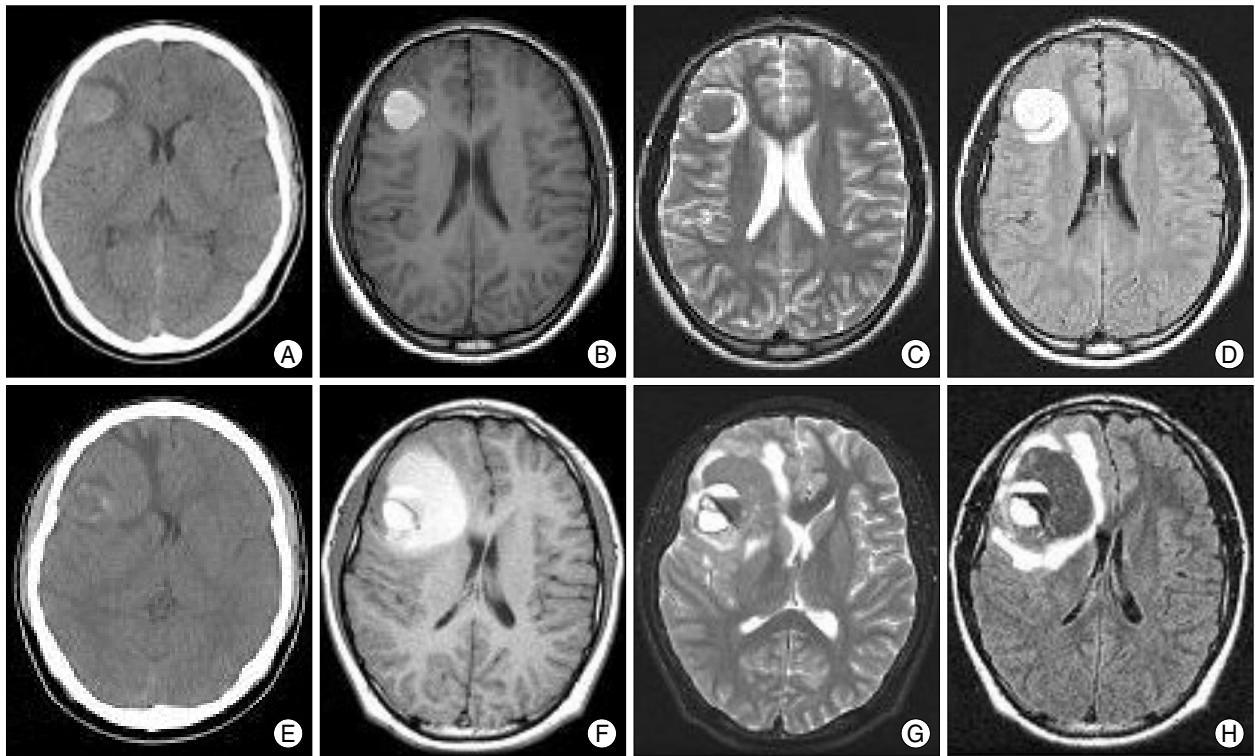


Fig. 1. The upper four figures are computed tomography (CT) (A) and magnetic resonance (MR) images (B, C, and D) at first admission with symptoms such as headache and seizure. There is a subacute staged, homogenous round-shaped hemorrhage on the right frontal area. The lower four figures are CT (E) and MR images (F, G, and H) at second admission with increasing intensity of headadche. There is a multiple staged, heterogenous hemorrhage on the same area.

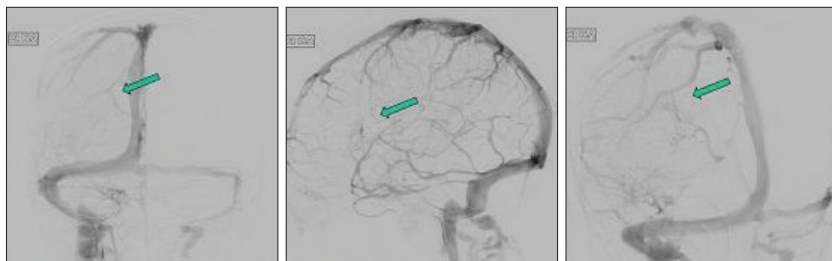


Fig. 2. Cerebral angiograms demonstrate the typical appearance of a developmental venous anomalie on the right frontal area with centrally located caput medusae.

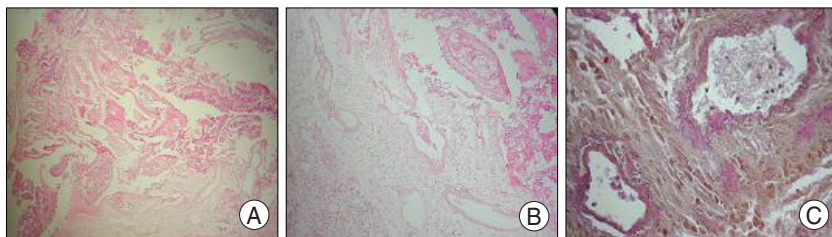


Fig. 3. Pathologic findings reveal the dilated thin-walled vessels diffusely distributed in normal white matter with lack of elastic fiber in vessel walls. A : H & E, $\times 40$. B : H & E, $\times 100$. C : Elastic fiber stain, $\times 400$

benign lesions with little clinical significance and develop in compensation during embryogenesis after occlusion or maldevelopment of the normal medullary veins by some accidents such as an intrauterine ischemic event²⁰). These

anomalous venous channels may be structurally weaker than normal cerebral veins and it is plausible to postulate that DVAs have a high bleeding potential. There are some reports of intracerebral hemorrhage caused by a DVA itself^{4,9,11,14,15,18}). However, many authors assert that DVAs alone are rarely if at all bleed^{3,7,13,16}).

In fact, the bleeding risk associated with DVAs is lower than other vascular malformations (approximately 0.22-0.34% per year^{7,17}) except DVAs in the posterior fossa or during pregnancy^{15,16}). Several authors insist that in the case of bleeding, the hemorrhage in the context of a DVA is likely to be related to an associated CM rather than the DVA itself^{1,10,11,17}). Abdulrauf

et al.¹¹) compared the clinical profile of patients harboring CMs with or without associated DVAs and found that the risk of hemorrhage associated with a DVA was extremely low. They suggested that, in cases of hemorrhage, small associated

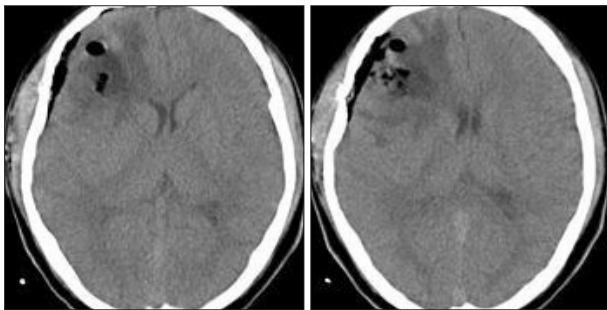


Fig. 4. Postoperative computed tomography scans revealing nearly total removal of the hematoma.

CMs might have been missed. Others have suggested the possibility that the hemorrhage destroyed the underlying CM, which could not be detected by pathologic examination^{7,17}. McLaughlin et al.¹⁷ asserted that the hemorrhage rate of a patient with a DVA was similar to the rates presented in previous reports for patients with CMs without previous symptomatic hemorrhage and it supported that the hemorrhage in patients with DVAs might be related to an underlying but not yet documented CMs. Kovács et al.¹³ insisted that in cases of DVAs with bleeding, associated malformations should be thoroughly looked for. It is interesting that the CMs associated with a DVA have a more aggressive clinical course^{1,5,6,23} and are more likely to present with symptomatic hemorrhage than CMs alone²³.

Abe et al.² insisted that DVAs share a common origin and pathogenic mechanism with CMs. It has been postulated that the abnormal hemodynamics of DVAs might induce the formation of CMs; certain DVAs produced local venous hypertension with resultant microhemorrhage, growth factor release, and creation of CMs^{1,5,19}. Based on these hypotheses, DVAs can be regarded as the primary lesion leading to the occurrence of mixed vascular malformations. We believe these findings support the coexistence of a CM and a DVA which has been relatively commonly reported (2.1-23% of the occurrence rate)^{21,22}. Although mixed vascular malformations of the brain have been thought to be uncommon, it can't be elucidated that most hemorrhages are related with CMs rather than DVAs. Guclu et al.⁸ insisted that DVAs and CMs are two distinct entities with different pathogenetic mechanisms and that DVAs have a distinct biology and clinical behavior when compared to CMs using a gene study in a family whose members were affected by both disorders.

Because the risk of surgery appears to exceed that of the natural history of the disorder, many authors advocate conservative treatment. Kondziolka et al.¹² insisted that surgical removal or radiological obliteration of a DVA should not be considered unless a patient has a second life-threatening hemorrhage. Some authors advocate surgical

resection for the treatment of surgically accessible DVAs, usually after intracerebral hemorrhage or for patients with recurrent hemorrhage^{2,3,16}. Surgical resection of DVAs may frequently bring on a fatal venous infarction³. In order to prevent fatal complications, when surgical extirpation is needed, the DVA itself should be preserved intact, as the sparing of DVAs is not associated with rebleeding^{3,19}. However, Lupret et al.¹⁵ reported that no severe cerebral edema was encountered despite the excision of converging medullary veins and the partial coagulation of the main draining veins.

In our case, magnetic resonance imaging (MRI) and cerebral angiograms revealed a repeated hemorrhage caused by the DVA without associated CMs. During the surgery, the small size of the DVA within the large hematoma had brought on the inevitable damage, but it did not lead to brain swelling or venous infarction. In spite of the thorough histological examination, no CMs or any other vascular anomalies were found.

CONCLUSION

Although DVAs very rarely cause intracerebral hemorrhage, we should keep in mind that DVAs might cause intracerebral hemorrhage without CM when an atypical intracerebral hemorrhage is diagnosed.

References

1. Abdulrauf SI, Kaynar MY, Awad IA : A comparison of the clinical profile of cavernous malformations with and without associated venous malformations. *Neurosurgery* 44 : 41-46; discussion 46-47, 1999
2. Abe M, Asfora WT, DeSalles AA, Kjellberg RN : Cerebellar venous angioma associated with angiographically occult brain stem venous malformation : reports of two cases. *Surg Neurol* 33 : 400-403, 1990
3. Biller J, Toffol GJ, Shea JF, Fine M, Azar-Kia B : Cerebellar venous angiomas. *Arch Neurol* 42 : 367-370, 1985
4. Buhl R, Hempelmann RG, Stark AM, Mehdorn HM : Therapeutic considerations in patients with intracranial venous angiomas. *Eur J Neurol* 9 : 165-169, 2002
5. Ciricillo SF, Dillion WP, Fink ME, Edwards MSB : Progression of multiple cryptic vascular malformations associated with anomalous venous drainage : case report. *J Neurosurg* 81 : 477-481, 1994
6. Comey CH, Kondziolka D, Yonas H : Regional parenchymal enhancement with mixed cavernous/venous malformations of the brain. *J Neurosurg* 86 : 154-158, 1997
7. Garner TB, Del Curling O Jr, Kelly DL Jr, Laster DW : The natural history of intracranial venous angiomas. *J Neurosurg* 75 : 715-722, 1991
8. Guclu B, Ozturk AK, Pricola KL, Seker A, Ozek M, Gunel M : Cerebral venous malformations have distinct genetic origin from cerebral cavernous malformations. *Stroke* 36 : 2479-2480, 2005
9. Gümüş A, Yildirim SV, Kizilkılıç O, Cengiz N, Cemil T : Case report : seizures in a child caused by a large venous angioma. *J Child Neurol* 22 : 787-789, 2007
10. Jung JH, Kim MH, Park HK, Park HC, Kim SH, Shin KM, et al : Cerebral cavernous hemangiomas associated with venous angiomas. *J Korean Neurosurg Soc* 25 : 662-667, 1996

11. Koc K, Anik I, Akansel Q, Anik Y, Ceylan S : Massive intracerebral hemorrhage due to developmental venous anomaly. *Br J Neurosurg* 21 : 403-405, 2007
12. Kondziolka D, Dempsey PK, Lunsford LD : The case for conservative management of venous angiomas. *Can J Neurol Sci* 18 : 295-299, 1991
13. Kovács T, Osztie E, Bodrogi L, Pajor P, Farsang M, Juhász C, et al : Cerebellar developmental venous anomalies with associated vascular pathology. *Br J Neurosurg* 21 : 217-223, 2007
14. Lovrencic-Huzjan A, Rumboldt Z, Marotti M, Demarin V : Subarachnoid haemorrhage headache from a developmental venous anomaly. *Cephalgia* 24 : 763-766, 2004
15. Lupret V, Negovetic L, Smiljanic D, Klanfar Z, Lambasa S : Cerebral venous angiomas : surgery as a mode of treatment for selected cases. *Acta Neurochir (Wien)* 120 : 33-39, 1993
16. Malik GM, Morgan JK, Boulos RS, Ausman JI : Venous angiomas : an underestimated cause of intracranial hemorrhage. *Surg Neurol* 30 : 350-358, 1988
17. McLaughlin MR, Kondziolka D, Flickinger JC, Lunsford S, Lunsford LD : The prospective natural history of cerebral venous malformations. *Neurosurgery* 43 : 195-200 ; discussion 200-201, 1998
18. Merten CL, Knitelius HO, Hedde JP, Assheuer J, Bewermeyer H : Intracerebral haemorrhage from a venous angioma following thrombosis of a draining vein. *Neuroradiology* 40 : 15-18, 1998
19. Rigamonti D, Spetzler RF, Medina M, Rigamonti K, Geckle DS, Pappas C : Cerebral venous malformations. *J Neurosurg* 73 : 560-564, 1990
20. Saito Y, Kobayashi N : Cerebral venous angiomas : clinical evaluation and possible etiology. *Radiology* 139 : 87-94, 1981
21. Töpper R, Jörgens E, Reul J, Thron A : Clinical significance of intracranial developmental venous anomalies. *J Neurol Neurosurg Psychiatry* 67 : 234-238, 1999
22. Wilms G, Bleus E, Demaerel P, Marchal G, Plets C, Goffin J, et al : Simultaneous occurrence of developmental anomalies and cavernous angiomas. *AJNR Am J Neuroradiol* 15 : 1247-1254; discussion 1255-1257, 1994
23. Wurm G, Schnizer M, Fellner FA : Cerebral cavernous malformations associated with venous anomalies : surgical considerations. *Neurosurgery* 57 (1 Suppl) : 42-58; discussion 42-58, 2005