

## Case Report

# Therapeutic Difficulty in a Case of Supratentorial Primitive Neuroectodermal Tumor Diagnosed during Pregnancy

Feyzi Birol Sarica, M.D., Kadir Tufan, M.D., Orhan Sen, M.D., Bulent Erdogan, M.D.

Department of Neurosurgery, Baskent University Faculty of Medicine, Ankara, Turkey

We report a supratentorial primitive neuroectodermal tumor (sPNET) in 17-year-old primipara in the second trimester her pregnancy. Magnetic resonance imaging revealed a left frontoparietal mass with solid and cystic component. Gross-total resection was achieved via a left frontoparietal craniotomy. It was decided to suspend the radiotherapy and chemotherapy until the 30 weeks of gestation. But, a sudden uncal herniation was developed due to the recurrence of the tumor and bleeding into the tumor at the 25 weeks of gestation and the patient died after urgent decompressive surgery. sPNETs is an extremely rare brain tumor in pregnancy and only two cases were reported in the literature to date. There is no universally agreed treatment protocol for sPNETs during pregnancy and a multidisciplinary approach is required in treatment. In the present study, the clinical, histopathological features and therapeutical difficulties of sPNETs diagnosed during pregnancy was discussed with the literature review.

**KEY WORDS :** Multidisciplinary treatment · Pregnancy · Supratentorial primitive neuroectodermal tumor.

## INTRODUCTION

Primitive neuroectodermal tumors (PNETs) are poorly differentiated neoplasms with quite aggressive progression, originating in the germinal matrix cells of the primitive neural tube in the central nervous system. PNETs comprise 1% of all childhood primary central nervous system (CNS) tumors and 5% of tumors with supratentorial location. These usually occur in children before the age of one and follow a rather aggressive course<sup>3,5</sup>. Due to rapid growth potential, they present with symptoms related to increased intracranial pressure (ICP). According to the World Health Organization (WHO) classification of 1993, PNETs localized in the cerebellum were classified as PNET/Medulloblastoma, while those with non-cerebellar localization were classified as supratentorial primitive neuroectodermal tumors (sPNETs). In the 2000 WHO histological classification

of tumors of CNS, the terms Neuroblastoma and Ganglioneuroblastoma appear under the sPNETs heading.

In addition to being rarely seen in adults, sPNETs are extremely rare during pregnancy. Only 2 such cases have been previously reported<sup>1,11</sup>. Treatment of sPNETs in pregnancy is complicated by the presence of the fetus. In the present study, the clinical, histopathological features and therapeutical difficulties of sPNETs during pregnancy are discussed with the literature review.

## CASE REPORT

A 17-year-old woman, gravida 1 para 0, in her 20th week of pregnancy, was admitted to hospital with headache and weakness in the right arm and leg. Confusion, dysphasia and right hemiparesis (grade 1/5) were detected in neurological examination. Magnetic resonance imaging revealed, a left frontoparietal cystic mass (size : 5.5 × 4.5 × 2.5 cm) with peripheral enhancement (Fig. 1). Gross-total resection was achieved via a left frontoparietal craniotomy (Fig. 2). Atypical cells, with a round hyperchromatic nucleus and narrow cytoplasm, few rosette-like structures occasionally displaying a diffuse pattern were seen on

• Received : June 3, 2008 • Accepted : December 29, 2008  
• Address for reprints : Kadir Tufan, M.D.  
Department of Neurosurgery, Baskent University Baskent Universitesi  
Adana Uygulama ve Arastirma Hastanesi, Dadaloglu Mahallesi. 39.  
Sokak No: 6, 01250, Adana - TURKEY  
Tel : +90-322-3272727, Fax : +90-322-3271273  
E-mail : kadirufan@hotmail.com

Hematoxylin & Eosin-stained sections (Fig. 3A). It was considered as a small cell malignant tumor. Postoperative course was uneventful and moderate improvement in her right hemiparesis (grade 4/5) and dysphasia were noted. Consultation with the Medical Oncology, Radiation Oncology and Gynecology Departments resulted in decision to give an adjuvant radiation therapy to the neurocranium and chemotherapy at 30 weeks of gestation and to deliver the baby at 34 weeks.

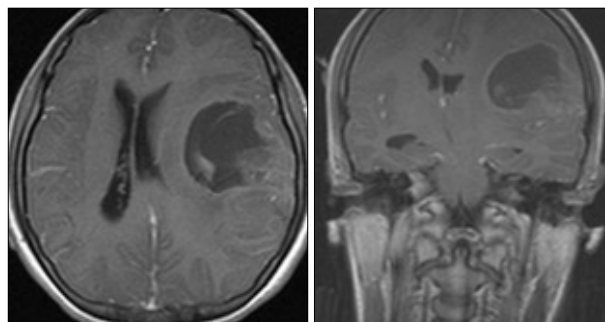
Light microscopic examination depicted malignant neoplastic development with the features explained above. Frequent mitosis was noticed (Fig. 3A). Glial Fibrillary Acidic Protein (GFAP), CD-99, Neuron Specific Enolase (NSE), Chromogranin, Synaptophysin focal positive (Fig. 3B), Leukocyte Common Antibody (LCA) and Desmin negative cells were observed by immunohistochemical staining techniques. It was reported as a primitive neuroectodermal tumor when evaluated together with the present morphological and immunohistochemical findings.

At 25 weeks of pregnancy, patient was re-hospitalized by the Gynecology Department due to threatened abortion and headache. On day 3 of hospitalization, patient developed a sudden nausea and vomiting and lost her consciousness gradually. On the neurological examination, dilated right pupil, decorticated rigidity by painful stimuli and Cheyne-Stokes respiration were detected. Glasgow coma scale score was 5/15. After safeguarding the abdomen, cranial CT showed recurrence of the both cystic and solid component of the tumor measuring 5.5 × 4.5 cm and acute hemorrhage in the tumor with brain shift toward to right side. (Fig. 4). After mannitol and steroid infusion, the patient was urgently taken to the operation room together with the obstetricians. The cystic mass was aspirated and the craniotomy flap was removed for decompression (Fig. 5). Simultaneously, obstetricians delivered, by caesarian section, a 1,770 g girl with an Apgar score of 7/9. However, no improvement was observed on the patient's postoperative neurological status possibly due to uncal herniation, and she died on postoperative day 4.

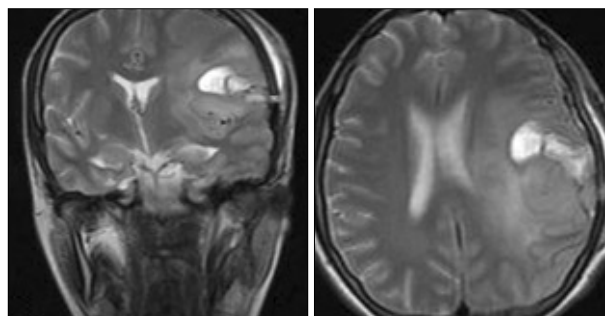
**DISCUSSION**

The relationship between brain tumor and pregnancy are not well known and no detailed studies that explain pathophysiological behavior of brain tumors during pregnancy are available. Numerous aggravating factors were associated with brain

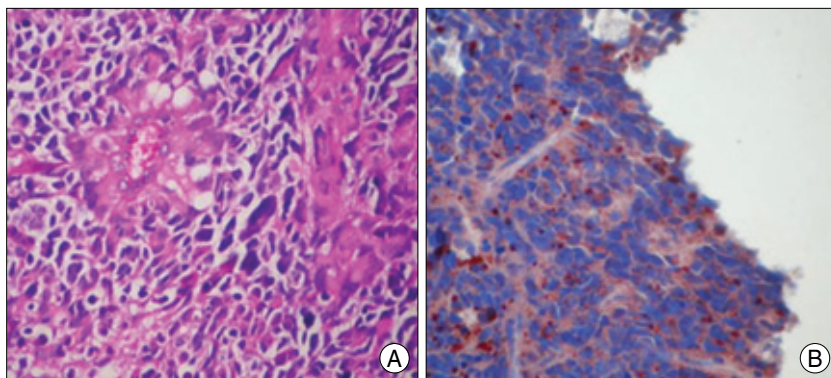
tumors during pregnancy. Some of these factors include expansion of the tumor vascular bed in conjunction with the maternal blood changes, vascular engorgement, angioformative characteristic of the stromal cell and endocrine changes. Potential reasons for a decreased incidence of brain tumors during pregnancy may include the antiangiogenic hormonal milieu induced by progesterone or other growth factors that regulate the maternal response to the growing fetus<sup>2,7,9)</sup>. However, when reviewing the literature, no reliable causative factor was found for the development and / or aggravation of



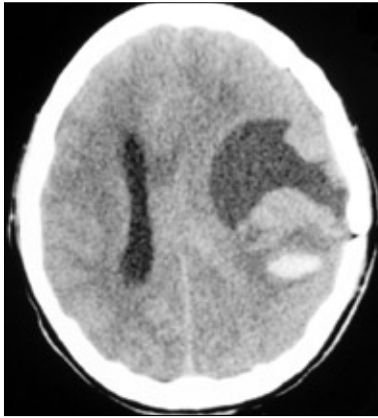
**Fig. 1.** A cystic mass (size: 5.5 × 4.5 × 2.5 cm) lying from inferior gyrus of the left frontal lobe to the temporal lobe causing 1.5 cm subfalcine herniation, revealing slight contrast and accompanied by a solid component on the posteolateral is observed on the preoperative T1 weighted magnetic resonance images of the brain.



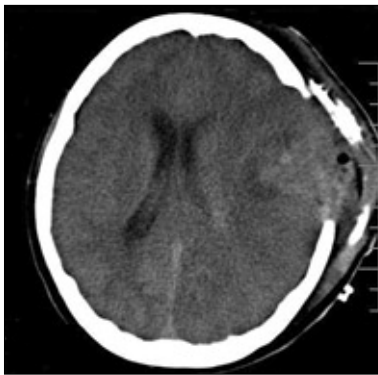
**Fig. 2.** Postoperative cerebral magnetic resonance image shows the removal of the tumor via left frontoparietotemporal craniotomy, postoperative changes and decrease of subfalcine herniation towards the right.



**Fig. 3.** A : The arrangement of the tumor cells with pleomorphic and hyperchromatic nucleus in perivascular rosette formation (HE × 400). B : The positivity of Synaptophysin in the cytoplasm of tumor cells (× 400).



**Fig. 4.** Cranial computed tomography before the second operation reveals the recurrence of both cystic and solid component of the tumor and acute hemorrhage in the tumor.



**Fig. 5.** Control computed tomography after the second operation shows the craniectomy site. Images verified the adequate decompression of the cystic and hemorrhagic mass.

a brain tumor during pregnancy.

The clinical behavior of malignant brain tumors involves general non-specific and non-characteristic findings in pregnancy. For instance, nausea and vomiting, common in early pregnancy, are also present in about 25% of pregnant women with an intracranial neoplasm. Persistent nausea and emesis have been mistakenly attributed to hyperemesis gravidarum in cases of a brain tumor<sup>7,9</sup>. Headache may occur in pregnancy, but the new onset of a persistent headache, particularly associated with nausea, vomiting, or focal neurological signs,

mandates neuroimaging. The symptoms are similar to other malignant supratentorial tumors and occur as a result of direct effect the tumor and increased intracranial pressure. Focal neurological findings develop due to mass effect. The initial duration of the symptoms, which was reported to reach a peak between 1 and 3 months though it displays a variation between 1 and 12 months, was only 10 days in our patient<sup>5,8,9</sup>.

First case of sPNETs during pregnancy was reported by Bodner-Adler and colleagues in 2006 in Austria. The tumor was detected in a 26-year-old patient who was 20 weeks pregnant. Patient underwent gross-total resection of the tumor, followed by neoadjuvant radiation therapy to the neurocranium and chemotherapy with Temozolomide at 30 weeks of gestation. The baby was delivered at 34 weeks of gestation by Caesarian section and then the patient received a complete radiation therapy to the craniospinal axis. Patient was admitted to the hospital for follow-up 3 months after diagnosis. No evidence of disease was detected<sup>11</sup>. However,

the tolerability of the doses of chemotherapy and RT was not discussed during the postoperative observation of the baby. The second case was reported in Italy in 2007 by Ulivieri et al. Tumor was diagnosed at 20 weeks of gestation in an 18-year old patient who underwent total resection. When tumor recurrence was detected 3 months later, baby was delivered by Caesarian section, patient was re-operated and the tumor was excised, followed by combined chemotherapy and radiotherapy<sup>11</sup>. It is not possible to comment on mean survival since both cases were detected very recently. Histopathological and radiological features and clinical course of sPNETs diagnosed during pregnancy are similar to sPNETs in normal adults. In this report, we, by taking pregnancy into account, considered the effects of therapeutic options on the fetus and used the data gathered from adult sPNET cases as well in outlining the treatment plan following the delivery of the baby.

Treatment of sPNETs in pregnancy is complicated by the presence of the fetus. These lesions require diagnostic intervention and treatment regardless of the gestational age of the fetus. The patient and her family should be clearly but compassionately informed of the poor prognosis of these lesions to allow her to guide the medical team about her priorities for treatment. The first choice in the treatment is radical surgical resection. The basic approach in surgery should be, as in other intrinsic neoplasms, the radical removal of the tumor using internal decompression in a manner to give the least damage to the surrounding healthy parenchyma and vascular structures<sup>1,3,5,6</sup>. Kim et al. reported the type of resection being the major prognostic factor<sup>5</sup>.

Gestational month is another very important parameter in pregnant patients with radiosensitive malignant brain tumors. Radiotherapy during pregnancy might cause harm to the developing fetus. Generally, pregnant women with malignant diseases are advised to delay radiotherapy until after delivery. However, this advice is not based on knowledge of the risks of radiation to the unborn child. In general, the expected radiation effects, such as mental retardation and organ malformations probably arise above a threshold dose of 0.1-0.2 Gy. This dose threshold is generally not enough for curative radiotherapy during pregnancy<sup>4</sup>.

Publications regarding the administration of chemotherapy postoperatively are few in number and the results are contradictory for sPNETs<sup>3,8,10</sup>. Information related to pregnancy and cytotoxic treatments are generally derived from animal studies. Those obtained from human studies are limited to case reports or small series. The most critical period with regard to genetic and teratogenic effects of chemotherapeutic agents on fetus is the active organogenesis stage that takes place between 3-10 weeks of gestation. The frequency

of teratogenicity during this period was reported between 10-20%. Therefore, chemotherapeutic agents should be avoided as much as possible in the first trimester. It is accepted that chemotherapy does not further increase the risk of fetal malformations even in the 2nd trimester. Dysfunction of the endocrine system and motor-mental retardation are amongst the late effects that are related to chemotherapeutics and we do not have sufficient knowledge on them<sup>7,9)</sup>.

sPNETs in adults and children are similar with regard to the clinical features and prognosis. Type of resection is the major prognostic factor. Presence of systematic metastasis such as leptomeningeal metastasis and involvement of the lungs and the lymph nodes are poor prognostic factors. Prognosis of sPNETs is generally poor. Mean survival is 24 months in adults although 5-year survival was also reported in a few patients<sup>3,5,6,8)</sup>.

## CONCLUSION

sPNETs are rarely seen during pregnancy and only two cases were reported in the literature to date. The primary choice in treatment is radical surgical resection. Adjuvant treatment should be planned due to local recurrence and tendency to metastasize within the neuraxis. There is controversy with regard to chemotherapy. The most important factor in planning the treatment during gestation is the time of gestation but there is no general agreement on the timing of RT and chemotherapy. Since the outcome of sPNETs are poor and these tumors grow rapidly, we conclude to treat the pregnant patients without taking account the fetus. There is no universally established treat-

ment protocol for cases seen during pregnancy and a multidisciplinary treatment approach is required.

## References

1. Bodner-Adler B, Bodner K, Zeisler H : Primitive neuroectodermal tumor (PNET) of the brain diagnosed during pregnancy. *Anti-cancer Res* 26 : 2499-2501, 2006
2. Erdogan B, Sen O, Aydin MV, Bagis T, Bavbek M : Cerebellar hemangioblastoma in pregnancy. A case report. *J Reprod Med* 47 : 864-866, 2002
3. Hwang MJ, Kim DW, Lee SY, Kim IM, Lee CY, Yim BM, et al : Treatment of supratentorial primitive neuroectodermal tumors (PNETs) in children. *J Korean Neurosurg Soc* 37 : 193-196, 2005
4. Kal HB, Struikmans H : Radiotherapy during pregnancy : fact and fiction. *Lancet Oncol* 6 : 328-333, 2005
5. Kim DG, Lee DY, Paek SH, Chi JG, Choe G, Jung HW : Supratentorial primitive neuroectodermal tumors in adults. *J Neurooncol* 60 : 43-52, 2002
6. Kouyialis AT, Boviatsis EI, Karampelas IK, Korfiatis S, Korkolopoulou P, Sakas DE : Primitive supratentorial neuroectodermal tumor in an adult. *J Clin Neurosci* 12 : 492-495, 2005
7. Oduncu FS, Kimming R, Hepp H, Emmerich B : Cancer in pregnancy : maternal-fetal conflict. *J Cancer Res Clin Oncol* 129 : 133-146, 2003
8. Ohba S, Yoshida K, Hirose Y, Ikeda E, Kawase T : A supratentorial primitive neuroectodermal tumor in an adult : a case report and review of the literature. *J Neurooncol* 86 : 217-224, 2008
9. Swensen R, Kirsch W : Brain neoplasms in women : a review. *Clin Obstet Gynecol* 45 : 904-927, 2002
10. Terheggen F, Troost D, Majoie CB, Leenstra S, Richel DJ : Local recurrence and distant metastasis of supratentorial primitive neuroectodermal tumor in an adult patient successfully treated with intensive induction chemotherapy and maintenance temozolomide. *J Neurooncol* 82 : 113-116, 2007
11. Ulivieri S, Oliveri G, Filosomi F, Petraglia F : Supratentorial primitive neuroectodermal tumor during pregnancy. Case report. *Minerva Ginecol* 59 : 199-201, 2007