

## Case Report

# An Anatomical Variant : Low-Lying Bifurcation of the Common Carotid Artery, and Its Surgical Implications in Anterior Cervical Discectomy

Salih Gulsen, M.D., Hakan Caner, M.D., Nur Altinors, M.D.

Department of Neurosurgery, Baskent University College of Medicine, Ankara, Turkey

The common carotid artery generally bifurcates into the internal and external carotid arteries at the level of C3-4. Injury to the common carotid artery during anterior cervical discectomy is a complication that is very much feared but encountered rarely. Knowing the anatomic variations of the common carotid artery and using an operating microscope during the anterior cervical approach for cases with low-lying bifurcation of the common carotid artery would prevent injuries to this artery. We present a 42-year-old female who has successfully undergone anterior cervical discectomy at the level of C5-6 and C6-7. She had a low-lying bifurcation of the common carotid artery.

**KEY WORDS :** Anterior cervical discectomy · Common carotid artery · Low bifurcation.

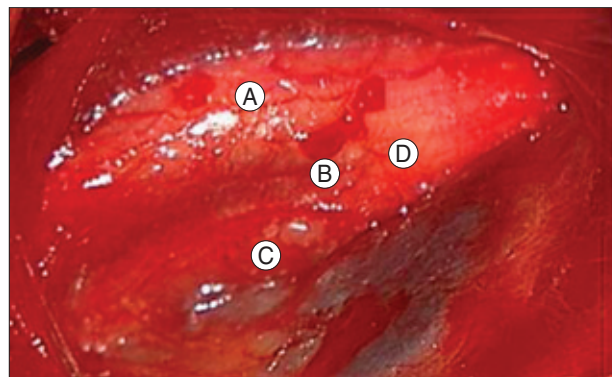
## INTRODUCTION

Anterior cervical discectomy is the surgical treatment method of choice for patients who fail to improve with conservative methods and also those with progressive neurological deficit while undergoing non-surgical management. It is possible to expose between the C3 and C7 levels anteriorly. An anterior approach to cervical disc pathology is widely accepted by neurosurgeons; however, this approach has some difficulties due to the complex anatomy of the neck region. Various complications due to inadvertent injury to the structures located in the anterior part of the neck including the esophagus, recurrent laryngeal nerve, vertebral artery and carotid artery have been reported<sup>2,4,5,7</sup>. Knowing the anatomical relationship between these structures, and also their variations is extremely important in preventing these complications. We present our case to emphasize the importance of being aware of the bifurcation point of the common carotid artery. In this case, the bifurcation of the common carotid artery was located between the body of the

C6 and C7 on the right side, and between the body of the C5 and C6 on the left side.

## CASE REPORT

A 42-year-old woman presented with symptoms of right arm pain and difficulty carrying objects with her right hand. Her motor power at the right biceps and deltoid was 4/5 and the right biceps reflex was unresponsive. Cervical



**Fig. 1.** Intraoperative image showing bifurcation of the common carotid artery during dissection of the neck for cervical disc operation at the level between C6-7 on the right side. A : right internal carotid artery, B : bifurcation of the common carotid artery, C : external common carotid artery, D : common carotid artery.

• Received : July 2, 2008 • Accepted : December 29, 2008

• Address for reprints : Salih Gulsen, M.D.

Department of Neurosurgery, Baskent University College of Medicine,  
10. sokak no 45, 06490 Bahçelievler, Ankara, Turkey

Tel : 0090 312 212 68 68/1362, Fax : 0090 312 223 73 33

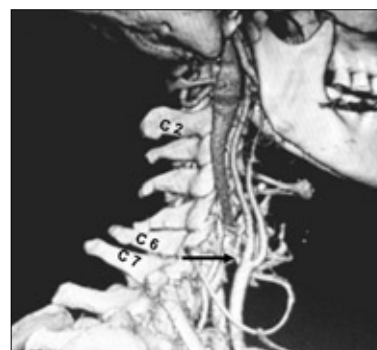E-mail : salihgulsen07@gmail.com

MRI revealed degenerative changes in the disc space between C5 and C6, and C6 and C7. In addition, the C6 root was compressed due to disc herniation on the right side at the level of C6-C7. After routine dissection of the neck, the platysma muscle was cut with tissue scissors and the carotid artery seen directly at the medial border of the sternocleidomastoid muscle without any dissection. The location of the carotid artery was more medial, more superficial and wider than in our usual anterior discectomy cases. We continued the dissection with the operating microscope, and noticed that the bifurcation of the common carotid artery was located just above the C6-7 interspace (Fig. 1). We then continued more cautiously, and also had some difficulty because of the lower bifurcation of the common carotid artery during traction of the tissues to expose the disc spaces and insertion of the cages into the cervical interspaces. Anterior cervical discectomy and fusion were performed through the right side of the neck and cages were placed between the level of C5-6 and C6-7. The operation was completed without any complications and the patient was discharged uneventfully.

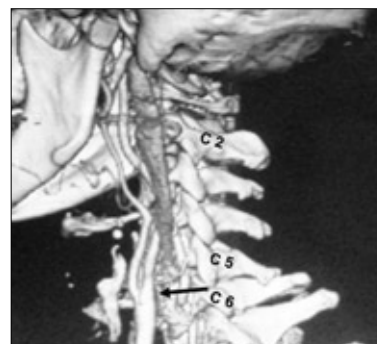
## DISCUSSION

The common carotid artery bifurcation is most commonly located between the C3-4 and C4-5 levels, but it may be at any cervical level<sup>7</sup>. Hayashi et al.<sup>1</sup> reported that the position of the bifurcation of the common carotid artery was located around the inferior part of the body of the C3 in Japanese individuals. Lo et al. described the carotid artery bifurcation point using its relation with the thyroid cartilage and hyoid bone. They found that the common carotid artery bifurcation point was at the level of the body of the hyoid bone in 40% of the cases, and the level of the bifurcation was asymmetrical between the left and right sides<sup>4</sup>. Inamasu and associates showed individual variation regarding bifurcation of the common carotid artery in their study<sup>2</sup>. Ito and associates reported a high common carotid artery bifurcation in 25 (31.2%), standard bifurcation in 46 (57.5%), and low bifurcation in 9 (11.3%) in a total of 80 cases<sup>3</sup>. Osborn showed that the normal common carotid artery bifurcation is at or near the level of the thyroid cartilage (approximately C4), but bifurcation may occur as high as C1 or as low as T2<sup>6</sup>. In our clinical experience, high bifurcation of the common carotid artery did not cause any problems regarding anterior cervical discectomy, but low bifurcation may cause some problems if one is not cautious. In the present case, we had dissected the neck on the right side and reached and cut the platysma muscle when we unexpectedly encountered a superficially-located and wider than normal common carotid artery that

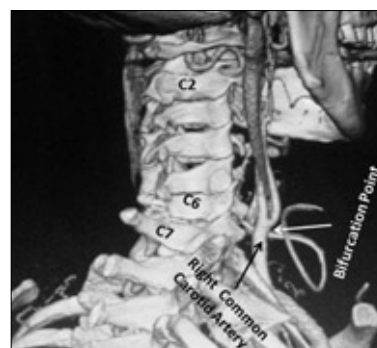
was also closer to the midline. After detection of this variant location of the common carotid artery, we decided to use the operating microscope to complete neck dissection. We provided enough exposure to reach the level of C5-6 and C6-7 interspaces. We encountered two main difficulties in providing enough exposure during neck dissection: First, we had to retract the common carotid artery more than usual due to its wider transverse diameter at the bifurcation point and its more median and more superficial location. We also had some difficulty during placement of the cages to the intervertebral spaces for the same reasons. Carotid artery injury is one of the most feared, but fortunately least encountered complications during anterior cervical discectomy<sup>4</sup>. Two days after the operation, we performed computerized tomographic angiography, which showed the low bifurcation point at



**Fig. 2.** Post-operative cervical computed tomography (Right lateral view) (Three dimensional reconstruction) with intravenous contrast revealing inferior location of the common carotid artery bifurcation. This bifurcation was at the level between C6-7 on the right side. Arrow showing the bifurcation point.



**Fig. 3.** Post-operative cervical computed tomography (left lateral view) (Three dimensional reconstruction) also showing inferior location of the common carotid artery bifurcation but this bifurcation was at the level between C 5- 6 on the left side. Arrow showing the bifurcation point.



**Fig. 4.** Post-operative cervical computed tomography (Right posterolateral view) (Three dimensional reconstruction) also showing inferior location of the common carotid artery bifurcation, but this bifurcation was at the level between C6-7 on the right side. White arrow showing the bifurcation point and black arrow showing common carotid artery.

the level of C5-6 on the right side and C6-7 on the left side (Fig. 2, 3, 4). It is not practical due to financial considerations to routinely use computerized angiography of the common carotid artery for all cervical disc patients undergoing cervical discectomy but awareness of such anatomical variations perioperatively, and using the operating microscope during neck dissection will minimize unexpected injury to the common carotid artery in patients with low-lying bifurcation of the common carotid artery.

## CONCLUSION

Carotid artery injury is a rare but potentially devastating event that can occur during anterior cervical approaches. When a neurosurgeon encounters a low-lying bifurcation of the common carotid artery during anterior neck dissection, use of the operating microscope might be helpful in preventing common carotid artery injury. A lower location of the common carotid artery bifurcation may obviate some manipulations during anterior cervical

approach such as placement of the artificial disc or cage to the intervertebral space on account of its wider transverse diameter.

## References

1. Hayashi N, Hori E, Ohtani Y, Ohtani O, Kuwayama N, Endo S : Surgical anatomy of the cervical carotid artery for carotid endarterectomy. *Neurol Med Chir (Tokyo)* 45 : 25-29; discussion 30, 2005
2. Inamasu J, Guiot BH : Iatrogenic carotid artery injury in neurosurgery. *Neurosurg Rev* 28 : 239-247; discussion 248, 2005
3. Ito H, Mataga I, Kageyama I, Kobayashi K : Clinical anatomy in the neck region--the position of external and internal carotid arteries may be reversed. *Okajimas Folia Anat Jpn* 82 : 157-167, 2006
4. Lo A, Oehley M, Bartlett A, Adams D, Blyth P, Al-Ali S : Anatomical variations of the common carotid artery bifurcation. *ANZ J Surg* 76 : 970-972, 2006
5. Mayfield FH : Cervical Spondylosis : a comparison of the anterior and posterior approaches. *Clin Neurosurg* 13 : 181-188, 1965
6. Osborn Anne G : *Diagnostic Cerebral Angiography*, ed 2. Philadelphia : Lippincott Williams & Wilkins 1999, pp 62-63
7. Gray H : The Carotid system of arteries in Williams PL, Warwick R (eds) : *Gray's Anatomy*, ed 36. Edinburgh : Churchill Livingstone, 1980, pp 676-692