

# A case of persistent pulmonary hypertension of the newborn: Treatment with inhaled iloprost

Yoon Young Jang, M.D., and Hye Jin Park, M.D.

Department of Pediatrics, School of Medicine, Catholic University of Daegu, Daegu, Korea

## = Abstract =

We report a case of a full-term neonate with persistent pulmonary hypertension who developed asphyxia after birth and was treated with iloprost. The neonate had persistent hypoxia and did not respond to supportive treatment. Because inhaled nitric oxide (iNO) was not available in our hospital, inhaled iloprost was administered via an endotracheal tube. This resulted in an immediate elevation of oxygen saturation. Echocardiography revealed the conversion of the right-to-left ductal shunt to the left-to-right one and a decrease of the right ventricular pressure. The use of inhaled iloprost did not cause any significant side effects. Here, we describe our experience where iloprost was used in a neonate with persistent pulmonary hypertension because the standard therapy with inhaled nitric oxide was not available. (**Korean J Pediatr 2009;52:1175-1180**)

**Key Words :** Persistent fetal circulation syndrome, Iloprost

## Introduction

Persistent pulmonary hypertension of the newborn (PPHN) is a serious disorder with high mortality. The introduction of inhaled nitric oxide (iNO) has greatly improved survival and reduced morbidity. However, in many hospitals this form of treatment is not readily available. Inhaled iloprost has been shown to be a safe and effective pulmonary vasodilator therapy in patients with primary pulmonary hypertension. Although few data are available about iloprost use in PPHN, it could be a rescue therapy in case of iNO unavailability or refractory to iNO therapy. Here we describe our experience of using inhaled iloprost in a neonate with PPHN.

## Case report

A 2,200 g female infant was born to a 32 year old G2P0A1 mother at 37+1 weeks gestation. Since 34 weeks

of gestational age, the mother had higher blood pressure than normal but not preeclampsia. One day prior to delivery, the mother felt decreased fetal movements and an emergency Cesarean section was done because of fetal distress.

There was thick meconium staining of the amniotic fluid, central cyanosis, and no spontaneous respiratory movements. The heart rate was approximately 20-30 per minute with normal heart sounds and no murmurs. The infant was hypotonic and showed no spontaneous movements. The infant was intubated and bag and mask ventilation with cardiac massage was done. After 5 minutes, heart rate rose up to 100 per minute and respiration was done by self. The Apgar scores were 2, 5 and 7 at 1, 5 and 10 minutes respectively.

There were no dysmorphic features. Both lungs were evenly aerated without crackles on auscultation. The abdomen was soft and flat without apparent organomegaly on palpation. There were two umbilical arteries and one vein. The birth weight was 2,200 g (10-25th percentile), length 47 cm (25-50th percentile), and head circumference 32 cm (25-50th percentile).

Initial laboratory findings revealed: hemoglobin 15.6 g/dL, white blood cell (WBC) 7,300/ $\mu$ L, platelets 145,000/ $\mu$ L, normal electrolytes except aspartate aminotransferase (AST) 232 unit, alanine aminotransferase (ALT) 68 unit, arterial

Received : 25 May 2009, Revised : 6 August 2009

Accepted : 11 September 2009

Address for correspondence : Hye Jin Park, M.D.

Department of Pediatrics, School of Medicine, Catholic University of Daegu, 3056-6, Daemyung4-dong, Namgu, Daegu, 700-712, Korea

Tel : +82.53-650-4231, Fax : +82.53-622-4240

E-mail : grapfarm@hanmail.net

blood gases: pH 7.106, pCO<sub>2</sub> 49 mmHg, pO<sub>2</sub> 43 mmHg, HCO<sub>3</sub> 15.2 mmol/L, and base excess (BE) -14 mmol/L, serum glucose 25 mg/dL. The hypoglycemia was treated with intravenous dextrose.

Initial heart rate was 144/minute and respiratory rate was 58/minute. Blood pressure was 48/25 mmHg initially and arterial hypotension was treated with intravenous volumes and dopamin was continuously infused by 10 µg/min/kg. Oxygen saturation was 93% of right arm and 88% of right leg.

Mechanical ventilation started and sufficient oxygenation was achieved on conventional ventilation, with continuous positive airway pressure (CPAP) mode (PEEP 6, FiO<sub>2</sub> 50%).

Chest X-ray showed significant diffuse infiltrations in both lung fields. There was a cardiomegaly with 68% of cardiothoracic (C-T) ratio. Empirical antibiotic treatment was initiated. A transthoracic echocardiography demonstrated no structural abnormalities of the heart and a left-to-right shunt through both the patent ductus arteriosus (PDA) and patent foramen ovale (PFO) and increased pulmonary artery pressure with 49 mmHg of systolic tricuspid regurgitation (TR) pressure gradient.

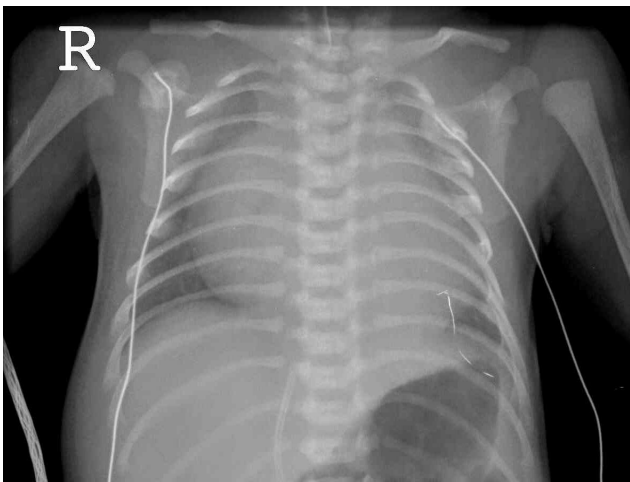
After an initial mild recovery with normal blood gases, the baby deteriorated with a decrease in oxygen saturation to 80–90% and intermittent cyanosis with 50–60% oxygen saturation. We changed the ventilator mode into Synchronized intermittent mandatory ventilation (SIMV) (PIP 17 cmH<sub>2</sub>O, PEEP 6 cmH<sub>2</sub>O, frequency 50/min, FiO<sub>2</sub> 100%), but the intermittent decrease in oxygen saturation con-

tinued. The postductal saturation was 10–15% points lower than the preductal measurement, raising the suspicion of PPHN with right-to-left shunting at the ductus arteriosus. Chest X-ray showed significant increase in cardiomegaly with 77% of C-T ratio (Fig. 1). We continued the conservative treatments including oxygen, assisted ventilation with sedation, intravenous fluids, correction of acidosis. But the clinical condition was worsened during the three days after admission. Four days after admission, repeated echocardiography demonstrated a right-to-left shunt through a large PDA, bidirectional shunt through PFO and supra-systemic pulmonary artery pressure with 63 mmHg of systolic TR pressure gradient, consistent with the diagnosis of persistent pulmonary hypertension of the newborn (Fig. 2).

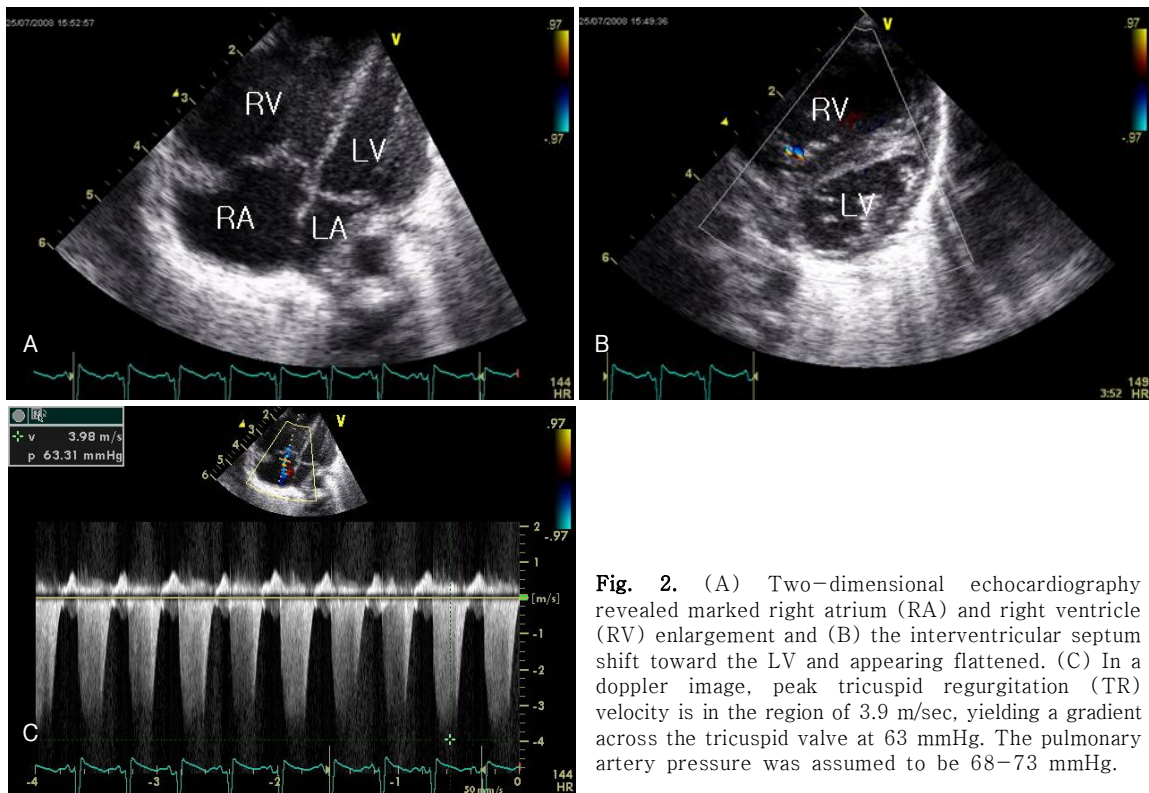
We continued the ventilator therapy with a maximal mean airway pressure of 12 cmH<sub>2</sub>O and 100% oxygen. The treatment included continuous administration of inotropic agents with dopamin and correction of acidosis with intravenous bicarbonate. The mean arterial blood pressure was maintained around 50 mmHg by dopamine 10 µg/min/kg. However, the oxygen saturation was around 70–80%, and frequent dips to 50%. The oxygenation indices (mean airway pressure × FiO<sub>2</sub>/PaO<sub>2</sub> × 100) were up to 25.

In our setting, iNO was not available, we decided to administer iloprost, having obtained informed parental consent. The baby was changed to SIMV to deliver iloprost. Iloprost was inhaled by connecting a built-in ultrasound nebulization chamber to the inspiratory branch of the respirator circuit. While the drug was administered, the baby was not disconnected from the ventilator. Iloprost, the solution containing 20 µg in 2 mL, was inhaled with an initial dosage of 20 µg/kg/d every 90 minutes, integrating a nebulizer into the ventilatory system. After administration of inhaled iloprost, the oxygen saturation rose to 90–95% in 6–10 hours and no falls to 50%. Subsequently, the ventilation pressure and frequency could be lowered significantly (PIP 11 cmH<sub>2</sub>O, PEEP 4 cmH<sub>2</sub>O, frequency 40/min, FiO<sub>2</sub> 25%). Echocardiography showed a conversion of ductal shunt to left-to-right and concomitant decrease of the pulmonary artery pressure with systolic TR pressure gradient to 39 mmHg (Fig. 3). Over the next 10 days, the infant continued to improve clinically and the oxygen saturation was maintained adequately up to 98% and could be weaned from the ventilator therapy.

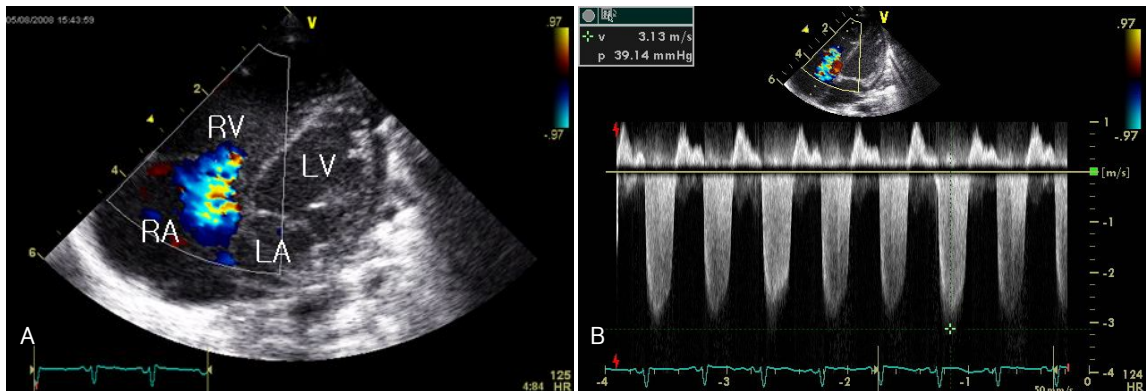
But 3 days after the weaning, the baby developed mild



**Fig. 1.** Marked cardiac enlargement and bilateral diffuse infiltrates and atelectasis of the lung are visible on the chest X-ray.



**Fig. 2.** (A) Two-dimensional echocardiography revealed marked right atrium (RA) and right ventricle (RV) enlargement and (B) the interventricular septum shift toward the LV and appearing flattened. (C) In a doppler image, peak tricuspid regurgitation (TR) velocity is in the region of 3.9 m/sec, yielding a gradient across the tricuspid valve at 63 mmHg. The pulmonary artery pressure was assumed to be 68–73 mmHg.



**Fig. 3.** (A) After the administration of inhaled iloprost, echocardiography revealed a decrease of the tricuspid regurgitation (TR) velocity and (B) the systolic TR pressure gradient decreased to 39 mmHg. The pulmonary artery pressure was assumed to be 44–49 mmHg.

tachypnea and chest retraction and restarted ventilator therapy with CPAP. Ten days after the weaning, the infant had a fever and severe tachypnea and CO<sub>2</sub> retention up to 60–70 mmHg. Echocardiography showed increased left to right shunt flow through the PDA. We decided on surgical operation of PDA, and PDA ligation was done. Because marked increase of the pulmonary artery pressure and the right ventricular failure persisted, we continued inhaled

iloprost treatment after the PDA ligation. The systemic BP was slightly decreased during iloprost treatment but within the normal range, and there were no other serious side effects. The baby was weaned off the iloprost treatment on the postoperative day 4 and extubated on the postoperative day 11. Her neurologic examination was considered normal, and the baby was discharged on the 60 day of life.

## Discussion

We present a case of a neonate with PPHN refractory to the supportive treatment, which in the absence of iNO and extracorporeal membrane oxygenation (ECMO), was successfully treated with inhaled iloprost.

PPHN occurs when pulmonary vascular resistance (PVR) remains elevated after birth. The elevated PVR decreases pulmonary blood flow and results in right-to-left shunt of blood through fetal circulatory pathways. This leads to severe hypoxemia that may not respond to conventional respiratory support. In normal conditions, a decline in the PVR is accompanied by an increase in systemic vascular resistance (SVR) within the first few hours after birth. Conditions that interfere with normal decline in the PVR/SVR ratio cause the persistent transitional circulation and result in PPHN.

The management of PPHN is largely supportive. It is aimed to promote a progressive decline in the PVR/SVR ratio and maintain adequate tissue oxygenation. Before the introduction of iNO therapy, the most commonly used modalities were hyperventilation (66%), continuous alkali infusion (75%), inotropic agents (84%), vasodilators including tolazoline (39%), sedation (94%), paralysis (73%), high frequency ventilation (39%) and ECMO (34%)<sup>11</sup>. But most of these interventions have not been studied in a controlled trial.

Pulmonary vasodilator therapy with iNO has been clearly shown to improve oxygenation and decrease the need for ECMO therapy in term infants with severe PPHN<sup>2-4</sup>. There are several potential toxicities of iNO such as methemoglobinemia secondary to excess iNO concentrations or impaired metabolism, pulmonary injury related to increased NO<sub>2</sub> concentrations during administration. However, iNO appears to be relatively safe when appropriately monitored<sup>5</sup>. The effects of iNO in PPHN have been studied extensively, so iNO is currently regarded as the mainstay of treatment and the recommended pulmonary vasodilating agent for PPHN.

Although iNO has improved outcomes for many infants with PPHN, there still remain those who do not respond. In addition, the iNO treatment is often not available due to lack of required NO delivery systems in many hospitals.

Prostacyclin (prostaglandin I<sub>2</sub>, PGI<sub>2</sub>) is an important mediator of pulmonary vasodilation<sup>6</sup>. A number of studies

have also shown that prostacyclin plays a role in vasodilation during the normal transition to extrauterine life<sup>7</sup>. Prostacyclin is also a potent vasodilator when infused directly into the fetal lung in vivo.<sup>8</sup> These findings suggest that prostacyclin is another potential vasodilatory therapy in patients with PPHN.

Intravenous prostacyclin infusion is effective in reducing pulmonary arterial pressures but tends to cause systemic hypotension<sup>9</sup>. The half-life of prostacyclin is short because it undergoes a spontaneous hydrolysis to its stable metabolite, 6-keto-PGF<sub>1</sub>-α<sup>6</sup>. Thus, aerosolized prostacyclin has been shown to cause a selective decrease in pulmonary artery pressure<sup>10</sup>.

There are a few case reports on the treatment of PPHN with inhaled prostacyclin. Aerosolized prostacyclin has been administered to two neonates and improved oxygenation and reduced pulmonary pressure, without systemic hypotension<sup>11</sup>. And it also has had a beneficial effect on the oxygenation of a preterm neonate (28 weeks gestational age) with respiratory distress syndrome complicated by marked hypoxemia due to PPHN<sup>12</sup>.

Prostacyclin enhances cyclic adenosine monophosphate (cAMP), whereas iNO increases cyclic guanosine monophosphate (cGMP). Increased levels of cAMP and cGMP in vascular smooth muscle are associated with vascular dilatation. The effects of prostacyclin on pulmonary vascular tone are complementary to that of NO<sup>6</sup>. The cAMP and cGMP may compete as substrates for phosphodiesterase, enhancing the effects of NO and prostacyclin when they are used together<sup>13</sup>. Therefore, there is a potential synergistic effect on the pulmonary vascular tone with the combined use of these two drugs<sup>6</sup>. It has been shown in studies performed in experimental pulmonary hypertension in rats<sup>14</sup>. There are two case reports that show the beneficial effects of inhaled prostacyclin in non-responders of iNO, as well as an additive effect combining both agents<sup>15, 16</sup>.

Iloprost is a chemically stable prostacyclin analogue that can be delivered by nebulizers. It is stable at room temperature and has a half-life of 20–30 minutes<sup>17</sup>. Although the pediatric experience is limited, a study in children with pulmonary hypertension associated with congenital heart disease suggests that efficacy of inhaled iloprost is equivalent to iNO in lowering pulmonary vascular resistance<sup>18</sup>.

Few data are available about its use in patients with PPHN. To our knowledge, there is only one case of PPHN that has been treated with iloprost because iNO was

unavailable<sup>19)</sup>. The baby showed an improvement in oxygenation and pulmonary pressure decreased. No side effects were observed, but the baby died after 3 weeks because of other neurological problems.

This report is the first case of PPHN treated with iloprost in Korea. In our case mentioned, we used iloprost as a substitute for iNO. We believe our case is novel due to the fact that iloprost was used primarily and not in combination with iNO or other vasodilators. We chose the dosage based on literature data available<sup>16, 19)</sup>. There are many hospitals where iNO is not readily available and severe cases who failed iNO therapy. Although we do not advocate it as a standard therapy, iloprost may be used for rescue therapy in babies with PPHN that failed to respond adequately to iNO or in centers where iNO is not available. Further research is needed to determine optimum dose, safety, and method of administration. If found effective in randomized controlled trials, iloprost could contribute greatly to the treatment of PPHN in hospitals with limited resources.

## 한 글 요약

### Iloprost 흡입 투여로 치료한 신생아 폐고혈압 지속증 1예

대구가톨릭대학교 의과대학 소아과학교실

장윤영 · 박혜진

신생아 폐고혈압 지속증은 치료가 힘들고 사망률이 높은 질환이나, 산화질소 흡입 치료가 시행된 이후 사망률이 많은 감소를 가져왔다. 그러나, 신생아 집중 치료실이 있는 병원이라도 이러한 산화질소 흡입 치료가 가능하지 않는 곳이 많고, 산화질소 투여에도 호전되지 않는 경우도 있다. 흡입 iloprost는 최근 원발성 혹은 이차성 폐고혈압 환자에서 사용이 늘고있는 폐동맥 확장제로, 신생아 폐고혈압 지속증에 사용한 증례가 외국에 보고된 바 있다. 환아는 출생시 심한 태변 착색과 출산 질식, 진행되는 저산소증을 보였으며, 신생아 폐고혈압 지속증으로 진단되었다. 환아는 지속적인 저산소증을 보였으며, 통상적인 지지 치료에도 호전되지 않았다. 당시 저자들의 병원에는 산화질소 흡입 치료가 가능하지 않아, iloprost 흡입 치료를 시도하였다. Iloprost 흡입 치료 이후 수시간 내에 산소 포화도가 증가하였으며, 심초음파상에는 동맥관을 통한 우좌 단락이 좌우로 바뀌었고, 우심실 압력이 감소하였다. Iloprost 흡입 치료를 하는 동안 특별한 부작용은 관찰되지 않았다. 저자들은 산화질소 흡입치료가 가능하지 않은 상황에서 신생아 폐고혈압 지속증 신생아의 치료로 iloprost 흡입

치료를 시도한 경험을 보고하는 바이다.

## References

- Walsh-Sukys MC, Tyson JE, Wright LL, Bauer CR, Korones SB, Stevenson DK et al. Persistent pulmonary hypertension of the newborn in the era before nitric oxide: practice variation and outcomes. *Pediatrics* 2000;105:14-20.
- Kinsella JP, Truog WE, Walsh WF, Goldberg RN, Bancalari E, Mayock DE et al. Randomized, multicenter trial of inhaled nitric oxide and high-frequency oscillatory ventilation in severe, persistent pulmonary hypertension of the newborn. *J Pediatr* 1997;131:55-62.
- Roberts JD Jr, Fineman JR, Morin FC 3rd, Shaul PW, Rimar S, Schreiber MD et al. Inhaled nitric oxide and persistent pulmonary hypertension of the newborn. The Inhaled Nitric Oxide Study Group. *N Engl J Med* 1997;336:605-10.
- Davidson D, Barefield ES, Kattwinkel J, Dudell G, Damask M, Straube R et al. Inhaled nitric oxide for the early treatment of persistent pulmonary hypertension of the term newborn: a randomized, double-masked, placebo-controlled, dose-response, multicenter study. The I-NO/PPHN Study Group. *Pediatrics* 1998;101:325-34.
- Finer NN, Barrington KJ. Nitric oxide for respiratory failure in infants born at or near term. *Cochrane Database Syst Rev* 2006;18:CD000399.
- Konduri GG. New approaches for persistent pulmonary hypertension of newborn. *Clin Perinatol* 2004;31:591-611.
- Weinberger B, Weiss K, Heck DE, Laskin DL, Laskin JD. Pharmacologic therapy of persistent pulmonary hypertension of the newborn. *Pharmacol Ther* 2001;89:67-79.
- Cassin S, Winikor I, Tod M, Philips J, Frisinger J, Jordan J et al. Effects of prostacyclin on the fetal pulmonary circulation. *Pediatr Pharmacol (New York)* 1981;1:197-207.
- Eronen M, Pohjavuori M, Andersson S, Pesonen E, Raivio KO. Prostacyclin treatment for persistent pulmonary hypertension of the newborn. *Pediatr Cardiol* 1997;18:3-7.
- Santak B, Schreiber M, Kuen P, Lang D, Radermacher P. Prostacyclin aerosol in an infant with pulmonary hypertension. *Eur J Pediatr* 1995;154:233-5.
- Bindl L, Fahnenstich H, Peukert U. Aerosolized prostacyclin for pulmonary hypertension in neonates. *Arch Dis Child Fetal Neonatal Ed* 1994;71:F214-6.
- Soditt V, Aring C, Groneck P. Improvement of oxygenation induced by aerosolized prostacyclin in a preterm infant with persistent pulmonary hypertension. *Intensive Care Med* 1997;23:1275-8
- de Wit C, von Bismarck P, Pohl U. Synergistic action of vasodilators that increase cGMP and cAMP in the hamster cremaster microcirculation. *Cardiovasc Res* 1994;28:1513-8.
- Hill LL, Pearl RG. Combined inhaled nitric oxide and inhaled prostacyclin during experimental chronic pulmonary hypertension. *J Appl Physiol* 1999;86:1160-4.
- Kelly LK, Porta NF, Goodman DM, Carroll CL, Steinhorn RH. Inhaled prostacyclin for term infants with persistent pulmonary hypertension refractory to inhaled nitric oxide. *J Pediatr* 2002;141:830-2.

- 16) Ehlen M, Wiebe B. Iloprost in persistent pulmonary hypertension of the newborn. *Cardiol Young* 2003;13:361-3.
- 17) Aschner JL. New therapies for pulmonary hypertension in neonates and children. *Pediatr Pulmonol Suppl* 2004;26:132-5.
- 18) Rimensberger PC, Spahr-Schopfer I, Berner M, Jaeggi E, Kalangos A, Friedli B et al. Inhaled nitric oxide versus aerosolized iloprost in secondary pulmonary hypertension in children with congenital heart disease: vasodilator capacity and cellular mechanisms. *Circulation* 2001;103:544-8.
- 19) De Luca D, Zecca E, Piastra M, Romagnoli C. Iloprost as 'rescue' therapy for pulmonary hypertension of the neonate. *Paediatr Anaesth* 2007;17:394-5.